plexus. The median nerve may be compressed within the carpal tunnel. **tunnel syndrome**. Similarly the ulnar nerve may be compressed as it lies behind epicondyle of the humerus. Damage to the median nerve produces a condition known as the **simian hand** while damage to the ulnar nerve produces a **claw hand**. The radial and ulnar arteries are the principal vessels of the forearm. In their course, they lie between the radial and ulnar nerves. The ulnar artery continues as the superficial palmar arch while the radial artery continues into the more proximally situated deep palmar arch.

EXERCISE 5:

1. Draw and show the arrangement of any group of muscles of this region

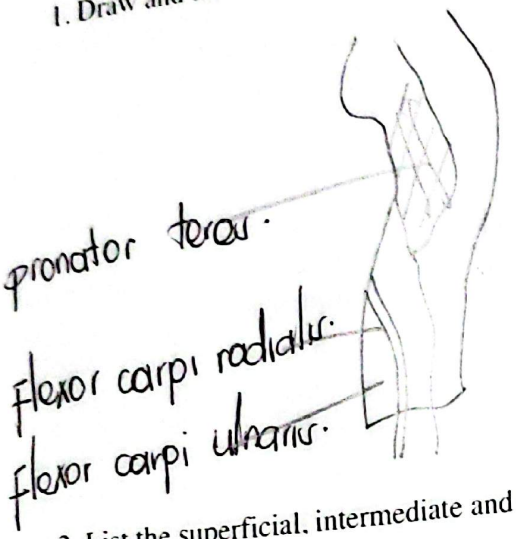

2. List the superficial, intermediate and deep flexors of the forearm.

Superficial group
Pronator teres.
flexor carpi radialis
Palmaris longus.
flexor carpi ulnaris.

Intermediate
flexor digitorum superficialis.

Deep.
Flexor digitorum profundus
Flexor pollicis longus.
Pronator quadratus.

3. What is the attachment of the superficial group of flexors?

	origin.	insertion.
Pronator teres.	medial epicondyle.	Lateral surface of radius.
flexor carpi radialis	medial epicondyle	2nd and 3rd metacarpals
Palmaris longus	medial epicondyle	palmar aponeurosis.
flexor carpi ulnaris	olecranon.	pisiform.

4. Define the attachment and surface mark the flexor retinaculum.

It is a strong fibrous band extending across the anterior aspect of wrist

Attachment; Radially - Tubercle of scaphoid. Ulnarly - pisiform
- Trapezium. - Hamate.

5. Name the order of structures superficial and deep to the retinaculum.

Superficial; - palmaris longus tendon.
- ulnar nerve
- ulnar artery.
- median nerve.
- Radial artery.

Deep - 4 tendons of flexor digitorum superficialis.
- 4 tendons of flexor digitorum profundus.
- median nerve.

6. Describe the formation of the thenar and hypothenar compartments and their contained muscles.

Thenar compartment.
- Abductor pollicis brevis.
- flexor pollicis brevis.
- Opponens pollicis.

hypothenar.
- Abductor digiti minimi.
- flexor digiti minimi brevis.
- opponens digiti minimi.

7. State the actions of the thenar and hypothenar muscles.

APB - Abducts thumb.
FPB - flexes thumb.
OP - opposes thumb.

ADM - abducts little finger.
FDMB - flexes little finger.
ODM -

8. Define the fibrous sheaths, synovial sheaths and termination of long flexor tendons.

Fibrous sheaths; - strong fibrous tunnels attached to the phalanges.

Synovial tendon sheaths; fluid filled coverings surrounding the long flexor tendons.

Termination of long flexor tendons;

9. Describe the origins and insertions of the lumbricals and interossei.

	origin	insertion
lumbricals	muscles from tendons of FDP	Along lateral side of 2 finger.

10. Outine the actions of the flexor, lumbrical and interossei muscles.

long flexors; flex the interphalangial and MCP joint of the finger.

lumbricals; flex the MCP joints while simultaneously extending the interphalangel joints.

Interossei; palmar - Adduct the fingers.
Dorsal - Abduct fingers.

11. Describe the neurovascular plane of the foream.

Plane btn FDS and FDP containing median nerve, ulnar artery and ulnar nerve.

~~Radial artery; from cubital bifurcation, lateral course.~~

12. Describe the course and distribution of the radial and ulnar arteries.

Ulnar artery; Medial course deep to FCU, forms superficial palmar arch.

Radial artery; from cubital bifurcation, lateral course.

13. Demonstrate the formation of the superficial and deep palmar arches and surface-mark them.

Superficial arch; Direct continuation of ulnar artery; surface mark at proximal transverse crease.

Deep arch; Direct continuation of radial artery; surface mark at proximal wrist crease.

14. Describe the nerve supply to the flexor compartment of the foream.

Median nerve supplies all muscles of the anterior forearm compartment except for 1½ muscles which are Flexor carpi Ulnaris and medial half of flexor Digitorum Profundus which are supplied by ulnar nerve.

15. Deduce the effects of lesion of the ulnar and median nerves at the elbow and wrist.

Ulnar nerve; paralysis of FCU and medial half of FDP, sensation loss over medial part.

Median nerve; Hand of Benediction.
Ape hand deformity.

16. Discuss the importance of the arrangement of the digital vessels and nerves in local anesthesia.

Proper digital nerves and vessels run in the dorsomedial and dorsolateral aspects of each digit, Arterial &

CamScanner

17. Describe the clinical importance of the palmar spaces.
Potential paths for the spread of deep hand infections and abscess formation.

JOINTS OF FREE UPPER LIMB

1. Elbow Joint

Relevant skeletal features:
Humerus - trochlea; capitulum; radial, coronoid and olecranon fossae;
Ulna - trochlear notch; coronoid and olecranon processes;
Radius - head; neck; tuberosity.
Muscles in relation to capsule of joint: brachialis; biceps; triceps; anconeus.
Capsule: attachments.
Ligaments: ulnar collateral; radial collateral.
Synovial membrane: reflection.
Articular surfaces: shape; carrying angle.
Movements: flexion; extension.
Nerve supply: musculocutaneous; radial.
Blood supply: anastomosis around elbow.
Clinical anatomy: dislocations; fractures.

2. Proximal, Middle and Distal Radioulnar Joints

Relevant skeletal features:
Radius - head: ulnar notch; interosseous border;
Ulna - radial notch: head; interosseous border.
Capsule: attachments.
Ligaments: anular (proximal joint); interosseous membrane.
Intraarticular structures: articular disc (distal joint).
Synovial membrane: reflection.
Movements: Pronation; supination; axis of movement.

3. Wrist Joint

Relevant skeletal features: distal end of radius; articular disc; scaphoid; lunate; triquetrum Capsule: attachments.
Ligaments: palmar radiocarpal and palmar ulnocarpal; dorsal radiocarpal and dorsal Ulnocarpal; radial and ulnar collateral.
Synovial membrane: reflection.
Articular surfaces: shape.
Movements: flexion; extension; adduction; abduction; circumduction.

4. Intercarpal, Midcarpal, Carpometacarpal, Metacarpophalangeal and Interphalangeal joints

CamScanner

Is a hinge type of synovial joint comprising of articulations; joint cavity.
humeroulnar, humeroradial proximal radial ulnar joint

ligament:

Joint capsule.
ulnar collateral lig.
Annular lig.
Radial collateral lig.

ii. Describe the articulation of the radius and ulna with the humerus.

Humeroulnar (trochlea + trochlear notch) and humeroradial (capitulum + radial head) at the ~~wrist~~ elbow joint.

iii. Describe the attachments of the capsular ligament and the radial and ulnar collateral ligaments.

capsule attaches to humerus proximal to fossae to ulna and anular ligament.
UCL has anterior, posterior, transverse bands.
RCL blends with anular ligament.

iv. Discuss the muscles involved in flexion and extension.

flexion; Brachialis, Biceps brachii, Brachioradialis.
Extension Triceps brachii, Anconeus.

v. Discuss the clinical importance of segmental innervation of the joint.

Innervated by musculocutaneous, radial, median, and ulnar nerves (C5-C8) According to Hilton's law.

vi. Indicate the types of dislocation and sites of common fractures around the joint.

Posterior elbow dislocation - the most common type of ellocration of lhow dislocation from a fall on a street, a fall on an outstreched hand. Occuring in movement of ulna displaces the ulna posteriorly, the posteriorly relative to the humerus.

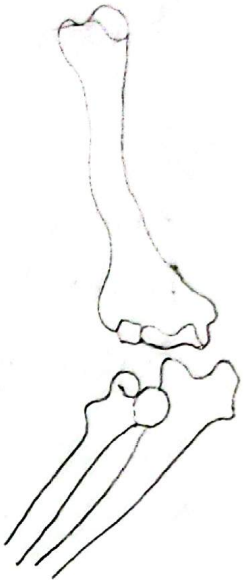

Common fractures; ~~suprotco~~

- supracondylar humerus fracture are risking brachial artery and the brachial artery injury in the median nerve ~~the~~
- Olecranon fractures - radial neck ricks /head/ n
- Radial head /neck fractures -

2. RADIOULNAR JOINTS

i. Describe how the movements of pronation and supination of the forearm are afforded.

Pronation ; performed by pronator teres, when in quadratus Axis through center ~~to~~ of radial head on the radius.

Supination ; supinator and biceps brachii, solvers in ulnar fixed Axis through ulnar head.

ii. Define the articulating surfaces of the proximal and distal radioulnar joints.

Proximal - circumference of head of radius with radial notch of ulnar.

Distal - head of ulna with ulnar notch of radius.

4. What are the functional roles of the anconeus muscle; anular ligament; articular disc?

Anconeus; weak elbow extensor, abducts ulna during pronation
Anular lig.; forms collar around radial head, allows spin.
Articular disc; separates ulna from carpus.

5. Discuss the segmental innervation of the joints.

mainly C5 - C6 for proximal radial and median nerve
C7 - C8 for distal (posterior interosseous nerve.

3. WRIST AND MIDCARPAL JOINTS

i. Describe the structural and functional aspects of these joints.

structural - wrist is synovial ellipsoid, midcarpal is synovial plane.
functional - together they permit flexion, extension, abduction adduction and circumduction.

ii. Define the articulating surfaces, capsules and synovial reflections of the joints.

Proximal is the distal radius and articular disc, Distal are scaphoid, lunate and triquetrum.
separate synovial cavities exist for wrist and midcarpal rows with capsule continuous.

iii. Enumerate the primary flexors and extensors of the wrist.

flexors; Flexor carpi Radialis, Flexor carpi Ulnaris.
Extensors; Extensor carpi Radialis longus -
Extensor carpi Radialis Brevis.
Extensor Carpi Ulnaris.

iii. Identify the tendons around the wrist in the living.

Palmar ; Palmaris longus, Flexor Digitorum Superficialis
Flexor carpi Ulnaris.

Dorsal - Abductor Pollicis longus, Extensor Pollicis Brevis.
Extensor Pollicis longus, Extensor Digitorum.

iv. Define the movements at the wrist in terms of its ellipsoid articular surfaces.

Biaxial ellipsoid joint allowing movement around two axes,
Flexion and Extension and Abduction/radial deviation and
Adduction/ulnar deviation, plus circumduction.
Rotation is prevented by the oval articular shape.

v. Discus the range of movements at the wrist and associated movements occurring at the midcarpal joint.

Flexion (~80°) Extension (~70°), Adduction (~35°), Abduction (~15°)
Radiocarpal and midcarpal joints work together.
flexion occurs mainly at the midcarpal joint while extension
and adduction occur mainly at the radiocarpal joint.

vi. Assign functional roles to the muscles acting on the joints in terms of prime movers antagonists, synergists and fixation muscles.

Prime mover ; FDS and FP.
Antagonists ; Extensor digitorum.
Synergists ; wrist extensors (ECRL, ECRB, ECU).
Fixators ; Biceps, triceps and shoulder muscles steady the limb.

vii. Discuss the segmental innervation of the joints.

Innervated by articular branches of Anterior Interosseous (median) Posterior Interosseous (radial) and ulnar nerves.

Small joints of the hand

1. Classify the carpometacarpal joint of the thumb, the metacarpophalangeal and interphalangeal joints according to the shape of the articulating surfaces.

1st CMC - saddle joint.
MCP : condyloid joint.
IP : Hinge joint.

CamScanner

2. Review the modes of insertion of the long flexors and extensors of the forearm: the lumbricals and interossei.

FDS splits around FDP to insert on middle phalanx side,
FDP inserts onto distal phalanx base. Lumbricals and
Interossei inserts into extensor expansion lateral bands to
flex MCP and extend IP joints.

3. Explain the increased freedom of movement of the index and little fingers, and the specialised movements peculiar to the thumb.

They possess extra extensor muscle allowing independent
extension over the middle and ring fingers are
flexed thumb. combination of adduction flexion and medial

4. Comprehend the anatomical basis of power, precision, hook and pinch grips.

Power grip - intrinsic muscles.
Precision grip - lumbricals and interosseus.
Hook grip - hook shape.

5. Demonstrate the position of rest and the working position of the hand.

Rest.
The wrist is extended slightly.
Fingers partially relaxed
Thumb slightly abducted.

work.
- wrist extend for the
CMC joint of the thumb
abduction.
- Joint flexed.

6. Analyse the contributions of the skin and subcutaneous structures in the performances of manual skills. Palmar skin- thick, rich in sweat glands.

Dorsal skin - thin elastic.
Subcutaneous fat - has small lobules for shock
absorption.

7. Outline the segmental innervation of the smaller joints of the hand.

Spinal cord segments.

NERVES OF THE UPPER LIMB

i. Describe the disposition of the nerves of the upper limb and their clinical importance

major nerves arise from brachial plexus, descending the limb within specific compartments.
Axillary - around surgical neck; Radial - through radial groove, median - via carpal tunnel, Ulnar; behind medial epicondyle.
Disposition dictates vulnerabilities and risk of injury from trauma.

ii. Illustrate the formation of the brachial plexus and its distribution

Roots (C_5-T_1) form trunks (upper, middle, lower,)
Each splits into anterior and posterior divisions.
Cords (lateral, medial, Posterior) & distribute to peripheral branches.

iii. Demonstrate the ulnar, median, musculocutaneous, radial and axillary nerves, mentioning their root values.

(C_8, T_1): flexors of hand, medial FDP.
median (C_5-T_1): thenar, lateral FDP.
musculocutaneous (C_5-C_7): flexors of arm
Radial (C_5-T_1): extensors of arm.
Axillary (C_5-C_6): deltoid, teres minor.

iv. Surface mark the above nerves and place them in relation to the relevant bones.

median - medial to biceps brachii - through carpal tunnel.
Ulnar - Behind medial epicondyle.

v. Demonstrate tendon jerks and discuss their anatomical basis

Biceps jerks -
Brachial radialis jerk.
Triceps Jerk.

vi. Demonstrate the anatomical principles in the testing of sensory loss.

Areas of skin supplied by the spinal nerve
C_6 for thumb.

vii. Explain the anatomical basis for the causation and manifestation of: Erb's and Klumpke's paralyses; crutch palsy and wrist drop; claw hand; cervical rib and carpal tunnel syndromes.

Erbs palsy - injury to upper trunk of brachial plexus.
Klumple's palsy - injury to lower trunk.
wrist drop = compression of radial nerve in the axilla.

CamScanner

BLOOD VESSELS AND LYMPHATICS OF THE UPPER LIMB

1. Draw a diagram to show the subclavian, axillary, brachial, radial and ulnar arteries.

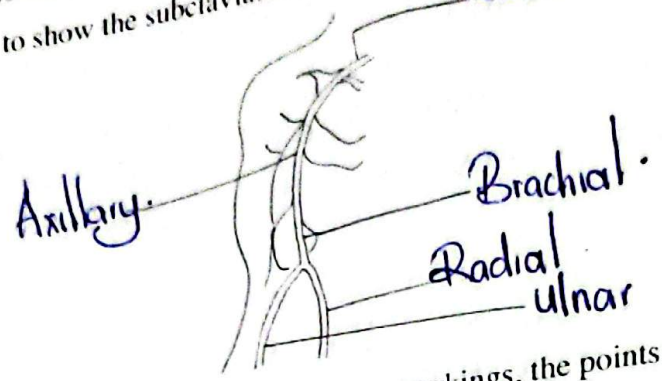

2. Describe the extent of these arteries, their surface markings, the points for feeling the pulse and the site for recording blood pressure in the upper limb.

Subclavian - 1st rib border.
Axillary; teres major, pulse felt in axilla.
Brachial; medial bicipital groove, pulse palpable in cubital fossa
Radial; distal radius lateral to FCR tendon.
Ulnar; lateral to FCU tendon.

3. Illustrate the principles of collateral circulation and periarticular anastomoses.

Periarticular anastomoses provide collateral channels, recuring distal flow if a main artery is occluded and Elbow.

4. Explain the arrangement of superficial and deep veins.

Superficial veins - are subcutaneous and independent -
Deep veins run with companion arteries beneath deep fascia, utilizing arterial pulses to aid return.

5. Define the routes of venous drainage and the extent of the cephalic, basilic, median cubital and axillary veins.

cephalic - lateral forearm/arm - axillary vein.
Basilic - medial forearm - axillary vein
median cubital; in cubital fossa, shunts blood cephalic → basilic.
Axillary veins - Teres major to first rib.

6. Explain the selection of the cubital fossa as the site for intravenous infusions.

Median cubital vein is chosen for its large size, accessibility and stability; also safety from underlying deep structures

7. Indicate the routes of drainage of superficial and deep lymphatics.
Superficial lymphatics:- from skin, median, radial, ulnar groups accompany veins cephalic vein route; lymph from lateral side along vein to deltopectoral group. basilic vein
Deep lymphatics.

10. Describe the regional lymph nodes and attempt to palpate them in the living.
- Supratrochlear (cubital) Nodes.
- Deltopectoral Nodes
- Axillary Nodes. - Apical - central
- Pectoral - to lateral.

11. Discuss the anatomical basis of Volkmann's ischaemic contracture and Dupuytren's contracture.
Dupuytren's contracture: gradual progressive hypertrophy and shortening of the palmar Aponeurosis.

Section 2

THE DISSECTION OF LOWER LIMB

Lower Limb

INTRODUCTION

Human beings are unique among the primates in that they have adopted a bipedal mode of locomotion which has produced a substantial advantage over the older, more stable, quadrapedal gait. Bipedalism brings the advantage of a greater range of vision and frees the hands for the use of and for making tools and carrying food. As a result of bipedal locomotion, the weight of the body is transmitted to the lower limb via the pelvis. This has brought about several specialisations in the architecture of the skeleton, joints and muscles of the lower limb. These specialisations will have to be examined as the student proceeds with the dissection of the lower limb.

Since the lower limb is an outgrowth from the lateral aspect of the lower part of the trunk, its nerves and blood vessels are drawn out from within the abdomen and pelvis. Consequently, the nerves and vessels entering the front of the thigh pass beneath the **inguinal ligament**; those to the medial side of the thigh issue through the **obturator canal**; and those entering the gluteal region traverse the **greater sciatic foramen**.

It must also be borne in mind that the lower limb has undergone rotation during development. Thus, the original (embryonic) extensor or dorsal surface has shifted to the anterior or ventral aspect in the adult. Therefore, the extensor muscles which are now in the anterior compartment of the thigh are supplied by **dorsal divisions of the lumbar plexus** (femoral nerve L2, 3, 4). Similarly, the adductor muscles which lie on the medial side of the thigh developmentally belong to the flexor compartment and are hence 82 A Guide to Dissection of the Human Body supplied by **ventral divisions of the lumbar plexus** (obturator nerve L2, 3, 4). The pure flexor muscles, which are now at the back of the thigh, are called the **hamstring muscles**. These are supplied by **ventral divisions of the sacral plexus** via branches from the tibial component of the sciatic nerve. In the thigh, the anterior (extensor), medial (adductor) and posterior (flexor) compartments are separated by the medial, posterior and lateral intermuscular septa. Of these, the lateral

CamScanner

A: Draw and show a pictorial arrangement of the blood ves

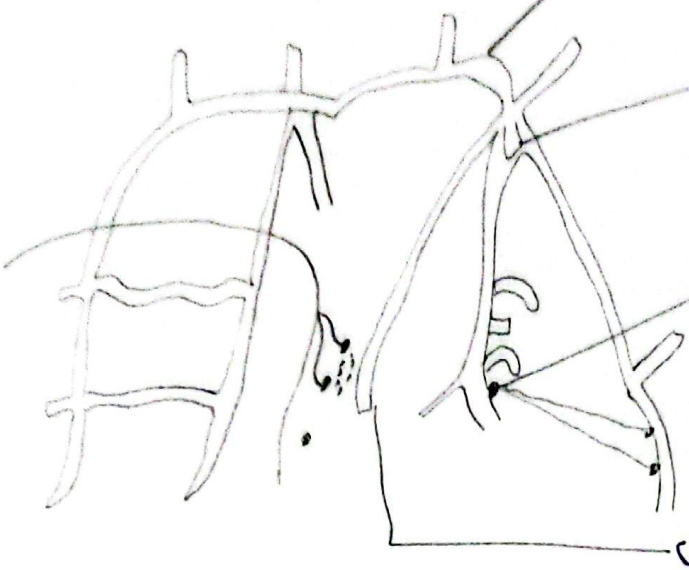

B: Outline the principles of the venous drainage by classifying veins into superficial and deep.

Superficial; located in subcutaneous tissue, independent of arteries & drain cutaneous
Deep; located deep to deep fascia, run with arteries like femoral vein.

C: Identify the great saphenous vein, its tributaries and its termination into the femoral vein.

Course; starts at medial foot dorsal venous arch → runs anterior to medial malleolus
ascends medial leg/thigh.
Tributaries; superficial epigastric, superficial circumflex iliac, superficial external pudendal veins.
Terminations; Pierces saphenous opening to empty into femoral vein.

D: Identify the superficial and deep inguinal lymph nodes and outline the principles of the lymph drainage.

Superficial Inguinal Node; Drain below umbilicus abdominal wall, gluteal region, perineum, superficial lower limb.

Deep Inguinal nodes; medial to femoral vein, drain deep structures and superficial node efferents Empty into External Iliac nodes

E: Define the boundaries of the femoral triangle and adductor canal.

femoral triangle; Superior - Inguinal lig. medial - Adductor longus.
lateral - sartorius. floor - Iliopsoas, Pectineus.

Adductor canal; Antelateral - vastus medialis.
Posterior - Adductor longus.
medial - Sartorius.

F: Demonstrate the femoral sheath, femoral artery, femoral vein, femoral canal and femoral ring.
sheath → contains femoral artery-vein, femoral canal
femoral sheath contains femoral artery.
position of sheath - artery, femoral canal → canal and femoral ring

G: Analyse the boundaries of the femoral canal and its relation to femoral hernia; distinguish femoral from inguinal hernia.
posterior - r
femoral from inguinal hernia ~~eg re~~ to pubic tubercle, aype pubic tubercle

H: Identify the course and extent of the femoral artery and indicate the common sites of injury.
common sites - mid-thigh from penetrating trauma, monitoring trauma
femoral artery above the proximal thigh.

I: Outline the territory of supply of the profanda femoris artery.
- medial and lateral circumflex arteries
- Lateral circumflex arteries:-
- Perforating arteries - anterior compartment.

Exercise 2

Objective Led Questions about the Anterior and Medial Aspects of the Thigh 2

A: Draw and show a pictorial arrangement of the muscular compartments; also show the distribution of related nerves.



B: Explain the concept and significance of muscular compartments and the distribution of related nerves. muscular compartment is bounded by fascia, holds vastus muscle groups, muscles, arteries and nerves.
Nerve distribution:- femoral Nerve - obturator nerve - perforating arteries.

C: Describe the fascia lata and the intermuscular septa passing from it to the femur.
fascia lata is attachement by deep fascia, attached by faroria lata grand to femur then to meclus femoris and rectus muscles

D: Evaluate the actions of the muscles of this region in the living subject.

Flexors -
Iliopsoas
Rectus femoris.

Adductors -
Adductor longus
Adductor Brevis

Quadriceps Extensors
- Vastus muscles
- Rectus femoris.

E: Describe the principles of formation of the lumbar plexus with special reference to the femoral and obturator nerves.
- formed within the Psoas major by ventral rami of L1-L4 spinal nerves.
- Femoral Nerve
- Obturator nerve



F: Evaluate the cutaneous innervation and dermatomic pattern of the region.
Cutaneous Nerves:
- lateral femoral cutaneous Nerve (L2-L3)
- Anterior femoral cutaneous branches (L2-L4)
- saphenous N (obturator N L2-L4)

G: Discuss the effects of lesions of the femoral and obturator nerves and outline clinical tests for these.
For femoral Nerve - motor - weak hip flexion
sensory - loss over
Test - knee extension against resistance.

obturator Nerve. motor - weak thigh adduction.
sensory - loss over middle medial thigh.

Overview of Schedule 8

Before you begin dissection note:

GLUTEAL REGION AND POSTERIOR ASPECT OF THE THIGH

Relevant skeletal features:

Hip bone - gluteal surface; greater and lesser sciatic notches and foramina; iliac crest, tubercle and spines; ischial spine and tuberosity, sacrum coccyx

Femur - greater trochanter; trochanteric fossa; trochanteric crest; quadrate tubercle; gluteal tuberosity; linea aspera;

tibia - condyles and shaft:

Fibula - head.

Subcutaneous structures:

Cutaneous nerves eg. posterior cutaneous nerve of the thigh.

Muscles: Gluteus maximus, medius and minimus; tensor fasciae latae; piriformis; obturator internus and gemelli; quadratus femoris; hamstring muscles including the ischial part of adductor magnus.

Nerves: Sciatic nerve and its divisions; superior and inferior gluteal nerve; nerve to quadrates femoris: nerve to obturator internus; pudendal nerve.

Arteries: superior and inferior gluteal arteries; arterial anastomoses.

Surface anatomy: posterior superior iliac spine; greater trochanter; gluteal fold; sciatic nerve.

Clinical anatomy: Its surface markings/location provides a site for intramuscular injection.

Dissection Schedule 8

GLUTEAL REGION AND POSTERIOR ASPECT OF THE THIGH

1. With the body in the prone position make the following incisions:

hip provide some support for the joint. These muscles form a rotator cuff similar to that around the shoulder joint. Note that they are all lateral rotators of the thigh. The hamstring muscles arising from the ischial tuberosity receive their innervation from the tibial portion of the sciatic nerve. The short head of biceps femoris that arises from the linea aspera is supplied by the common fibular peroneal component of the sciatic nerve.

The semitendinosus is inserted into the medial surface of the upper part of the shaft of the tibia while the semimembranosus gains insertion into the **medial condyle of the tibia**. The ischial part of the adductor magnus is attached to the **adductor tubercle** of the femur, while the biceps femoris has its insertion onto the **head of the fibula**. These insertions will be seen later. The sciatic nerve innervates not only the hamstring muscles of the thigh, but also the entire leg and foot musculature. It is covered only by the gluteus maximus in the gluteal region and by the long head of biceps femoris in the thigh.

The superior and inferior gluteal arteries are distributed chiefly to the gluteal region. The gluteal arteries take part in various anastomoses, which can provide a collateral circulation when the femoral artery is obstructed.

Questions for Dissection Schedule 8

MUSCLES, NERVES AND BLOOD VESSELS OF THE GLUTEAL REGION

Exercise 3

Objective Led Questions about the Gluteal Region 1

A: Draw and show a pictorial arrangement of the Muscles of Gluteal region and list their functions.

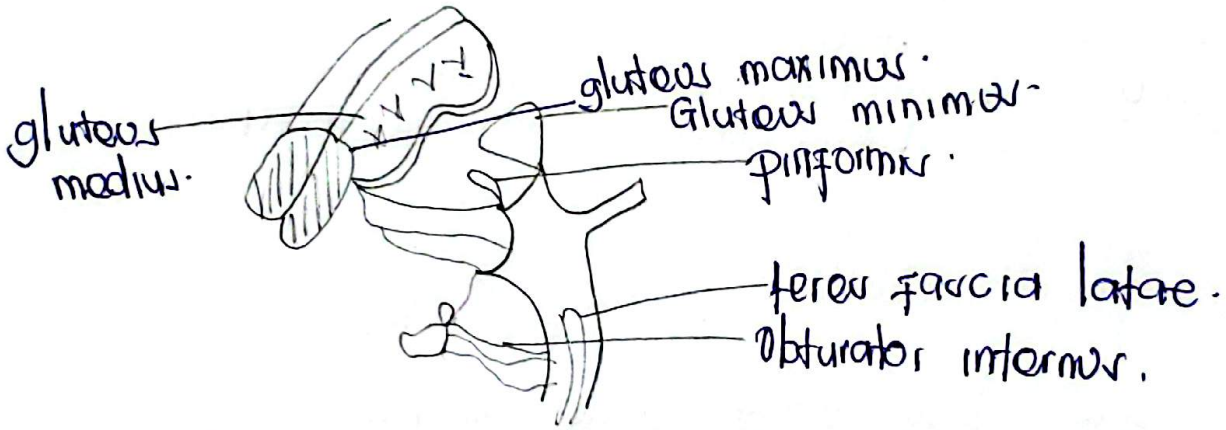

B: Draw the pelvic bones and identify: the crest, tubercle, spines and gluteal lines of ilium; tuberosity, spine and ramus of ischium; crest, tubercle, body and superior and inferior cami of the pubis..

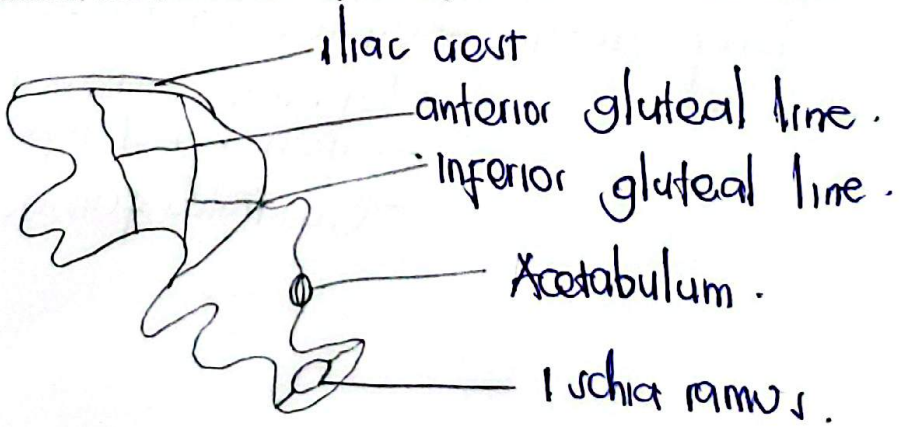

CamScanner

C: Draw the femur and show the head, neck, greater and lesser trochanters, trochanteric line and crest, trochanteric fossa and the linea aspera of the femur

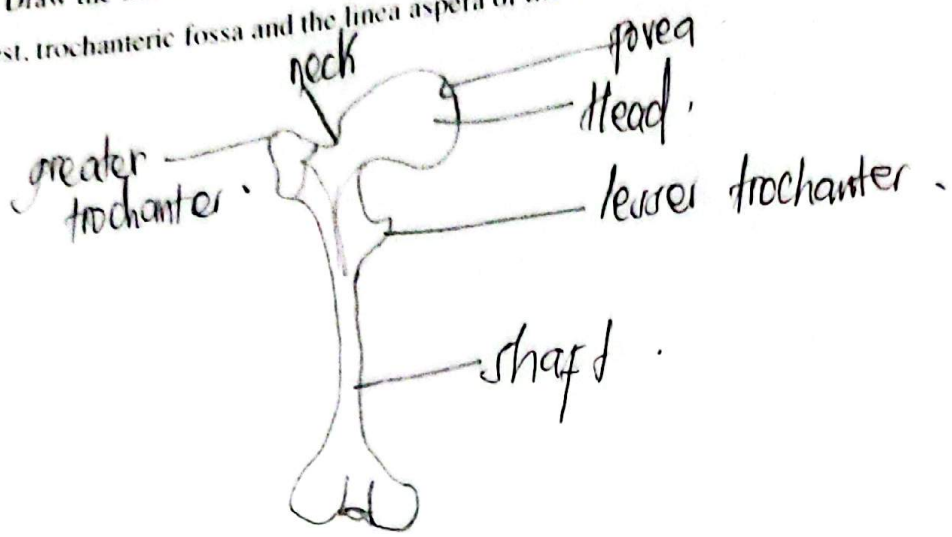

D: Explain how the pelvic girdle, hip bone and femur are Anatomically Orienteted in life.

Pelvic girdle & hip bone; the anterior superior iliac spine and the upper border of the pubic symphisis lie in the same vertical coronal plane. The pelvic inlet faces anteriorly and superiorly and acetabulum faces laterally, inferiorly.

femur - the rounded head is directed medially, superiorly and slightly anteriorly into acetabulum

E: Discuss the arrangement of the muscles of the region in three strata.

Superficial stratum ;- Gluteus maximus.
- Tensor fascae latae.

Intermediate stratum - Gluteus medius.
- Piriformis.

Deep stratum - Gluteus minimus.
- Obturator internus.
- Superior and inferior gemelli.
- Quadratus femoris.

F: Evaluate the actions of the gluteal muscles.

Gluteus maximus: chief extensor of flexed thigh.
lateral rotator of thigh.

Gluteus medius & minimus; Abduct & medially rotates the thigh.
Prevents pelvic drop.

Tensor fasciae latae; flexes, abducts and medially rotates the thigh; tenses the iliotibial tract.

G: Evaluate the actions of the small muscles at the back of the hip.

Piriformis, obturator internus, superior and inferior gemelli and quadratus femoris.; primarily laterally rotates the extended thigh.
-abducts flexed thigh.

stabilising the hip joint by holding the femoral head firmly in the acetabulum

H: Evaluate the actions of the hamstring muscles.

Biceps femoris.
Semitendinosus.
Semimembranosus.
- Extend the thigh at the hip joint and flex the leg at knee joint.
- Biceps femoris laterally rotates the flexed knee.
- semitendinosus and semimembranosus medially rotates the leg.

CamScanner

I: Analyse the double nerve supply of the adductor magnus and biceps femoris muscles.

Adductor magnus:
Innervated by obturator nerve.

Biceps femoris
short head - common fibula nerve.
long head - tibial nerve.

Exercise 4

Objective Led Questions about the Gluteal Region 2

A: Draw and show the arrangement of nerves and blood vessels of the region.

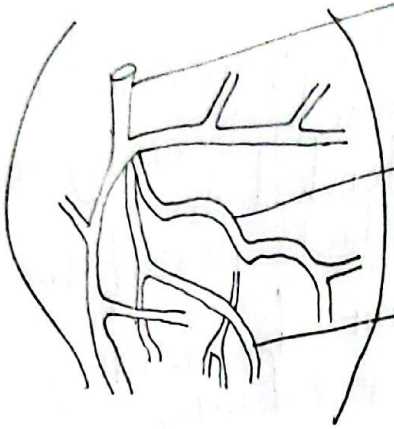

B: Explain the formation of the greater and lesser sciatic foramina.

Greater sciatic foramine formed by greater sciatic notch bounded by sacrotuberous ligament and inferiorly by sacrospinous ligament.
lesser; formed by lesser sciatic notch bounded by sacrospinous lig.

C: Enumerate the structures traversing the sciatic foramina.

Above piriformis
- superiori gluteal nerve
- superior gluteal artery.

Below:
- sciatic nerve.
- Pudendal nerve.

D: Explain why the piriformis is considered the key muscle of the region.

It traverses the greater sciatic foramen, dividing it into suprapiriform and infrapiriform spaces and serves as the landmark for neurovascular structures entering the gluteal region.

- superior gluteal structures emerge above it.
- sciatic, inferior gluteal and pudendal structures emerge below it.

E: Appreciate the functional subdivisions of the sciatic nerve.

It consists of two divisions in a common sheath.

1) Tibial division (L_4-S_3); supplies hamstrings, posterior leg and plantar foot.

2) Common fibular division (L_4-S_2)- supplies the short head of Biceps femoris, anterior and lateral leg and dorsum of foot.

F: Outline the course of the pudendal nerve and vessels.

They exit the pelvis via the greater sciatic foramen inferior to the piriformis, hook around the ischial spine and sacrospinous ligament, and enter the perineum through the lesser sciatic foramen to travel anteriorly within the pudendal canal.

G: Outline the distribution of the superior gluteal nerve.

It exits the pelvis above the piriformis via the greater sciatic foramen and provides motor innervation to the gluteus medius, gluteus minimus and tensor fasciae latae muscles.

H: Surface mark the course of the sciatic nerve.

- located lateral to mid point line connecting the PSIS and ischial tuberosity.
- located mid way between greater trochanter and ischial tuberosity.

I: Explain the site selected for administration of intramuscular injections.

ventro gluteal site because of more and out of critical neuro vascular structures.

Overview of Schedule 9

Before you begin dissection note:

HIP JOINT, POPLITEAL FOSSA AND BACK OF THE LEG HIP JOINT

Relevant skeletal features:

Acetabulum - developmental components; head of femur.

Muscles in immediate relation to capsule of joint:

Iliopsoas; pectineus; obturator externus; short lateral rotators; gluteus minimus; reflected head of rectus femoris.

Capsule:

attachments.

Thickening of capsule:

iliofemoral, pubofemoral, ischiofemoral ligaments.

Intraarticular structures:

ligament of head of femur.

Synovial membrane:

reflection.

Articular surfaces: articular cartilage; acetabular labrum; transverse ligament.

Movements: flexion; extension; abduction; adduction; medial and lateral rotation; circumduction.

Nerve supply:

Application of Hilton's law.

Blood supply: to joint and to head of femur.

Clinical anatomy: dislocation of hip; fractures of femoral neck, positive Trendelenburg's sign

Popliteal Fossa and Back of the Leg

Relevant skeletal features:

Femur - popliteal surface; condyles;

Tibia - condyles; upper end of medial surface: posterior surface; soleal line; medial malleolus;

Fibula - posterior surface; lateral malleolus;

Calcaneus - attachment of flexor retinaculum.

CamScanner

popliteal [illegible]
common fibular nerve supplies [illegible]
as the dorsum of the foot. The tibial nerve supp[illegible]
muscles of the sole of the foot.

The **popliteal artery**, a continuation of the femoral artery at the opening in the adductor magnus, divides into anterior and posterior tibial arteries at the lower border of the popliteus. The anterior tibial artery after passing through the interosseous membrane supplies the anterior compartment of the leg and the dorsum of the foot. The posterior tibial artery supplies the back of the leg and sole of the foot while the fibular artery, a branch of the posterior tibial artery, supplies branches to the fibular compartment.

The muscles of the back of the leg can be divided into a superficial group comprising the gastrocnemius, plantaris and soleus, and a deep group consisting of the flexor digitorum longus, flexor hallucis longus and tibialis posterior. These muscles are plantar flexors, in addition tibialis posterior is also an invertor. The superficial and deep groups are separated by a transverse **intermuscular septum** and the neurovascular plane lies between these two groups of muscles.

Questions for Dissection Schedule 9

HIP JOINT

Objective Led Questions about the Hip Joint I

Exercise 5

A: Draw and show the essential features of the articulating bones and the ligaments around the joint



B: Define the articulating surfaces of the hip joint in the skeleton.
The head of the femur articulates with the acetabulum of the pelvis.

C: Identify the different developmental parts of the hip bone and their contributio acetabulum.
superior - Ilium.
posteroinferior - Ischium.
anteroinferior - pubis.
They fuse at the ~~face~~ triradiate cartilage to form the acetabulum.

D: Describe the attachments of the ligaments of the hip joint and analyse their fundi significance.
iliofemoral, pubofemoral, ischiofemoral ligaments attach to their respective pelvic bones and the femur attach to their respective pelvic bones and the femur stabilizing the joint against hyperextension and rotation.

E: Discuss the different kinds of movement possible at the hip and compare it with the shoulder.
Hip ~~go~~ movements: flexion, extension, abduction, adduction, medial/lateral rotation, circumduction.
Both are ball and socket but hips has a deeper socket and restricted range, primarily ∓ stability and weight bearing compared to shoulder mobility.

F: Discuss the likely sites for dislocation.
Hip dislocation is typically posterior, caused by a force pushing the femur back when the hip and the knee are flexed.

G: Interpret different radiographic views

Exercise 6

Objective Led Questions about the Hip Joint 2

A: Draw and show the arrangement and actions of muscle groups around the hip joint.

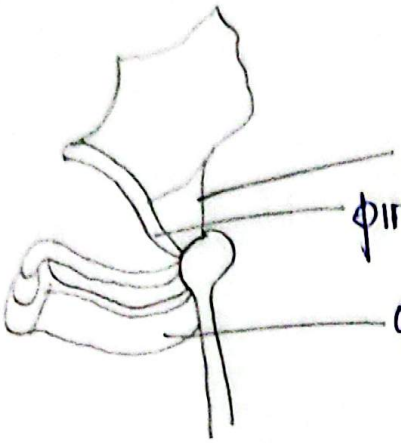

B: Identify the muscles on the anterior, medial and posterior aspects of the thigh and give their attachments and innervation.

Anterior (Femoral Nerve)
- sartorius
- Rectus femoris
- vastus group

Medial (Adductors)
- Adductor magnus, longus, brevis
- Gracilis

Posterior
- Biceps femoris
- Semitendinosus
- Semimembranosus

C: Arrange the muscles into functional groups as flexors, extensors, abductors, adductors, lateral and medial rotators.

Flexors
- Iliopsoas
- Rectus femoris
- Sartorius

Extensors
- Gluteus maximus
- Hamstrings

Abductors
- Gluteus medius
- Gluteus maximus
- tensor fascia latae

Adductors
- magnus
- Longus
- Brevis
- Pectineus

Lateral Rotators
- Gluteus maximus
- Piriformis
- Deep Rotators
- Adductor magnus

Medial Rotators
- Gluteus medius
- Gluteus minimus
- Tensor fasciae latae

D: Analyze the functional significance of Hilton's law in terms of reflexes arising from receptors in the joint capsule.

Hilton's law states that nerves supplying a joint also innervate the muscles moving it and the overlying skin. Mechanoreceptors and nociceptors in the joint capsule detect stretch, pressure or injury and trigger protective spinal reflexes. These reflexes cause immediate protective muscles spasm or inhibition to stabilize the joint and prevent excessive damaging movement.

E: Deduce the effects of nerves lesions related to the region.

Nerve lesions in the ~~upper~~ and lower limbs result in specific motor and sensory deficit.

1) Radial nerve: wrist drop and loss of elbow/wrist extension
2) Median nerve: Ape hand deformity and loss of thumb opposition.
3) Ulnar nerve: claw hand and loss of finger abduction
1) femoral nerve: loss of knee extension and weak hip flexion.
2) Sciatic (common fibular nerve; foot drop and loss of ankle dorsiflexion/eversion.

F: Illustrate the anatomical basis of the Trendelenburg hip test.

Superior gluteal nerve supplies the gluteus medius and gluteus minimus.

When standing on one leg, these muscles contract to keep the pelvis level.

Weakness of nerve injury causes the ~~pt~~ pelvis to drop toward the unsupported (swing) side.

CamScanner

G: Discuss the position of the lower limb in fracture of the neck of the femur and psoas spasm.

psoas spasm - flexed hip.
- slight lateral rotation.
- slight abduction.

H: Explain the importance of the arteries in fractures of the neck of the femur.

Arterial supply determines timing and the chance of treatment of fractures

POPLITEAL FOSSA AND BACK OF THE LEG

Exercise 7

Objective Led Questions about the Popliteal Fossa and Back of the Leg

A: Draw and show the arrangement of the muscles, blood vessels and nerves of the region.

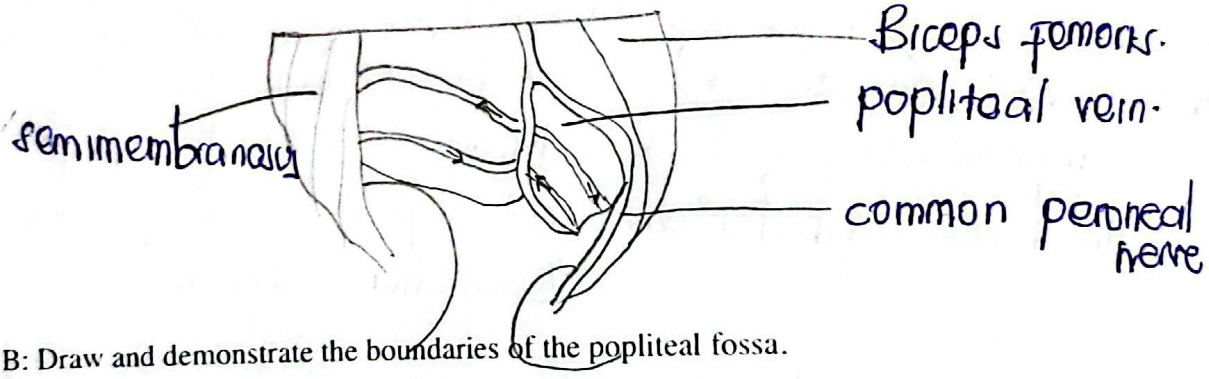

B: Draw and demonstrate the boundaries of the popliteal fossa.

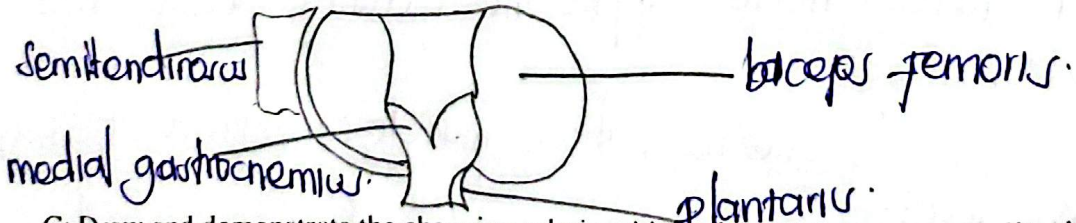

C: Draw and demonstrate the changing relationships of the tibial nerve, popliteal vein and artery.



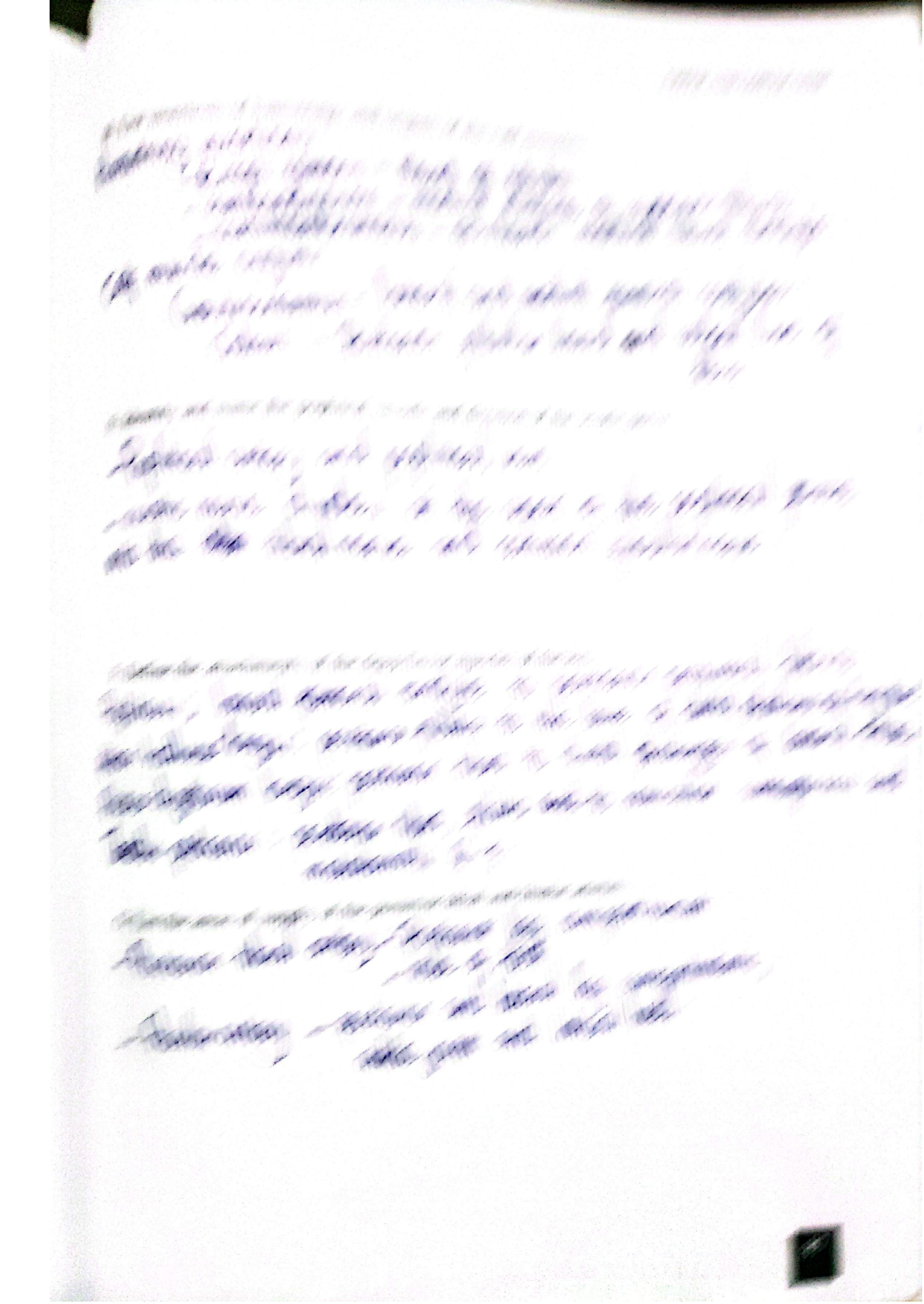

H: List the order of the structures passing beneath the flexor retinaculum.

Tendons of tibialis posterior, flexo digitorum posterior.
Tibial artery and vein, tibial nerve.

Overview of Schedule 10

Before you begin dissection note:

ANTERIOR AND LATERAL ASPECTS OF THE LEG AND DORSUM OF THE FOOT AND THE KNEE JOINT

Relevant skeletal features:

Tibia - borders and surfaces;

Fibula - borders and surfaces;

bones of foot - tarsus; metatarsus; phalanges.

Subcutaneous structures:

superficial fibular nerve; cutaneous nerves of calf region such as the saphenous nerve: deep fibular nerve; great saphenous vein; small saphenous vein.

Deep fascia:

osteofascial compartments; extensor retinacula; fibular retinacula.

Muscles:

fibularis longus; fibularis brevis; tibialis anterior; extensor hallucis longus; extensor digitorum longus; fibularis tertius; extensor digitorum brevis.

Nerves:

superficial fibular nerve; deep fibular nerve.

Arteries:

anterior tibial artery; dorsalis pedis.

Clinical anatomy:

dorsalis pedis arterial pulse; intravenous infusion into great saphenous vein.

KNEE JOINT

Relevant skeletal features:

Femur - areas for tibia and patella; intercondylar notch;

patella - condylar articular area; intercondylar eminence and tibia tubercles; tibial tuberosity.

Muscles in relation to capsule of joint:

quadriceps; sartorius; gracilis; semitendinosus;semimembranosus; adductor magnus; gastrocnemius; popliteus; fibularis longus.

Capsule:

attachments.

Ligaments: tibial collateral, fibular collateral; oblique popliteal.

Intraarticular structures: cruciate ligaments; menisci; popliteus tendon.

Synovial membrane: reflection; infrapatellar and alar folds; suprapatellar bursa.

Articular surfaces: articular cartilage.

Nerve supply: genicular nerves.

Blood supply: genicular arteries.

Movements: flexion; extension and rotation; 'locking' and 'unlocking' of knee joint.

CamScanner

Exercise 14

Objective Led Questions on Review of the Lower Limb 2

A: Draw and show a pictorial arrangement of the nerve supply of the lower limb.

Lumber plexus (L1-L4) – femoral [nerve → saphenous nerve
obturator nerve.
Lumber plexus.
sacral plexus (L4 - S4 - superior gluteal nerve → gluteus medius
inferior gluteal
sciatic nerve ← tibial nerve ← common fibular

B: Draw and show a pictorial Illustration of the surface markings of the sciatic, tibial, common fibular, femoral and saphenous nerves.

femoral nerve - mid inguinal
saphenous nerve - behind medial femoral condyle.
sciatic nerve - mid point 10 ischial tuberde

C: Explain the motor and sensory deficits in lesions of the femoral, sciatic, tibial and common fibular nerves.

quadriceps paralysis
Paialysis of hamstrings
loss of plantar flexion
loss of dorsiflexion and eversion.

D: Describe and demonstrate the segmental innervation of the joints, muscles and skin

skin L1 (groin) L2-L3 medial thigh
L5 (dorsum of foot L4 (great toe) extension) L4 - S1)

Exercise 15

Objective Led Questions on Review of the Lower Limb 3

A: Explain the anatomical basis of the maintenance of the erect posture and walking

line of gravity passes behind hip anterior to knee and anterior ankle positively locking joints.

B: Analyse the maintenance of the erect posture by discussing some important muscular and ligamentous supports in the hip, knee and ankle joints.

Hip: hyper extension checked passively.
gluteus medius prevent pelvic drop in single leg stand
knee, hyperextension checked by oblique popliteal
cruciate and collateral ligament

C: Demonstrate the walking cycle with the muscles involved in each phase.

stance, phase, heel strike.