minor and drain [illegible]

(b) long the internal thoracic artery to the **internal thoracic ly[illegible]** costal arteries to the **posterior intercostal nodes**. Rarely, lymphatics from the breast may = into the abdomen between the xiphoid process and the costal margin to end in the **diaphragmatic nodes.** They may even communicate with the lymphatics of the opposite breast.

Exercise 1:

Objective Led Questions about the Pectoral Region and Axilla

Draw and show a pictorial arrangement of the muscles in relation to the axilla.

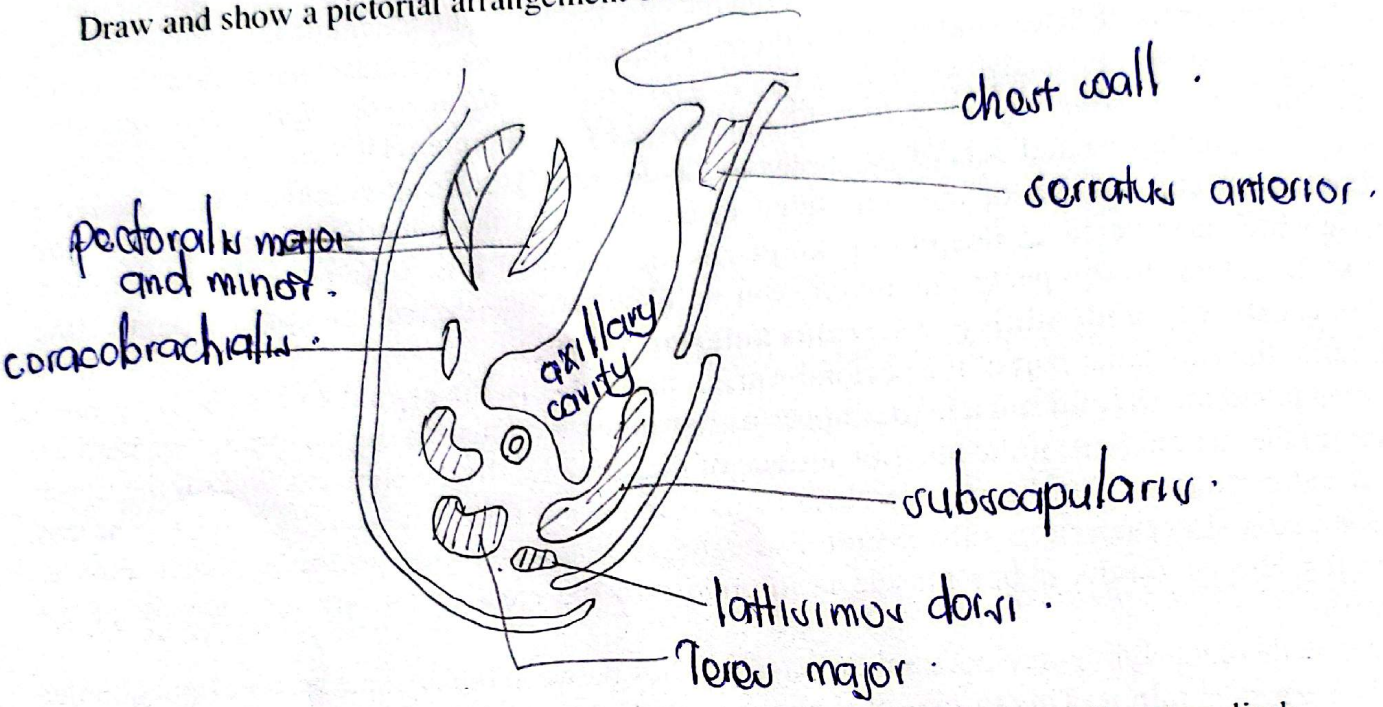

Explain why the pectoral region is the link between the trunk and mobile upper limb.

it contains muscles, nerves and blood vessels that link the trunk to the limb; " that stabilize the limb.

ii. Demonstrate the actions of pectoralis major and minor.

Pectoralis major; adduction of arm, medial rotation of arm.
Pectoralis minor; stabilizes the scapula against thoracic wall

iii. What muscles contribute to the formation and contour of the anterior and posterior axillary folds.-

Anterior- Pectoralis major.
Posterior- Latissimus dorsi.
Teres major.

CamScanner

iv. Define the omponents of medical and lateral walls of the axilla.

medial ; Ribs, intercostal muscles, serratus anterior.

lateral ; intertubercular sulcus, coraco brachialis, short head of biceps brachii

B: Draw and show the arrangement of the nerves and blood vessels of the Axilla:

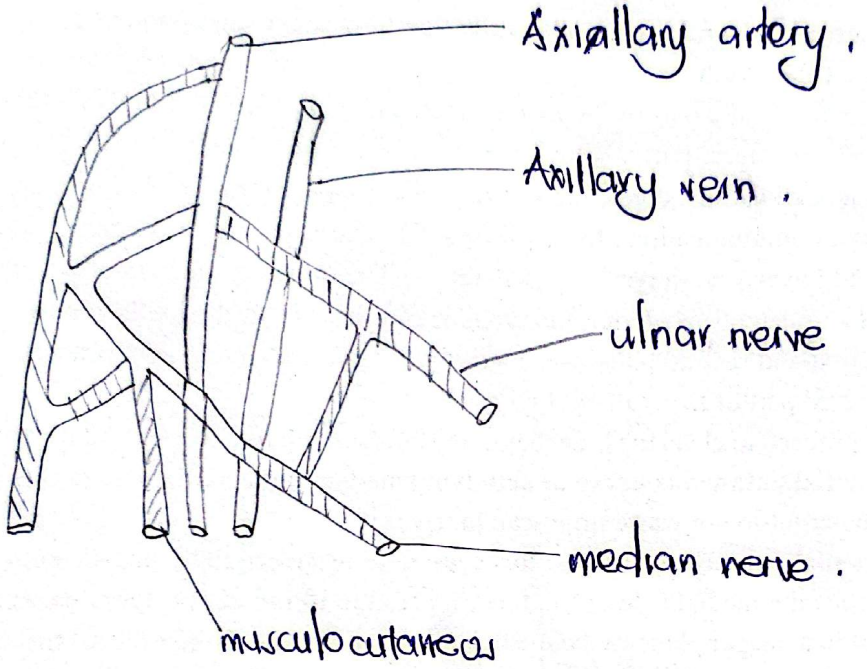

i. Explain how the apex of the axilla forms the highway for nerves and blood vessels between the neck and upper limb.

Apex is bounded by clavicle, first rib, and superior boarder of scapula.
It transmits axillary artery, axillary vein, cords of brachial plexus and lymphatic vessels; from root of neck and upper limb.

ii. Describe the surface marking of the axillary artery and define its extent.

Extent;
Begins from lateral border of first rib as a continuation of subclavian artery to the inferior border of teres major where it becomes brachial artery.

iii. Identify the roots, trunks, divisions and cords of the brachial plexus in prosected specimens.

Roots ; C5, C6, C7, C8, T1
Trunks ; upper trunk (C5 & C6), middle trunk (C7), lower trunk (C8 & T1)
~~Cords~~
Divisions ; three anterior and three posterior divisions.
Cords ; Lateral, Medial and Posterior cords.

iv. Illustrate the functional aspects of the divisions of the plexus.

Anterior division ; mainly supply anterior compartment of upper limb ie flexor compartment.

Posterior division ; mainly supply posterior compartment of upper limb ie extensor compartment.

v. Explain this functional subdivision by taking individual nerves in turn.

musculocutaneous nerve - supplies anterior arm muscles.
Radial nerve - extensor compartment of forearm.
median nerve - most anterior forearm muscles
ulnar nerve - some anterior forearm muscles & intrinsic muscles of hand
Axillary nerve - Deltoid & teres minor.

vi. Surface mark the pectoralis minor muscle and discuss why it is the key structure of the region.

• Deep of pectoralis major, 3-5 ribs.
* Becoz it divides the axillary artery into 3 parts &
provides attachment of clavipectoral fascia.

2. Draw and label the general anatomy of the breast

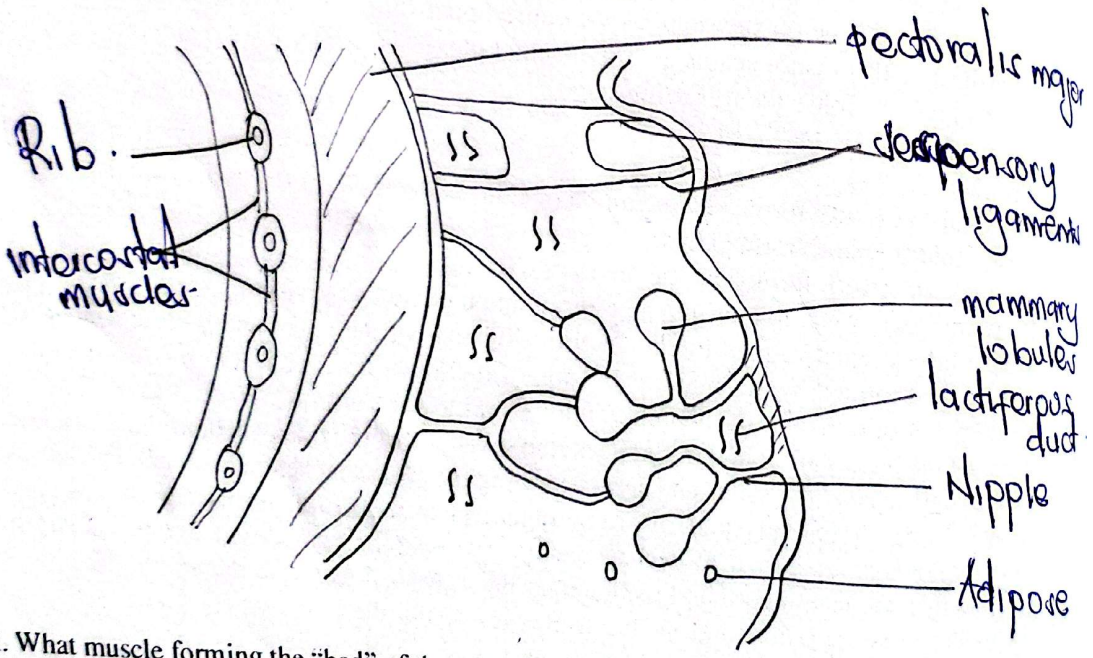

i. What muscle forming the "bed" of the adult female breast?

Pectoralis major.

ii. What forms the base of the gland and the axillary tail?

pectoral fascia covering pectoralis major.

iii. Outline the blood supply of the organ.

- Lateral thoracic artery.
- Perforating branches of internal thoracic artery.
- Pectoral branches of ~~to~~ thoracoacromial artery.

iv. Outline routes of lymph drainage of the breast.

- Axillary lymph nodes
- Parasternal lymph nodes.
- Posterior intercostal nodes.
- subdiaphragmatic and abdominal nodes.

v. Discuss the clinical importance of thee knowledge of the blood supply and lymphatic drainage of the breast.

- lymphatic drainage explains the spread of ~~co~~ breast cancer to axillary lymph nodes.
- Obstruction of lymphatic vessels may cause breast or upper limb odema.
- Arterial supply helps to prevent excessive bleeding during breast surgery.

DISSECTION SCHEDULE 2:

DISSECTION OF THE FRONT OF ARM AND CUBITAL REGION

CamScanner

Objective Led Questions about the Front of the Arm and Cubital Fossa

General Question:

Draw and demonstrate the arrangement of the muscles, nerves and blood vessels of the region

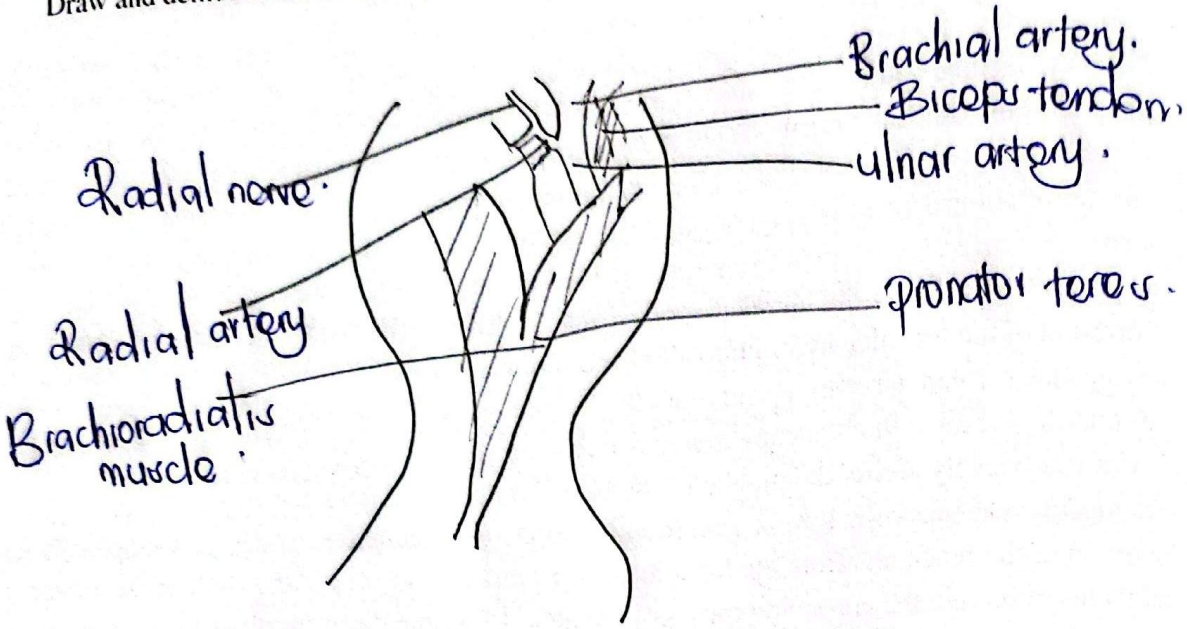

Specific questions

1. What are the components of the flexor and extensor compartments of the arm?

Flexor - Biceps brachii: Extensor - Triceps brachii:
- Brachialis: - Anconeous:
- Coracobrachialis:

2. What are the actions of individual muscles of the flexor compartment?

Biceps brachii; - flexes elbow; supinates forearm
Brachialis; main flexor of elbow
Coracobrachialis; Adducts the arm; flexes the arm at shoulde

3. Define the position of the neurovascular bundle (median nerve and brachial artery) in the upper and lower parts of the arm and their relationship to the humerus.

Upper part of arm; brachial artery lies medial to humerous
median nerve lies lateral to the brachial artery
Middle part; median nerve crosses anterior to the brachial artery form lateral to medial.
lower part; median nerve lies medial to brachial artery
Both structures pass anterior to the elbow into the cubital fossa.

4. Discuss the effects of lesion of the nerves supplying the flexor group in terms of segment innervation of the elbow joint.

musculocutaneous nerve injury ; weakness of elbow flexion & forearm supination.
median nerve injury ; weaken elbow flexion *
loss of biceps reflex ; may be due to damaging C5 & C6.

5. Surface mark the brachial artery and illustrate the points of arterial compression, the site for recording blood pressure and the vulnerability of the brachial artery in fractures of the lower end of the humerus (supracondylar fractures).

• Begins at the inferior boarder of teres major; Runs along medial aspect of arm; ends in the cubital fossa.
• It can be compressed against humerous ; medial aspect of arm
* It is auscultated in the cubital fossa medial to biceps tendon
* supracondylar fractures may damage brachial artery reducing blood supply to forearm and hand; also leading to ischaemia.

6. Explain the vulnerability of: (a) the median nerve in supracondylar fractures, and (b) the unlar nerve in fracture of the medial epicondyle.

a) ~~It may be at~~ median nerve passes anterior to the distal humerous it may be compressed or injured ; causing weakness in pronation of forearm
b) passes behind medial epicondyle in cubital tunnel ; cause weakness of intrinsic hand muscles & sensory loss of little finger

7. Describe the boundaries and contents of the cubital fossa.

Boundaries :
medial - pronator teres.
lateral - Brachioradialis
Floor - Brachialis & supinator.
superior - imaginary line joining epicondyles.

Contents -
- Radial nerve.
- Biceps brachii tendon
- median nerve.
- Brachial artery.

DISSECTION SCHEDULE: 3

1. Draw and demonstrate the arrangements of the muscles of the back of trunk, scapular region and back of arm.

DISSECTION SCHEDULE: 4

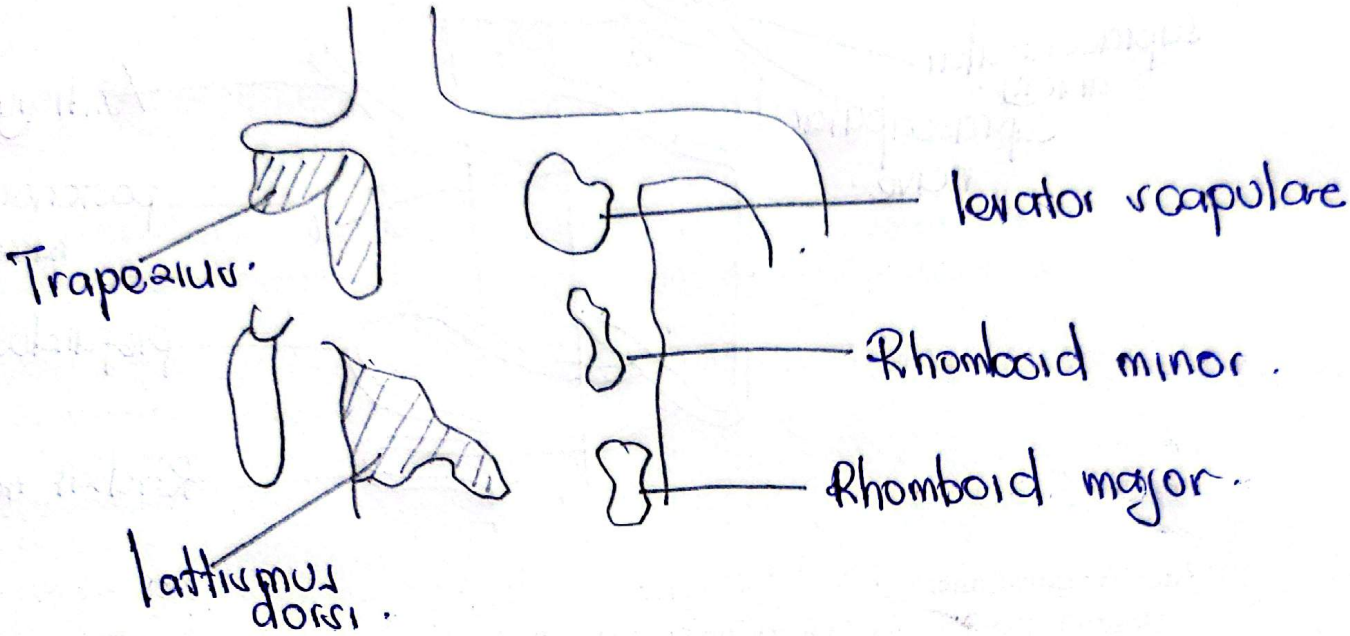

Specific questions:

i. Describe the attachments of the first and second layers of the back muscles.

1st layer; Trapezius - origin - occipital bone & lig. clavicle
latissimus dorsi - lower thoracic & Bicipital groove.

ii. Describe the attachments of the muscles on the ventral and dorsal surfaces of scapula.

ventral; subscapularis; from subscapular fossa to lesser tubercle.
dorsal; supraspinatus; from supraspinous fossa to greater tubercle.
Infraspinatus; from infraspinous fossa to greater tubercle.

iii. Describe the attachments of the muscles on the medial and lateral borders of the scapula.

medial - Levator scapulae.
- Rhomboid minor.
- Rhomboid major.
- Serratus anterior.

Lateral: - teres minor.
- teres major.
- long head of biceps brachii.

iv. Describe the three heads of the triceps brachii and its actions

long head; from infraglenoid tubercle; for adduction of arm &
lateral head; posterior humerous above radial groove
medial; posterior humerous below radial groove.

v. Describe the boundaries of the quadrangular space and the structures passing through it.

Boundaries
superior - teres minor.
inferior - teres major.
medial - long head of triceps.
lateral - surgical neck of humerous.

Content - Axillary nerve.
- posterior circumflex humeral artery & accompanying veins.

General Questions 2

2. Draw and demonstrate the arrangement of the nerves and blood vessels of back of trunk scapular region and back of arm.

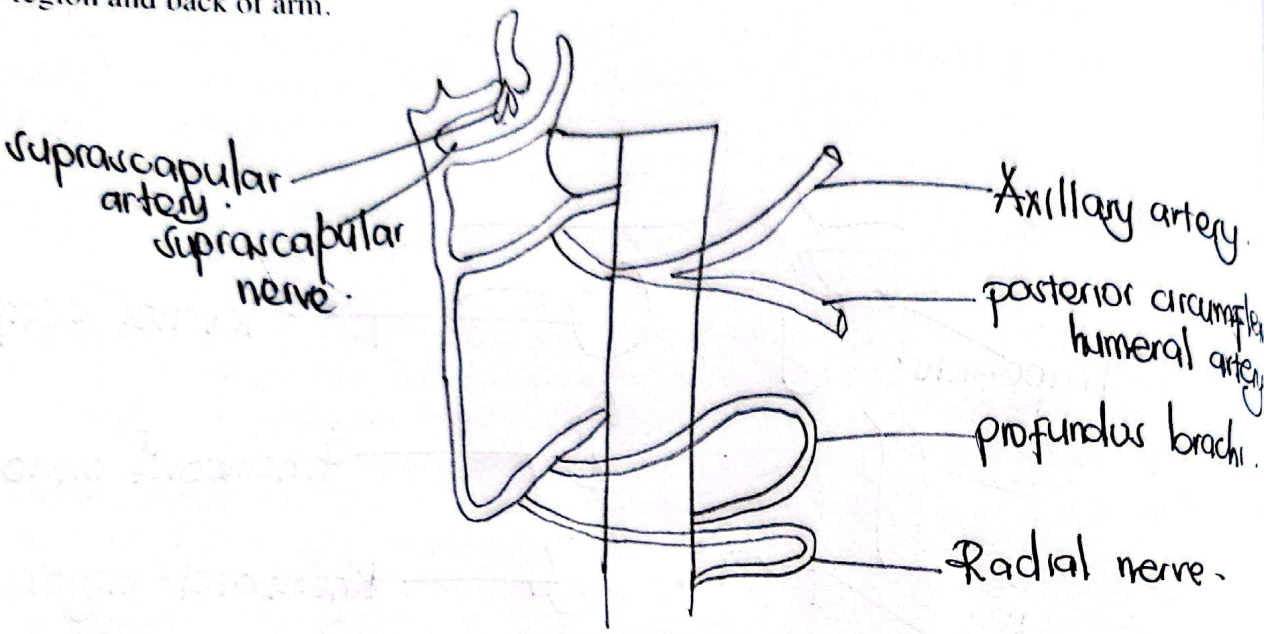

Specific questions:

1. Describe the segmental innervation of the skin of the back of the trunk by dorsal rami.
Skin is supplied by dorsal rami of spinal nerves which divides into medial and lateral cutaneous branches.

2. Explain the significance of the innervation of most of the scapular muscles by the posterior divisions of the brachial plexus.
Posterior division contribute to the posterior cord, this gives rise to the axillary and radial nerves; these supply important posterior upper limb muscles & cordinated movement of shoulder and arm.

3. Discuss the clinical importance of the segmental nerve supply of the elbow joint.
- Helps localise nerve root injuries.
- Helps assess the biceps tendon reflex (C_5-C_6)
- Helps assess the triceps tendon reflex (C_7-C_8)

4. Surface mark the radial and axillary nerves in the arm.
Axillary nerve - passes through quadrangular space and winds around surgical neck to deltoid.
Radial nerve - passes posteriorly thru triangular interval # and runs through radial groove.

5. Describe the effects of lesion of:
(a) the axillary nerve in fracture of the neck of the humerus;
Deltoid paralysis or weakness; weakness of arm abduction beyond 15°, weakness of lateral rotation, sensory loss over the upper lateral arm.

CamScanner

(b) the radial nerve in a mid-shaft fracture
wrist drop due to paralysis of wrist extensors; weakness in fingers and thumb extension; sensory loss over dorsum of hand.

DISSECTION SCHEDULE: 4

THE DISSSECTION OF THE JOINTS OF THE SHOULDER REGION

1. The Sternoclavicular Joint:

Relevant skeletal features: manubrium; medial end of clavicle; first costal cartilage.
Muscles in relation to capsule of joint: pectoralis major; sternocleidomastoid; subclavius.
Capsule: attachments.
Ligaments: anterior and posterior stemoclavicular; interclavicular, costoclavicular.
Synovial membrane: reflection.
Intraarticular structures: articular disc.
Articular surfaces: size of sternal and clavicular articular surfaces.
Movements: gliding; rotation.
Nerve supply: medial supraclavicular, nerve to subclavius

2. The Acromioclavicular Joint:

Relevant skeletal features: lateral end of clavicle; acromion process of scapula.
Muscles in relation to capsule of joint: trapezius; deltoid.
Capsule: attachments.
Ligaments: coracoclavicular.
Synovial membrane: reflection. Intraarticular structures: articular disc sometimes present.
Movements: gliding; rotation.
Nerve supply: suprascapular; lateral
Clinical anatomy: dislocation.

3. The Shoulder Joint:

Relevant skeletal features: glenoid cavity; head of humerus.
Muscles in relation to capsule of joint: deltoid: rotator cuff muscles; long head of biceps: long head of triceps.
Capsule: attachments.
Ligaments: coracoacromial; coracohumeral; glenohumeral. Intracapsular structures: tendon of long head of biceps.
Synovial membrane: reflection.
Particular surfaces: humeral and glenoidal articular surfaces: labrum glenoidale.
Movements: flexion; extension; abduction; adduction; medial and lateral rotation; circumduction.
Nerve supply: suprascapular, axillary: lateral pectoral.
Clinical anatomy: dislocation.

CamScanner

...classified into superficial and deep groups. The superficial set comprises the brachioradialis, extensor carpi radialis longus and brevis which are situated laterally (marginal group) and the extensor digitorum, extensor digiti minimi and extensor carpi ulnaris which occupy the dorsal aspect of the forearm. The deep group is formed by the supinator, abductor pollicis longus, extensor pollicis brevis, extensor pollicis longus and the extensor indicis. All these muscles are supplied by the radial nerve or its branches. Consequently, in cases of injury to the radial nerve, the extensor muscles will be paralysed leading to a condition known as wrist drop.

EXERCISE 4:

1. Draw and show the arrangement of the bone and ligaments of the joints of the shoulder girdle.

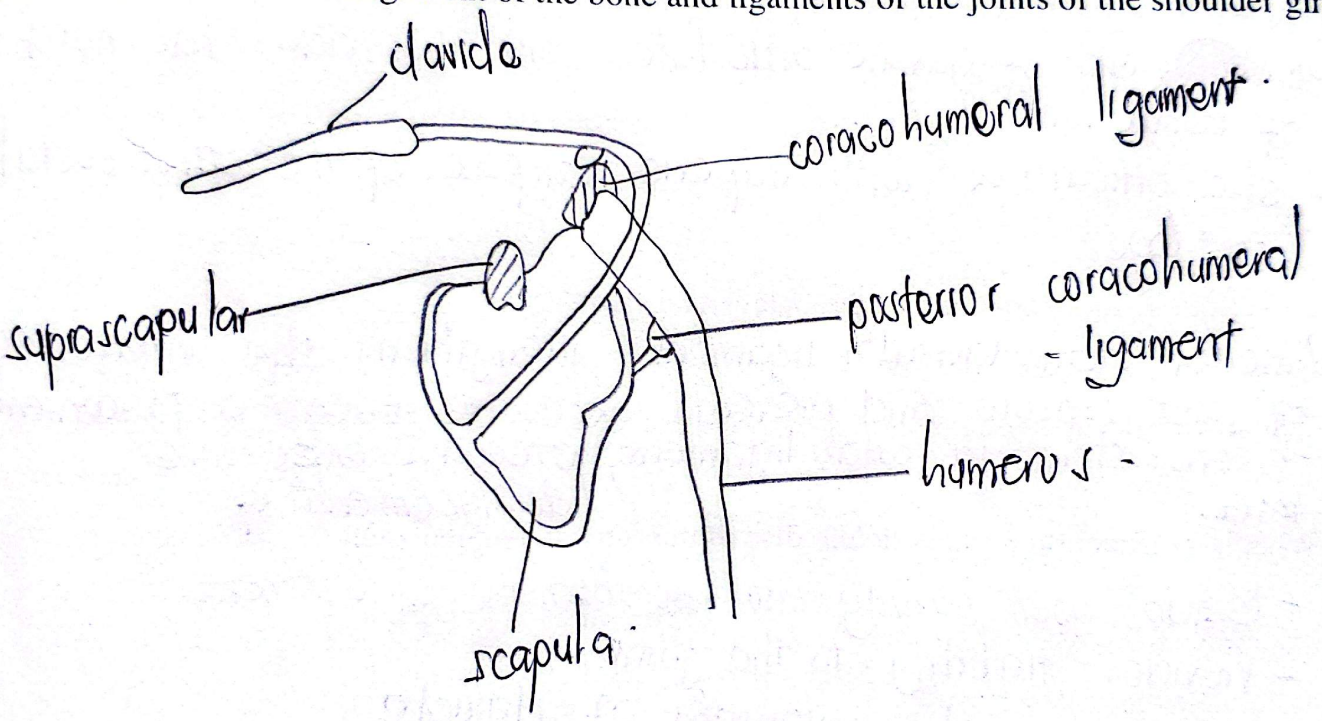

CamScanner

2. Draw a sketch diagram showing the topographical relationship of the sternum, clavicle, scapula and humerus.

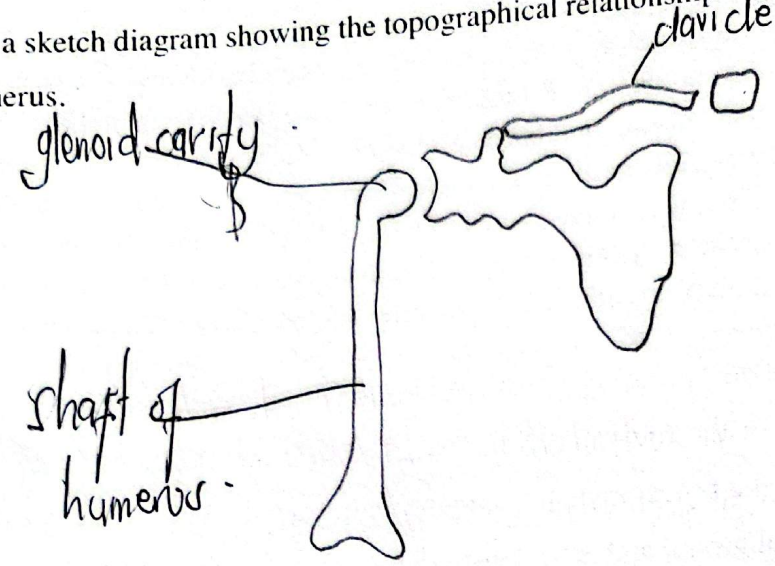

3. Describe the articulation of the clavicle with the sternum and first costal cartilage and compare the clavicular and sternal articular surfaces.

It is a synovial saddle-type joint;
- medial end of clavicle articulates with the clavicular notch of manubrium sterni.
- also articulates with superior surface of the first costal cartilage.

4. Describe the ligaments of the sternoclavicular joint.

- Anterior sternoclavicular ligament; strengthens the anterior aspect of joint capsule and prevents excessive anterior displacement.
- Posterior sternoclavicular ligament; prevents excessive displacement of.
- ~~[illegible]~~

5. What is the function of the articular disc of the sternoclavicular joint?

- Divides joint cavity into two separate compartments.
- Provides stability to the joint.
- Allows smooth movement of clavicle
- Improves the congruity of the articular surface.

CamScanner

6. Describe the Articulation of the clavicle with the acromion.

- Plane synovial joint.
- Between lateral end of clavicle and medial margin of acromion.
- Articular surfaces covered by fibro cartilage.

7. Name the ligaments of the acromioclavicular joint.

- Acromioclavicular ligament.
- Coracoclavicular ligament. { conoid ligament / Trapezoid ligament

8. What is the role of the coracoclavicular ligament?

- Connect coracoid process to the clavicle.
- Prevent excessive separation of clavicle and scapula.
- Provides strong stability of joint.

9 Describe the articulation of the huerus with the scapula.

- Synovial ball and socket joint.
- Head of humerous and glenoid cavity of scapula.
- Articular surfaces are covered by hyaline cartilage.

10. Describe the articulation of the humerus with the scapula.

- Synovial ball and socket joint.
- Head of humerus and glenoid cavity of scapular.
- Articular surfaces are covered by hyaline cartilage.

11. Describe the attachment of the capsular, transverse and coracohumeral ligaments of the shoulder.

Capsular ligament (joint capsule) medially - glenoid cavity.
laterally - anatomical neck of humerous.

Transverse humeral ligament - Both lesser and greater tubercle.

Coracohumeral ligament - coracoid process to greater tubercle.

12. Identify the anatomical and the surgical neck of the humerus.

Anatomical ; - slight groove immediately surrounding head of humerous.

Surgical ; narrow region distal to greater and lesser tuberdey; common # fracture

13. Discuss the stability of the shoulder joint.

Relatively less stable.
- humeral head articulates with glenoid cavity.
- attached by ligaments - glenohumeral, coracohumeral, lig.
- muscles like supraspinatous / infraspinatus / teres minor.

14. Describe the innervation of the shoulder joint based on Hilton's law.

Joint is innervated by Axillary nerve, suprascapular nerve and lateral pectoral nerve which supply the muscles around the joint.

15. Explain how movements of the shoulder joint are associated with movements of the acromioclavicular and sternoclavicular joints.

Abduction; scapula rotates upwards at acromioclavicular joint as the clavicle elevates at sternoclavicular joint.

Extension; scapular retracts with associated mov'ts of clavicle.

16. Classify the muscles acting on the shoulder joint into fleexors, extensors abductors, adductors and rotators.

Flexion - deltoid.
- ~~the~~ biceps brachii
- coracobrachialis.
- pectoralis major.

Extension
- Deltoid.
- Latissimus dorsi
- teres major.
- long head of triceps.

Rotators
- supraspinatus
- infraspinatus
- subscapularis.
- teres minor.

17. Outline the role of the rotator cuff muscles.

supraspinatus - initiates abduction.
infraspinatus - lateral rotation.
teres minor - lateral rotation
subscapularis - medial rotation.

CamScanner

18. Explain the effects of paralysis of the deltoid, supraspinatus and serratus anterior.

Deltoid; loss of abduction beyond 15° to 90°.
supraspinatus; initiate abduction 15° lost.
serratus anterior paralysis; cause winging scapula.

19. Explain the role of serratus anterior, trapezius, rhomboids and levator scapulae in scapular rotation.

upward rotation, upward rotation, downward rotation, downward rotation.

2. DISSSECTION OF THE BACK OF THE FOREARM AND HAND

General objective 1

Understand the disposition of the muscles in the region.

Specific objectives:

1. Enumerate the muscles of the superficial and deep extensor groups.
2. Define the osteofascial compartments on the back of the wrist and enumerate the tendons passing through each compartment.
3. Define the formation and termination of the extensor expansions to each digit.
4. Comment on the tendons to the thumb, index finger and little finger.

General objective 2

Comprehend the arrangement of the nerves and blood vessels of the region.

Specific objectives:

1. Define the muscles supplied by the radial nerve and its branches.
2. Indicate the segmental innervation of the wrist joint and the joints of the fingers.
3. Explain wrist drop in anatomical terms.
4. Analyse the cutaneous innervation and dermatomic pattern of the region.
5. Trace the origin, course and termination of the basilic and cephalic veins.

Relevant skeletal features:

Humerus - medial epicondyle; medial supracondylar ridge;
Radius - head; surfaces; borders; styloid process;
Ulna - surfaces; borders; head; styloid process;
Carpus - hook of hamate; tubercle of scaphoid; pisiform; tubercle of trapezium; metacarpus phalanges.

Subcutaneous structures:

Medial cutaneous nerve of forearm; lateral cutaneous nerve of forearm; Palmar cutaneous branch of ulnar nerve; palmar cutaneous branch of Median nerve; digital nerves and vessels; cephalic basilic and median cubital veins.

Deep fascia:

Flexor retinaculum; palmar aponeurosis; fascial septa of the hand; fibrous flexor sheaths

Ligaments:

Deep transverse metacarpal ligaments.

CamScanner