# Fetal Membranes, Umbilical cord and Placenta

# Fetal Membranes

- The membranous structures closely associated with or surrounding the embryo during its developmental period .
- Develop from the zygote
- Since such membranes are external to the embryo proper, they are called extraembryonic membranes and Include the:

**1- Amnion**

**2- Chorion**

**3- Allantois**

**4- Yolk sac**

Umbilical cord and Placenta are derived from them.

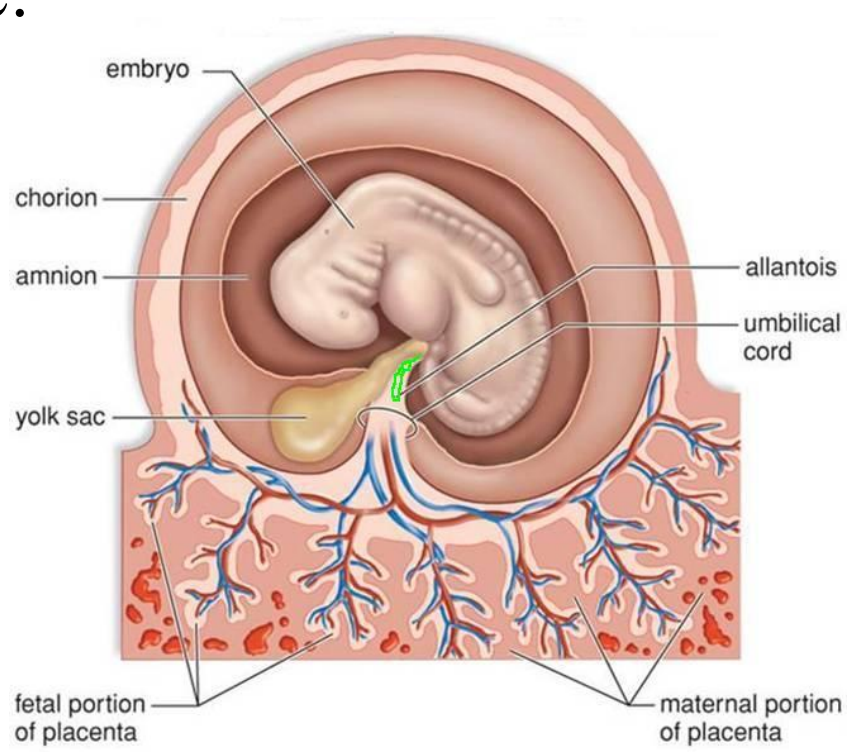

# Fetal Membranes function

- They function in the embryo's protection, nutrition, respiration, and excretion.
- The chorion & amnion do not take part in the formation of the embryo or fetus.
- Part of the yolk sac is incorporated into the embryo as the primordium of the gut.
- The allantois forms a fibrous cord called urachus

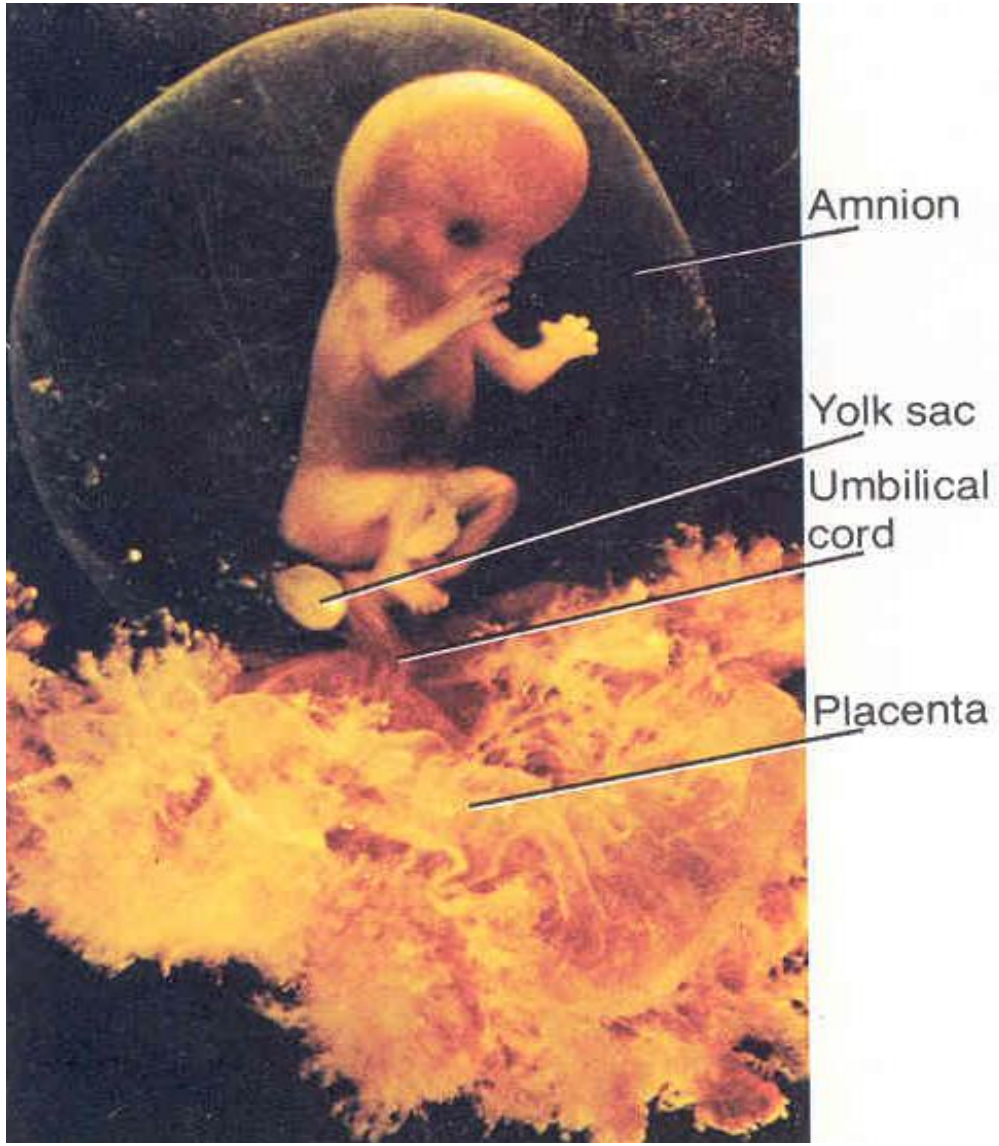

# Amnion

- The Amnion is a thin protective membrane that surrounds the embryo/ fetus
- Starts developing, in the early 2nd week (8th day) after fertilization, as a closed cavity in the embryoblast
- The amniotic cavity is roofed in by a single layer of flattened cells, the amnioblasts (amniotic ectoderm), and its floor consists of the epiblast of the embryonic disc
- Outside the amniotic ectoderm is a thin layer of extraembryonic mesoderm



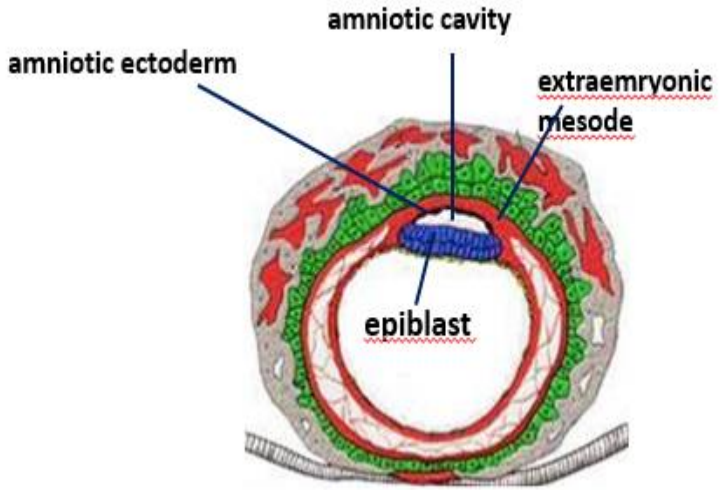

- The amniotic fluid increases in quantity and causes the amnion to expand.

- The amnion ultimately adheres to the inner surface of the chorion, so that the chorionic cavity is obliterated.

- The fused amnion and chorion form the amnio-chorionic membrane.

- Further enlargement of amniotic cavity results in obliteration of uterine cavity and fusion of amniochorionic membrane (covered by decidua capsularis), with the decidua parietalis.

- Amniochorionic membrane usually ruptures just before birth

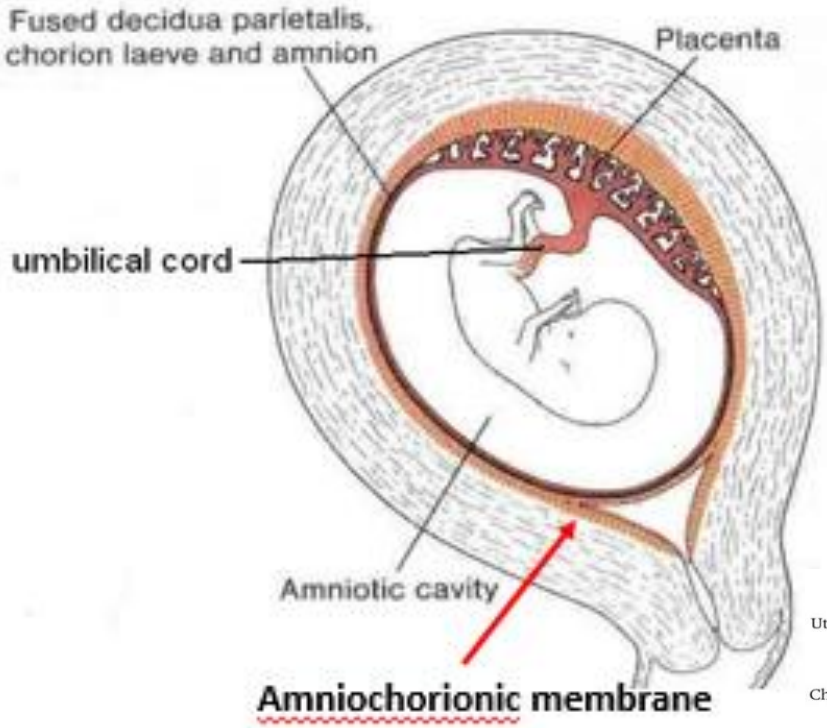
Fused decidua parietalis, chorion laeve and amnion
Placenta
umbilical cord
Amniotic cavity
Amniochorionic membrane

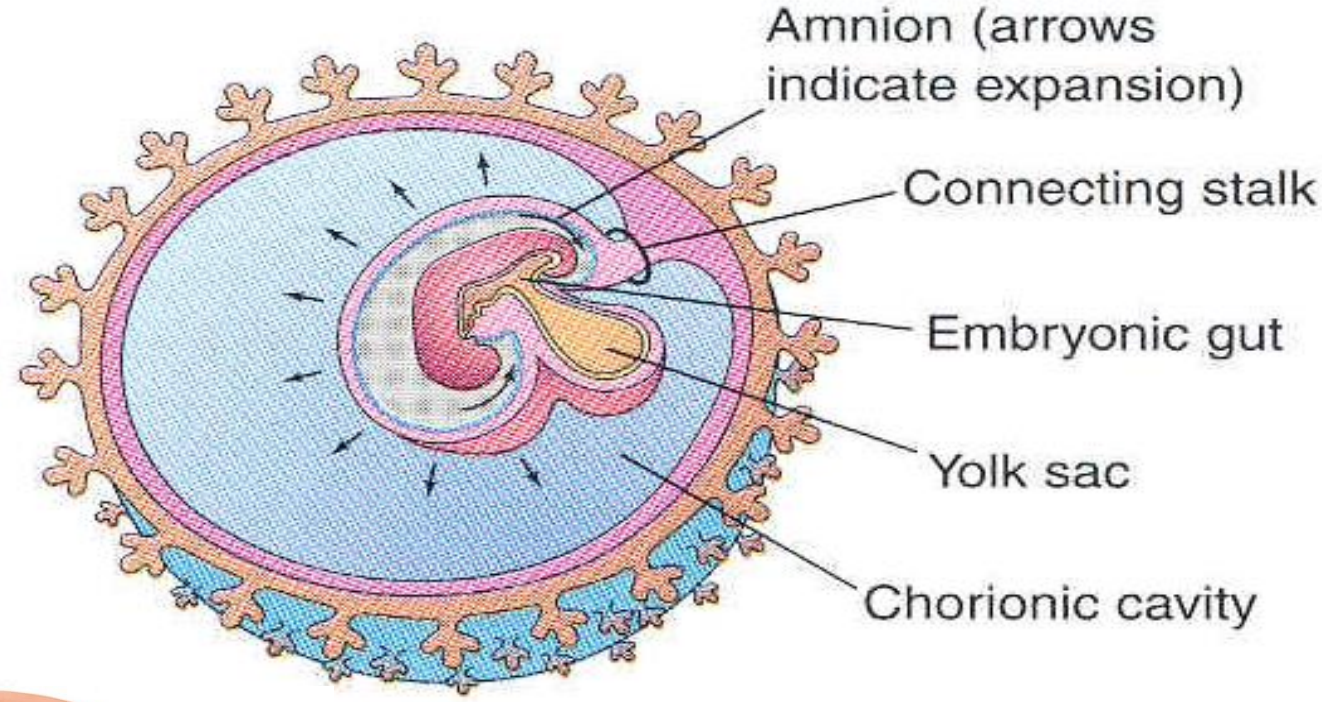
Amnion (arrows indicate expansion)
Connecting stalk
Embryonic gut
Yolk sac
Chorionic cavity

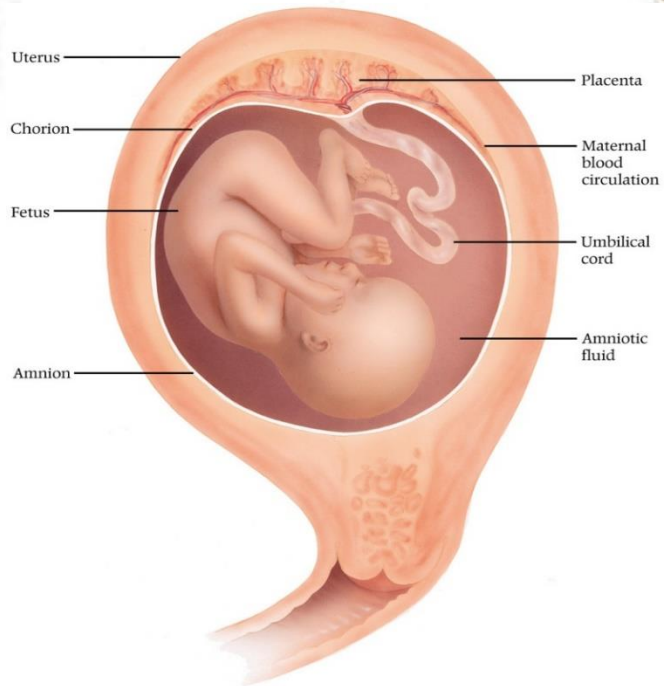
Uterus
Placenta
Chorion
Maternal blood circulation
Fetus
Umbilical cord
Amniotic fluid
Amnion

- The amniotic cavity is filled with a clear, watery fluid that is produced in part by amniotic cells but primarily from maternal blood. Later most of it is derived from the maternal tissue fluid by diffusion.
- The amount of fluid increases from 30 ml at 10 weeks of gestation to 450 ml at 20 weeks to 800 to 1000 ml at 37 weeks.

- Amniotic fluid is a clear, slightly yellowish liquid
- 99% of fluid in the amniotic cavity is water
- Suspended in this fluid are undissolved substances e.g. desquamated fetal epithelial cells, proteins, carbohydrates, fats, enzymes, hormones and pigments.
- As pregnancy advances the composition of amniotic fluid changes as fetal waste products (meconium & urine) are added.

# Function of amniotic fluid

- serves as a protective cushion
- prevents adherence of the embryo to the amnion.
- allows for fetal movements.
- The volume of amniotic fluid is replaced every 3 hours.

# Amniotic Fluid: Circulation

- It is swallowed by the fetus, is absorbed by respiratory & GIT and enters fetal circulation. It then passes to maternal circulation through placental membrane. During final stages of pregnancy fetus swallows about 400ml of amniotic fluid per day.

- Excess water in the fetal blood is excreted by the fetal kidneys and returned to the amniotic sac through the fetal urinary tract.

# Amniotic Fluid: Circulation

- By the beginning of the second trimester the amniotic sac contains 50 ml of the amniotic fluid
- The volume of amniotic fluid increases gradually, reaching about 1000ml by $37^{th}$ week.
- High volume of amniotic fluid i.e. more than 2000 ml is called **Polyhydramnios**. It results when the fetus does not swallow the usual amount of amniotic fluid e.g. in esophageal atresia
- Low volume of amniotic fluid i.e. less than 400 ml is called **Oligohydramnios**. Renal agenesis (failure of kidney formation) is the main cause of oligohydramnios

# Amniotic Fluid: Functions

- The fetus floats in the amniotic fluid. It allows fetus to move freely, aiding development of muscles and bones.
- Prevents adherence of the amnion to the embryo
- Acts as a cushion to protect embryo from injuries
- Acts as a barrier to infection
- Permits normal lung development
- Permits symmetrical external growth of the embryo
- Regulates fetal water/electrolyte balance
- Assists in regulation of fetal body temperature

# Amniocentesis

- Amniocentesis is the removal of a small amount of amniotic fluid from the sac around the baby.
- This is usually performed at 16 weeks in pregnancy.
- A fine needle is inserted under ultrasound guidance through the mothers' abdomen into a pool of amniotic fluid.

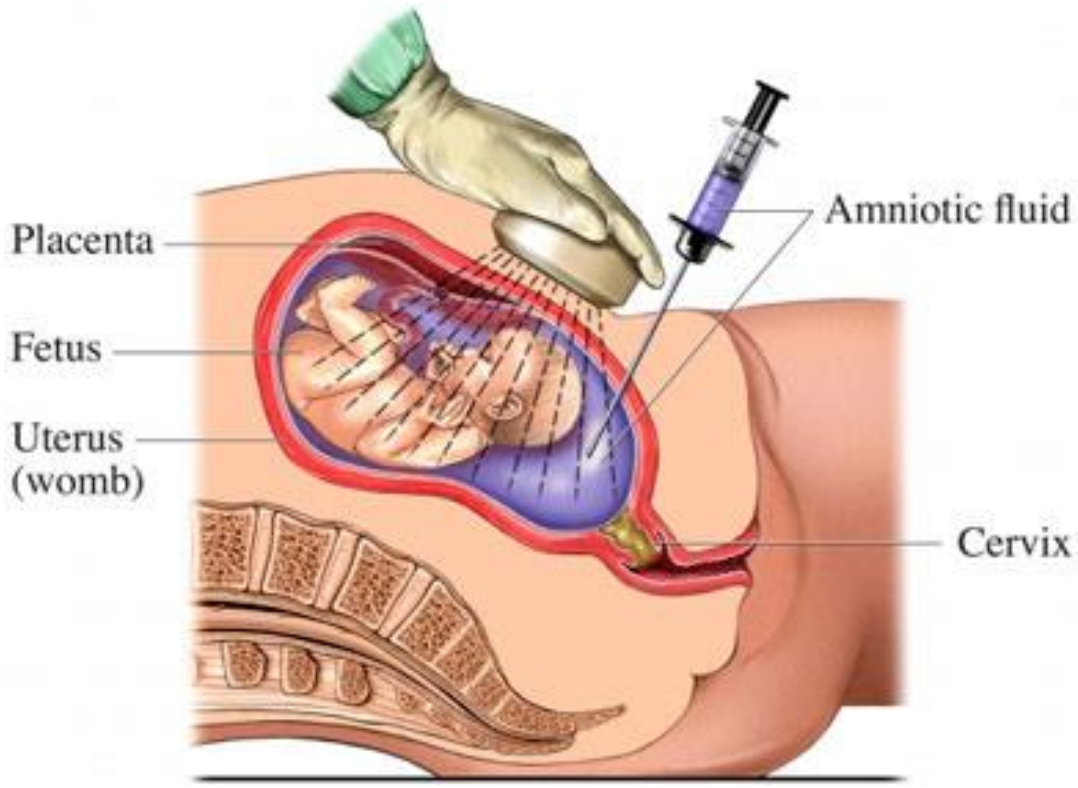

# Chorion

- The outermost of the two fetal membranes (amnion is the inner one)
- Develops in the early second week, as a three layered membrane (extraembryonic mesoderm & two layers of trophoblast)
- Forms the wall of the chorionic cavity (the original extraembryonic celome)

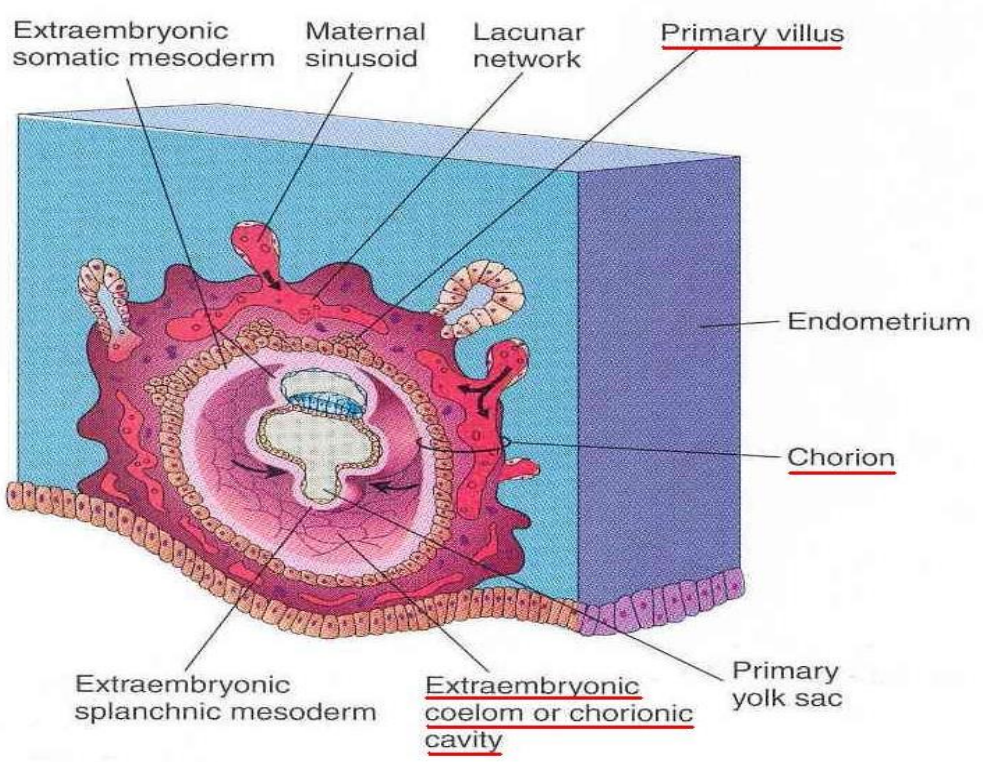

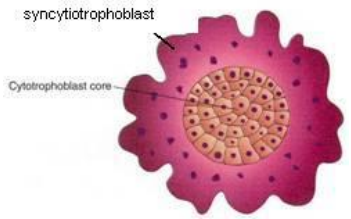


primary villus

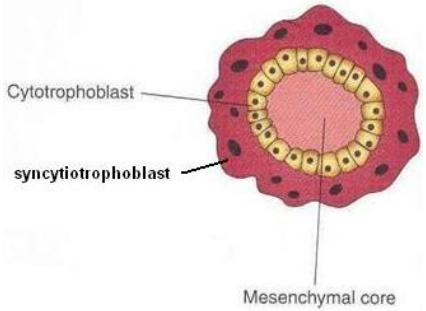


secondary villus

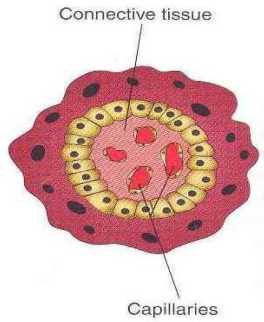


tertiary villus

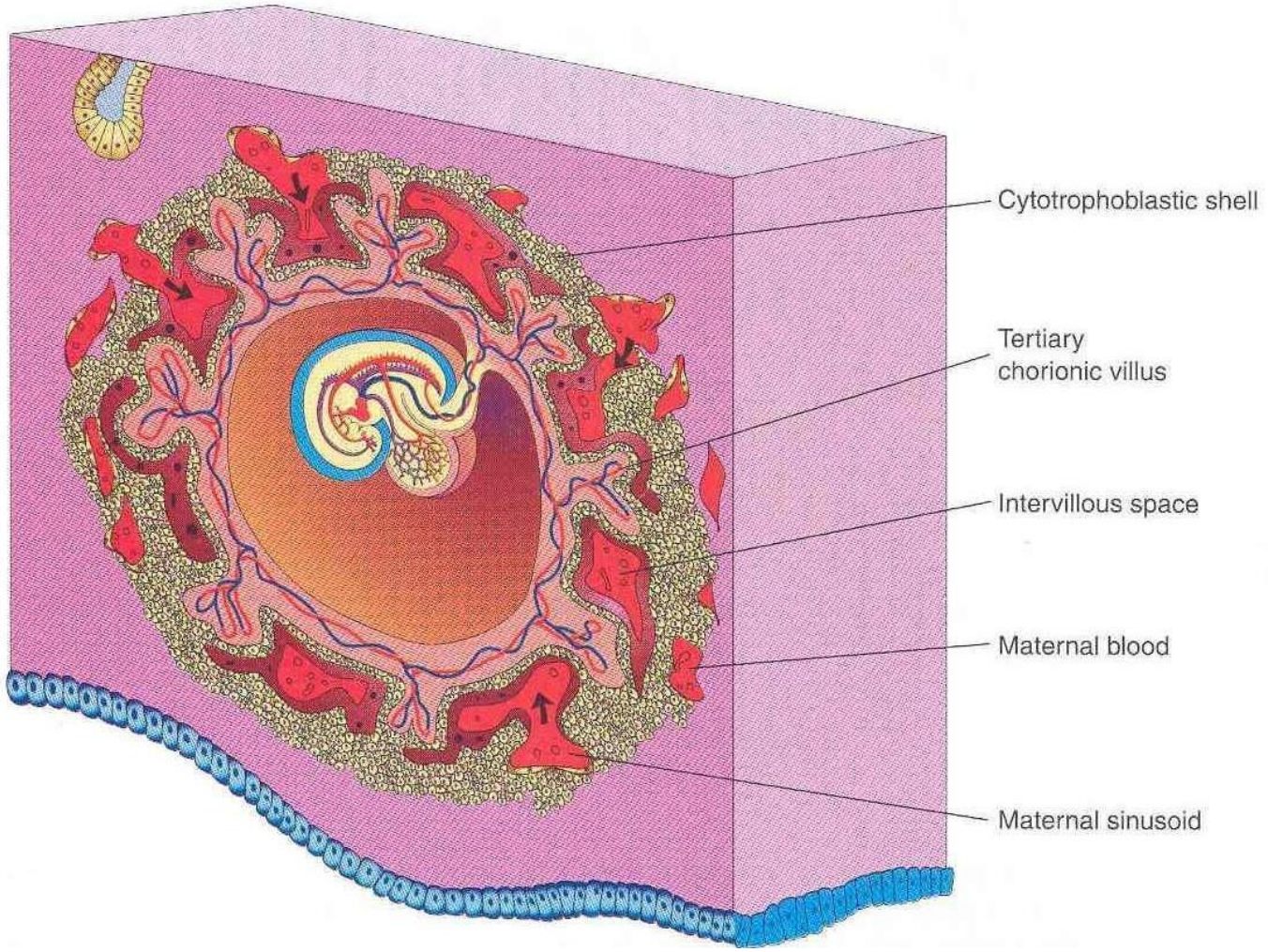


## Chorionic Villi

- As the embryo grows and the amniotic fluid increases in amount, the decidua capsularis becomes extremely stretched. The chorionic villi in this region become atrophied and disappear leaving a smooth chorion (chorion laeve)

- The villi in the region of decidua basalis grow rapidly, branch, and become highly vascular. This region of chorion is called chorion frondosum (villous chorion)

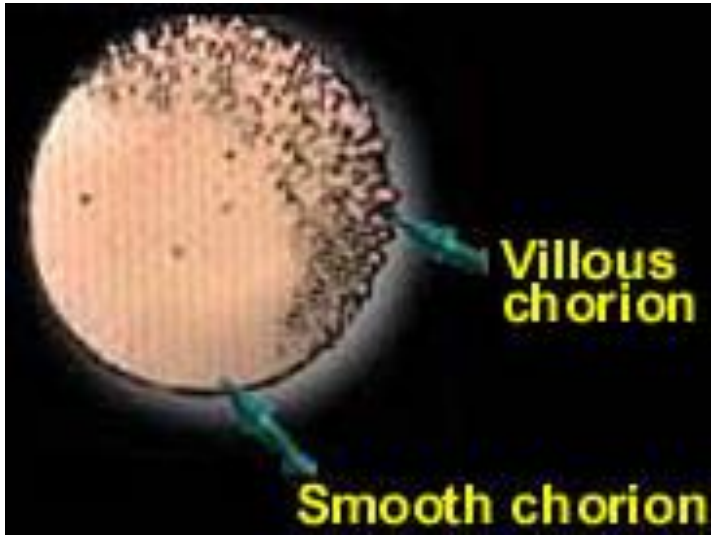

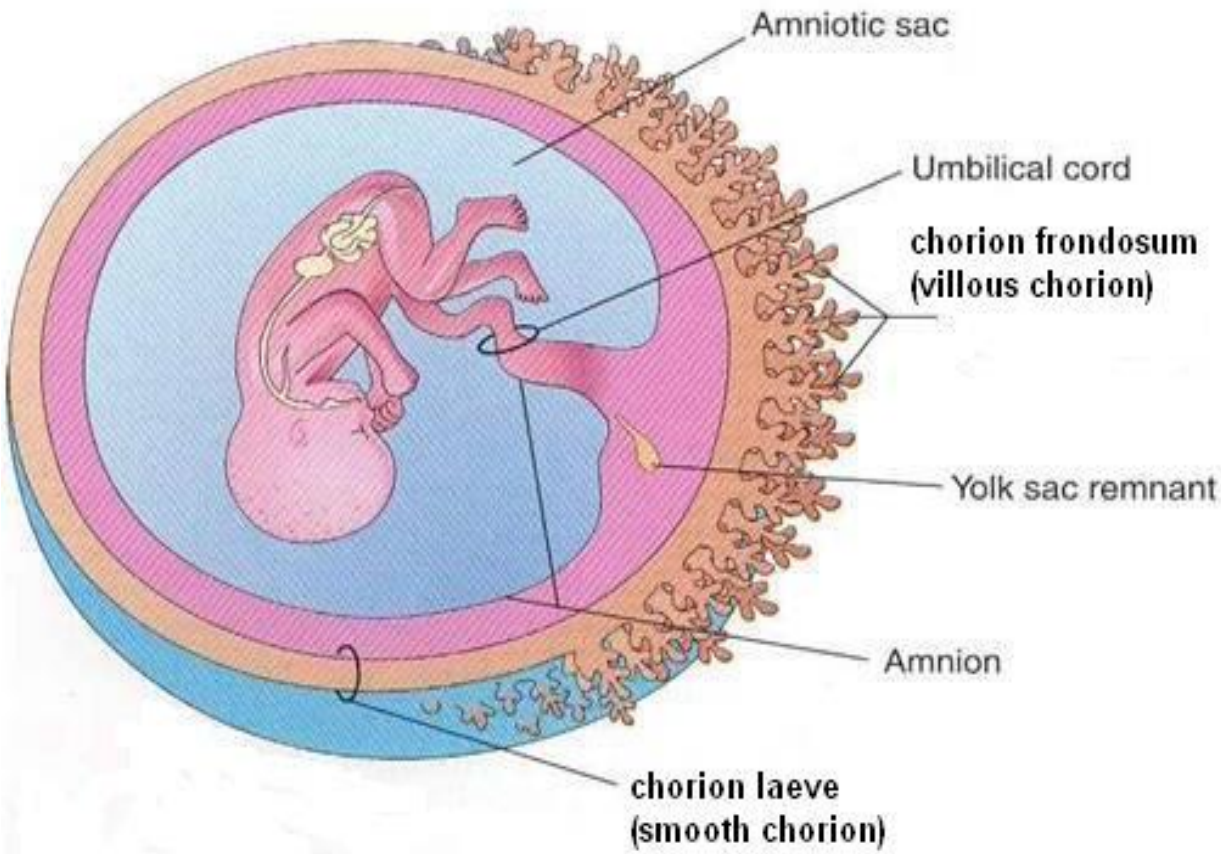
Amniotic sac
Umbilical cord
chorion frondosum
(villous chorion)
Yolk sac remnant
Amnion
chorion laeve
(smooth chorion)

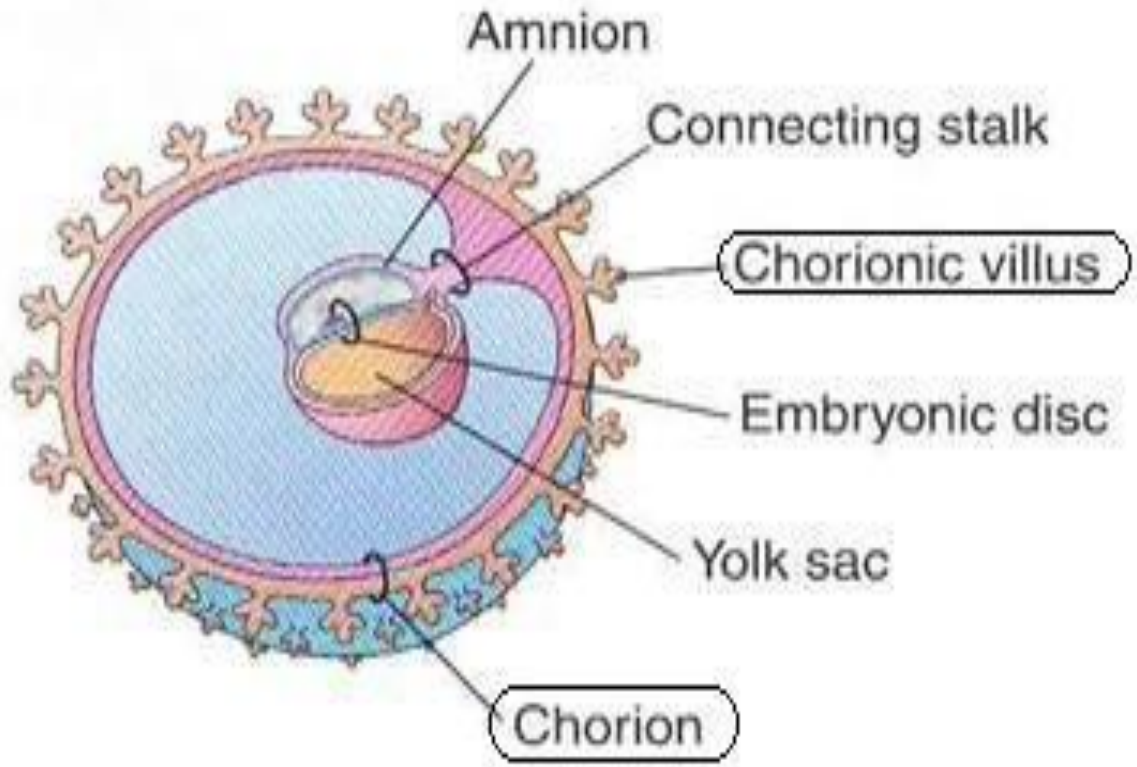
Amnion
Connecting stalk
Chorionic villus
Embryonic disc
Yolk sac
Chorion

# Yolk Sac

- At 32 days: a large structure
- 10 weeks: small, shrunk pear-shaped, lies in the chorionic cavity, connected to midgut by a narrow yolk stalk
- Atrophies as pregnancy advances and by 20 weeks: very small, and thereafter usually not visible
- Very rarely it persists as a small structure on the fetal surface of placenta, under the amnion, near the attachment of umbilical cord. Its persistence is of no significance

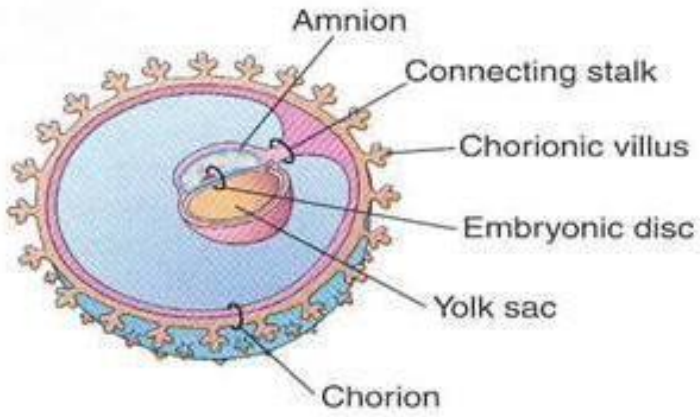
Amnion
Connecting stalk
Chorionic villus
Embryonic disc
Yolk sac
Chorion

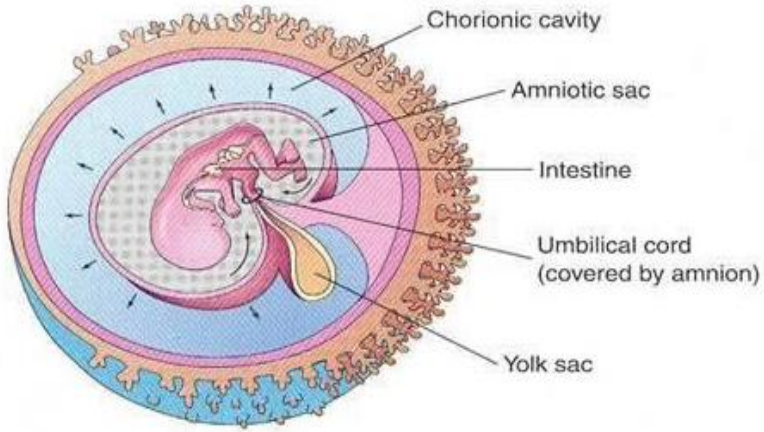
Chorionic cavity
Amniotic sac
Intestine
Umbilical cord
(covered by amnion)
Yolk sac

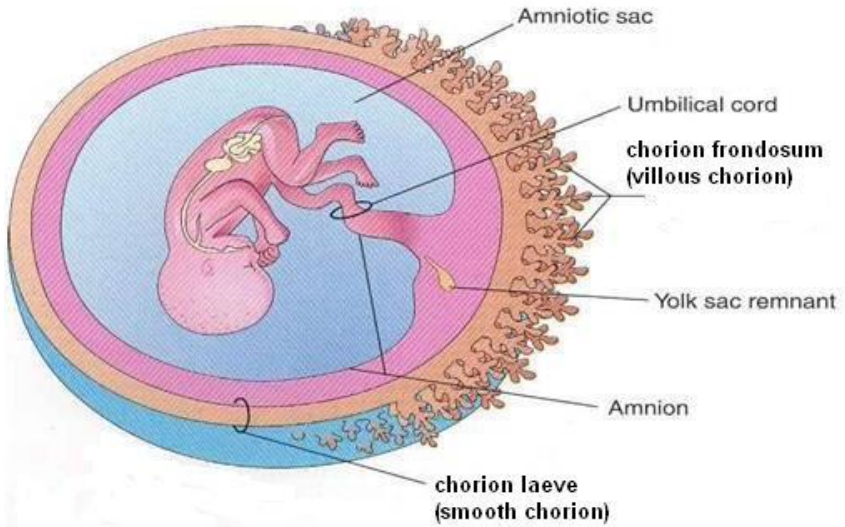
Amniotic sac
Umbilical cord
chorion frondosum
(villous chorion)
Yolk sac remnant
Amnion
chorion laeve
(smooth chorion)

# Yolk Sac

# Yolk Sac: Significance

- Source of nutrition for the embryo during 2-3 weeks
- Blood development first occurs in the mesodermal layer of the yolk sac (early 3$^{rd}$ week) and continues until hemopoietic activity begins in the liver (6$^{th}$ week)
- Primordial germ cells appear in the endodermal lining of the wall of the yolk sac (3$^{rd}$ week) and then migrate to the developing gonads
- Part of yolk sac is incorporated into the embryo as the primitive gut (4$^{th}$ week)

# Yolk Stalk (Vitelline Duct)

- A tubular connection between the midgut and the yolk sac.
- Initially wide, becomes narrow with the folding of the embryo
- Becomes one of the contents of the developing umbilical cord
- Attached to the tip of the midgut loop
- Usually detaches from midgut loop by the end of the $6^{th}$ week

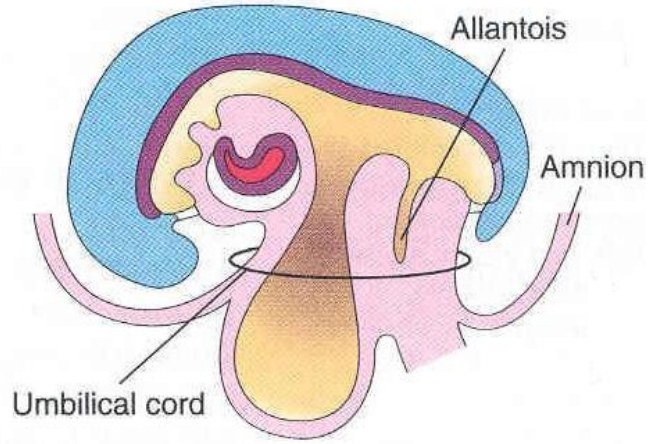
Allantois
Amnion
Umbilical cord

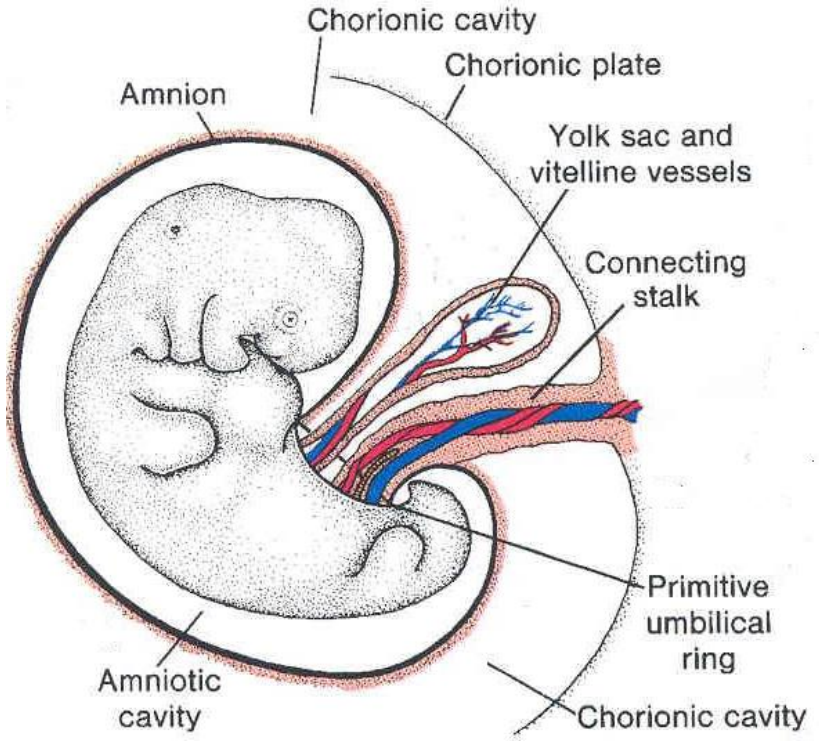
Chorionic cavity
Chorionic plate
Amnion
Yolk sac and vitelline vessels
Connecting stalk
Primitive umbilical ring
Amniotic cavity
Chorionic cavity

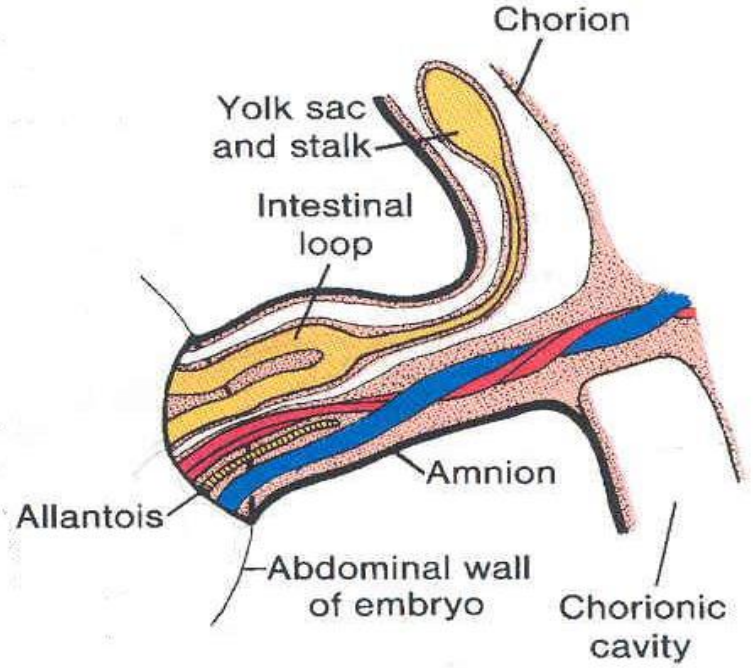
Chorion
Yolk sac and stalk
Intestinal loop
Amnion
Allantois
Abdominal wall of embryo
Chorionic cavity

- **Yolk Stalk**

# Allantois

- Appears in 3rd week as a diverticulum from the caudal wall of the yolk sac, that extends into the connecting stalk
- During folding of the embryo, a part of allantois is incorporated into the hindgut
- During 2nd month, the extra-embryonic part of allantois degenerates
- The intraembryonic part runs from the umbilicus to the urinary bladder. As bladder enlarges, this part involutes and changes to a thick tube called **urachus**
- After birth, urachus becomes a fibrous cord, **the median umbilical ligament**, that extends from the apex of the bladder to the umbilicus.
- **Allantois: Significance**
  - **Blood formation occurs in its walls during the 3rd week**
  - **Its blood vessels persist as umbilical vessels.**

- **Allantois**

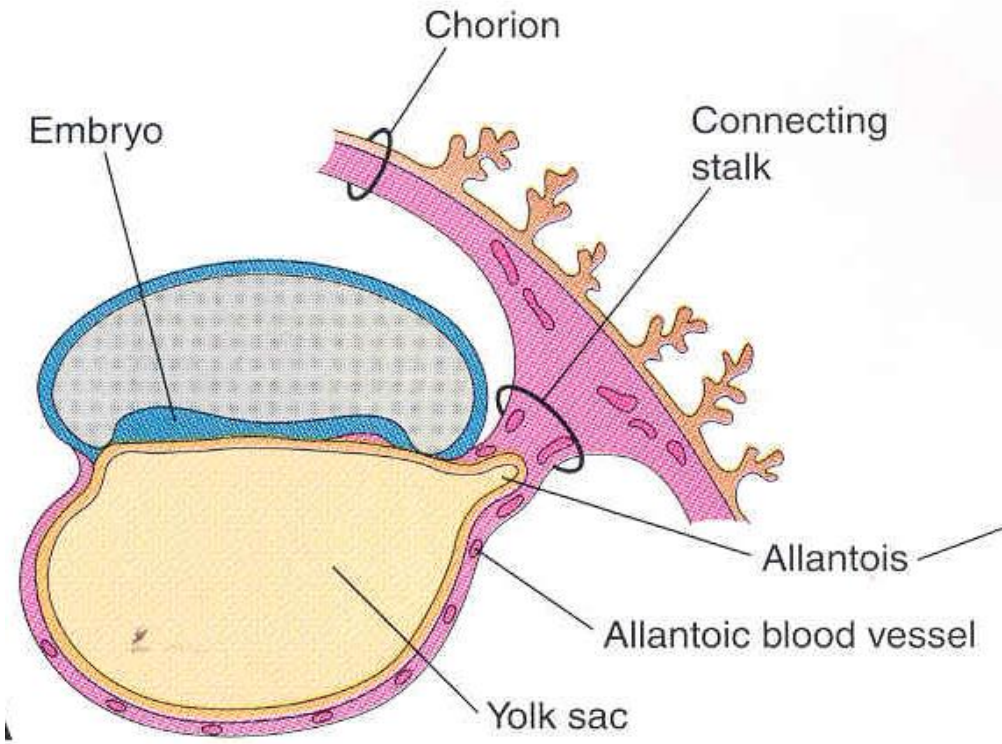
Chorion
Embryo
Connecting stalk
Allantois
Allantoic blood vessel
Yolk sac

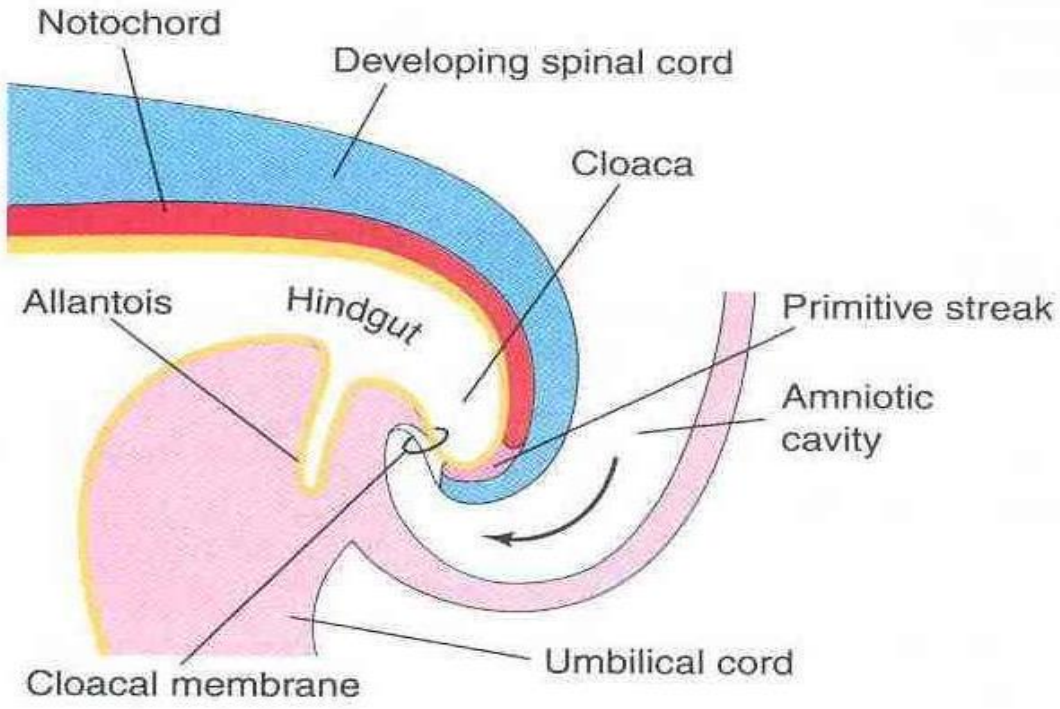
Notochord
Developing spinal cord
Cloaca
Allantois
Hindgut
Primitive streak
Amniotic cavity
Umbilical cord
Cloacal membrane

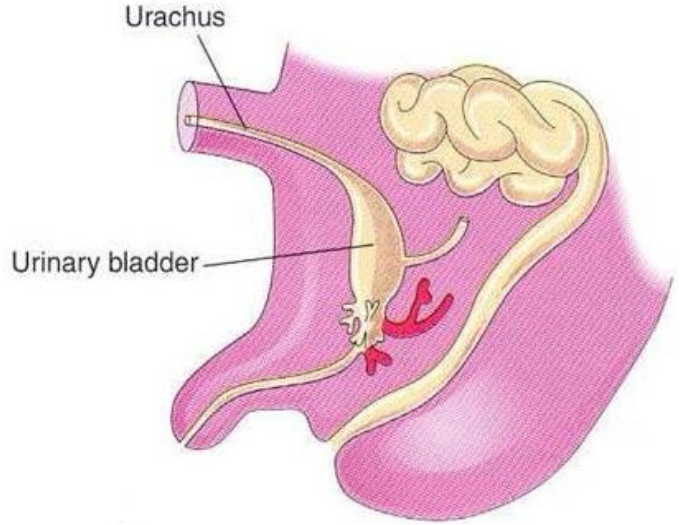
Urachus
Urinary bladder

# Umbilical Cord

- Cord like structure developing from the connecting stalk
- Connects fetus to the placenta
- Attached to the ventral surface of the fetal body and to the smooth chorionic plate of the placenta
- The connecting stalk initially attached to the caudal end of the embryonic disc, after folding, becomes attached to the ventral surface of the curved embryonic disc, at the umbilical region
- The umbilical region wider initially, becomes narrower as the folding progresses
- The underlying structures are compressed together and form a cord like structure, the umbilical cord



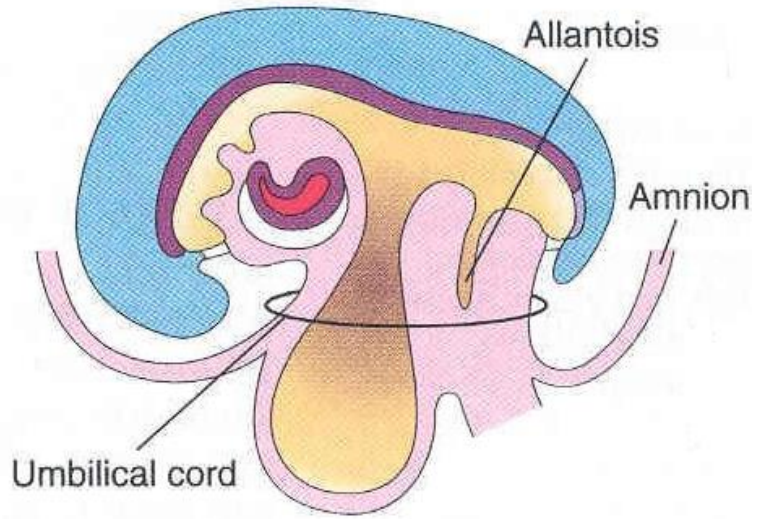

# Umbilical Cord: Formation cont'd

- **Initial contents:**
  - **Connecting stalk**
  - **Umbilical vessels**
  - **Allantois**
  - **Yolk sac**
  - **Extraembryonic celome**
  - **Intestinal loop (during 6-10 weeks)**

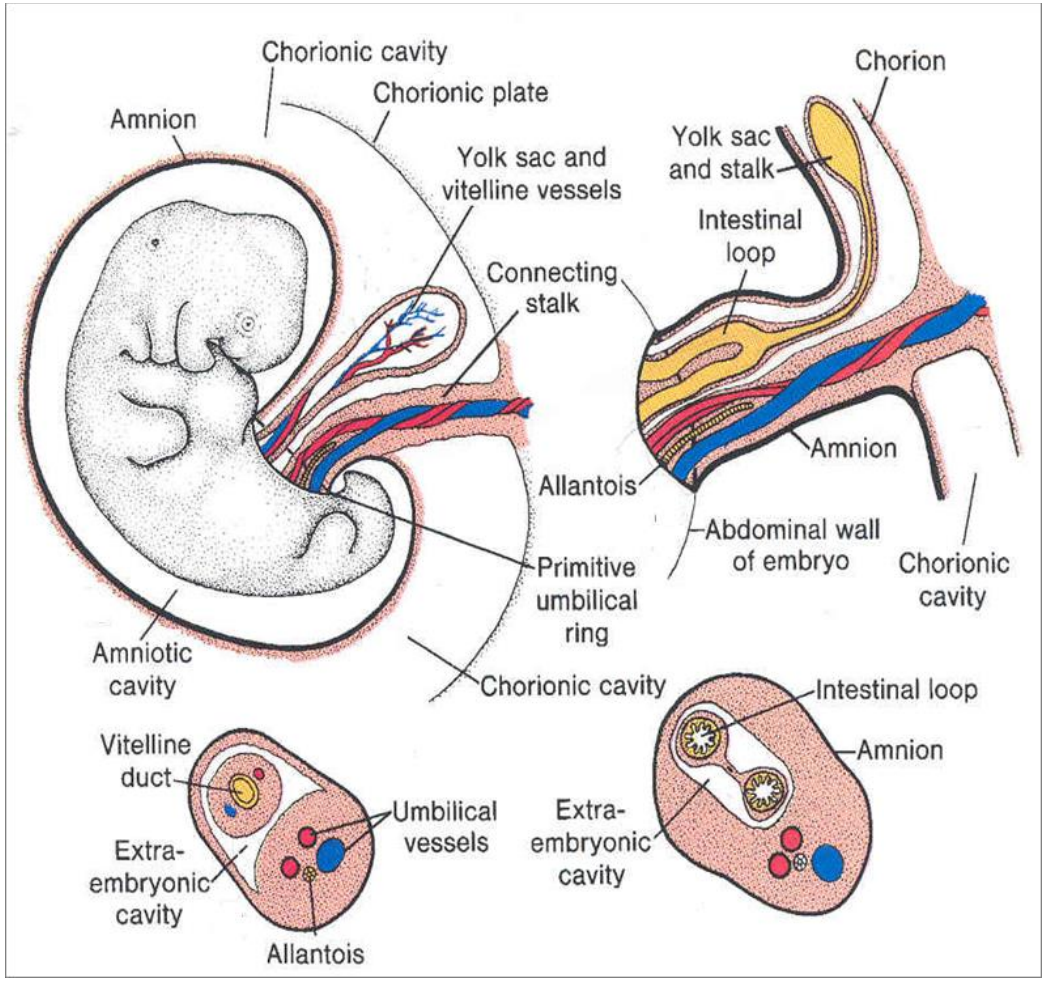

# Umbilical Cord: At Term

**At term, the typical umbilical cord:**

- **Is 55-60 cm in length, with a diameter of 2-2.5 cm**
- **Has knotty appearance**
- **Usually contains two arteries and one vein**
- **Is surrounded by a jelly like substance called the Wharton's jelly**
- **Is enclosed in amnion**

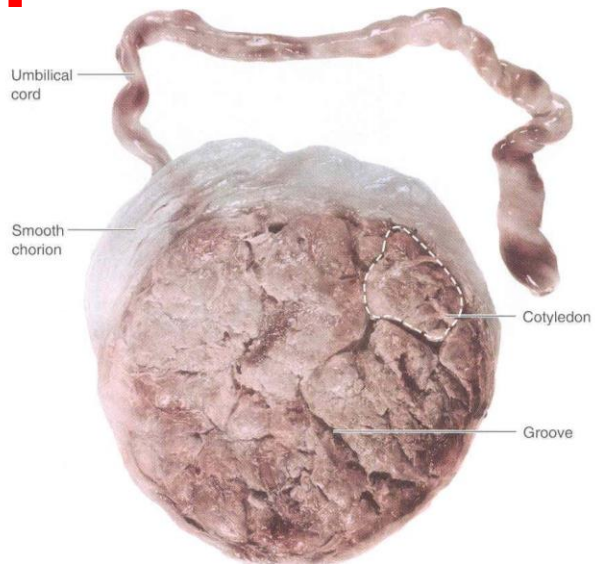


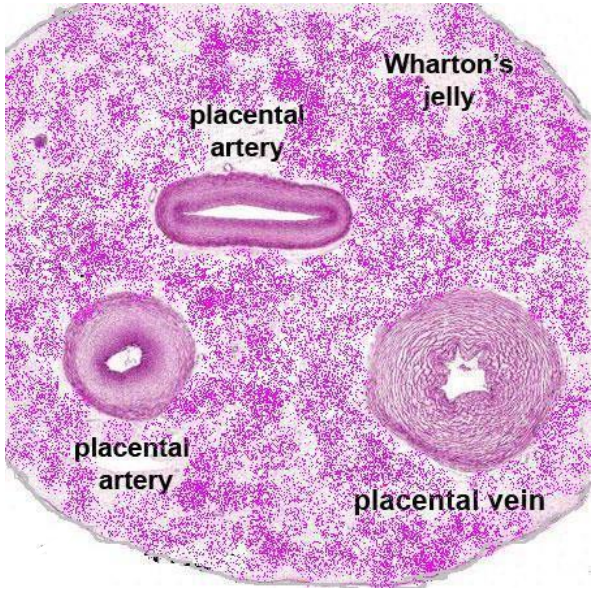

# Umbilical Cord: Placental Attachment

**Typically attaches to the placenta near its center- Eccentric attachment**

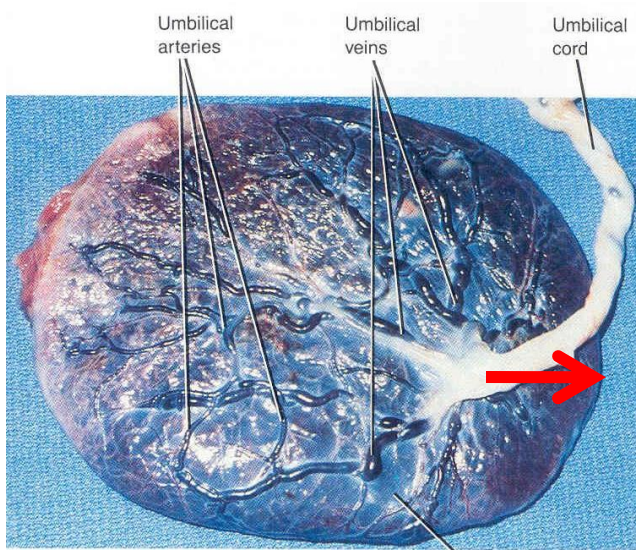


**May attach to the placenta near its margin- Marginal attachment**

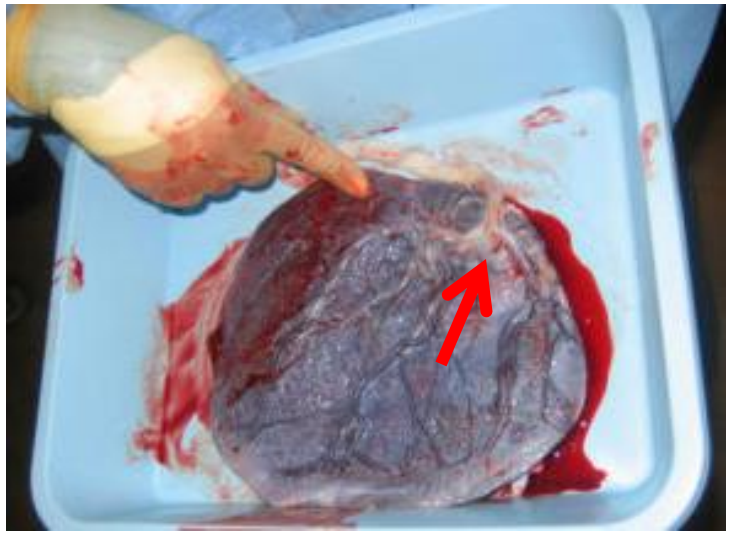

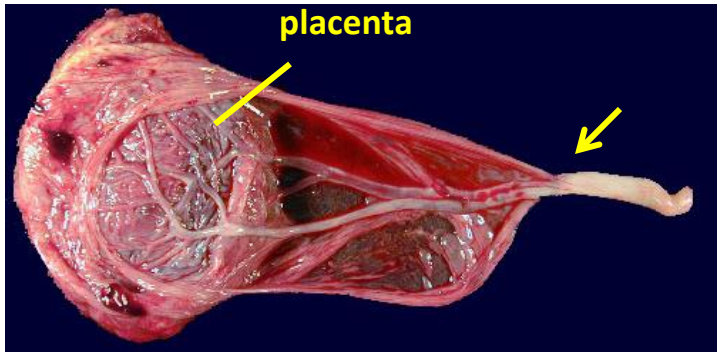


**May attach to the membranes around the placenta- Membranous (Velamentous ) attachment**

# Umbilical Cord cont'd

- After delivery of the placenta the umbilical cord is usually clamped and severed
- The site of its attachment leaves a scar, the navel (belly button), on the anterior wall of the abdomen



# The Placenta

## Changes in the trophoblast

- By the beginning of the second month, the **trophoblast** is characterized by a great number of secondary and tertiary villi
- As pregnancy advances, villi on the embryonic pole continue to grow and expand, giving rise to the **chorion frondosum**
- Villi on the abembryonic pole degenerate and by the third month this side of the chorion, now known as the **chorionic leave**

# The fetomaternal junction (junctional zone)

- The trophblast and decidual cells intermingle
- Between the chorionic and decidual plates are the intervellous spaces that filled with maternal blood
- The maternal blood reaches the intervellous spaces by ***spiral arteries***

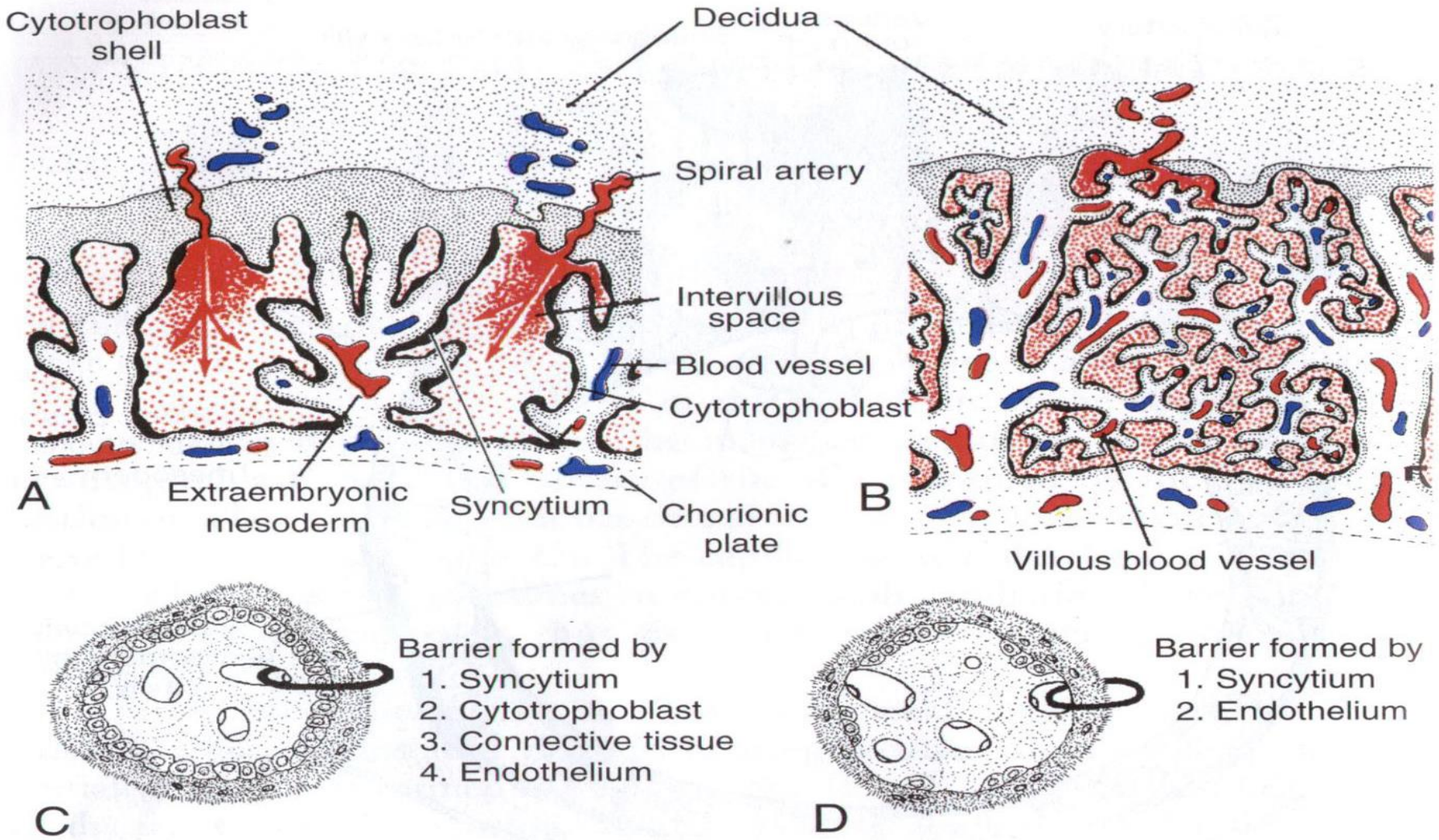


**Figure 7.2.** Structure of villi at various stages of development. **A.** During the fourth week. The extraembryonic mesoderm penetrates the stem villi in the direction of the decidual plate. **B.** During the fourth month. In many small villi the wall of the capillaries is in direct contact with the syncytium. **C** and **D.** Enlargement of the villus as shown in **A** and **B**, respectively.

# Structure of the placenta

By the beginning of the fourth month, the placenta has two components:

- Fetal portion formed by the **chorion frondosum**
- Maternal portion, formed by the **decidua basalis**
- placenta is bordered by the **chorionic plate** on its maternal side, it is bordered by the **decidua basalis**

- Functional layer of the endometrium is known as **decidua**
- The decidua over the chorion frondosum, the **decidua basalis**
- The decidual layer over the abembryonic pole is the **decidua capsularis**
- on the opposite side of the uterus is called **decidua parietalis**

- During the fourth and fifth months, the decidua forms a number of **decidual septa**, which project into intervillous spaces
- As a result of this septum formation, the placenta is divided into a number of compartments, or **cotyledons**

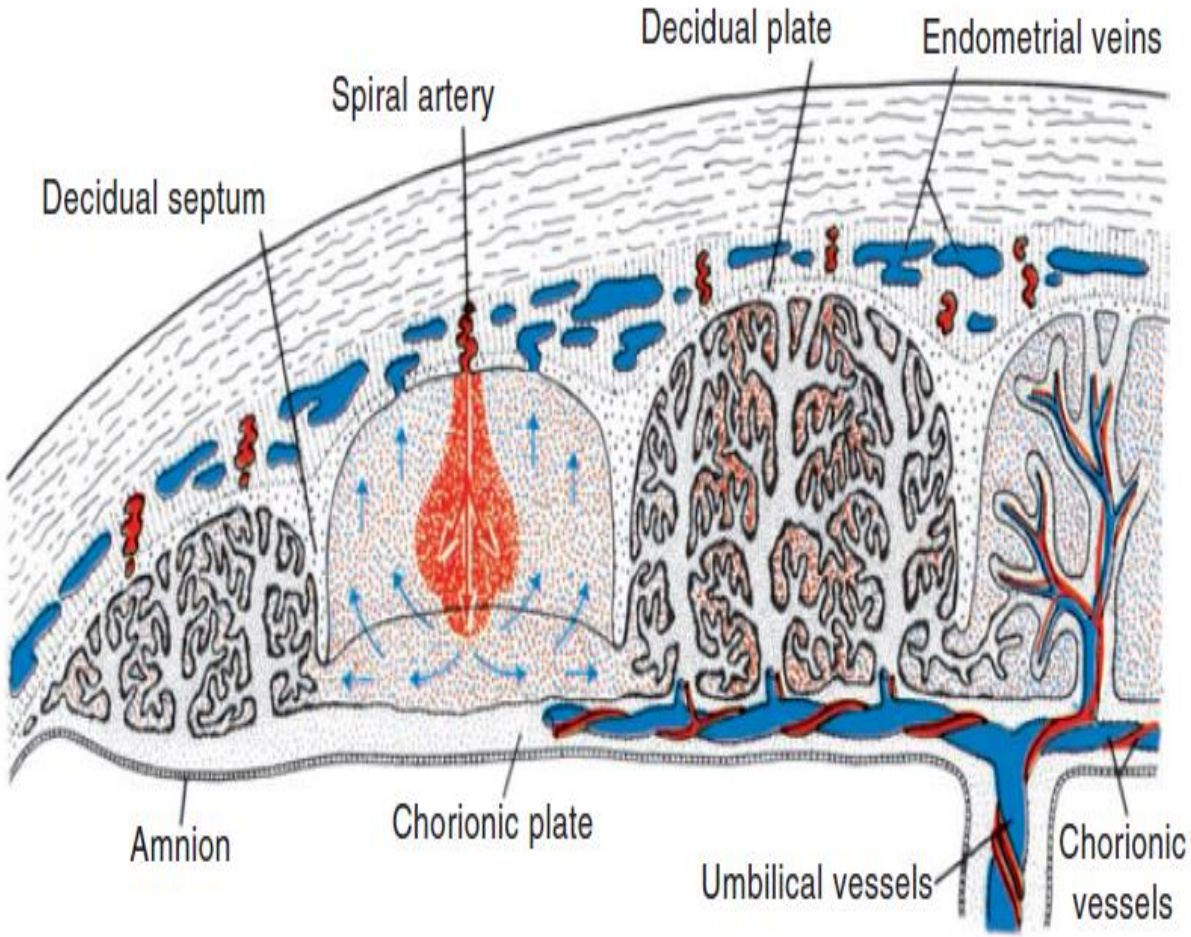
Decidual plate
Endometrial veins
Spiral artery
Decidual septum
Amnion
Chorionic plate
Umbilical vessels
Chorionic vessels

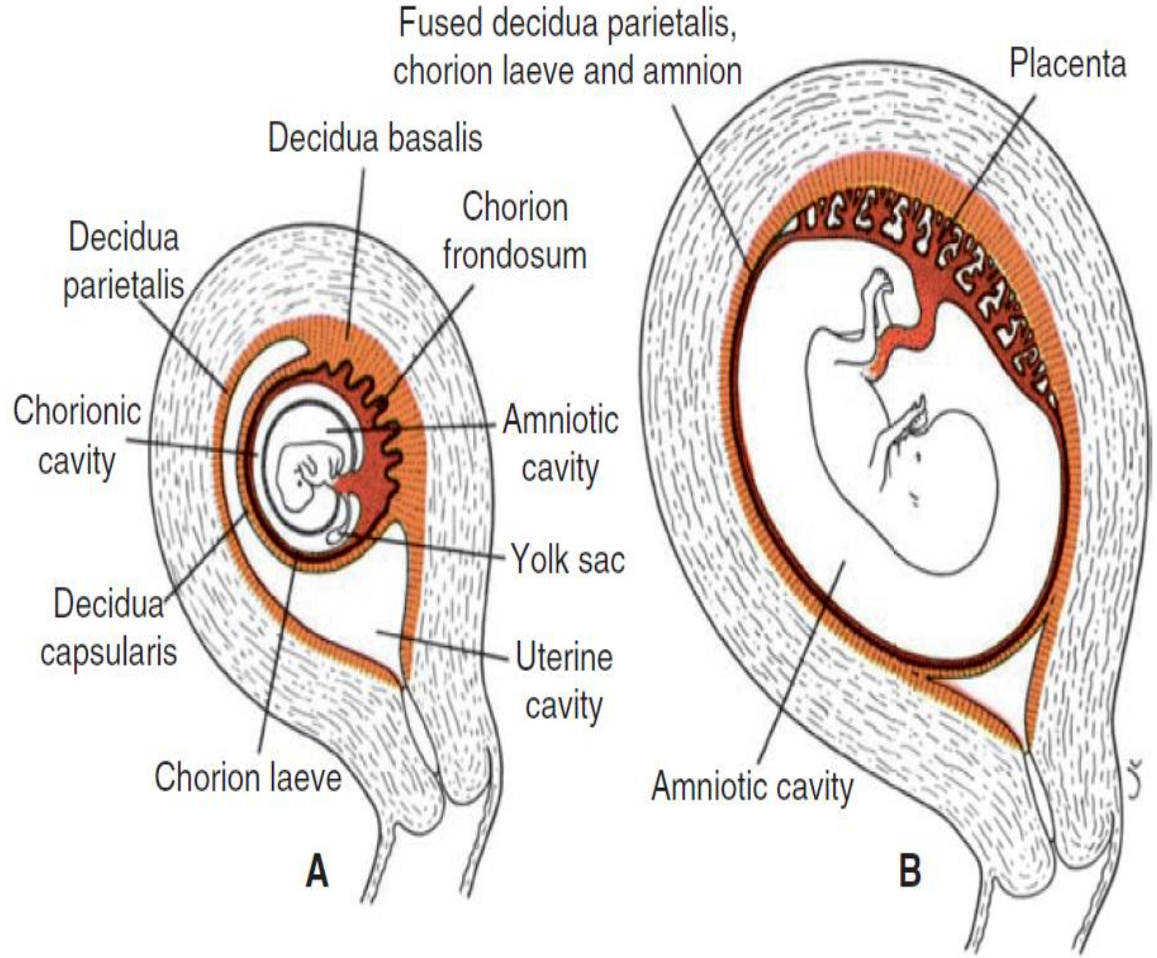
Fused decidua parietalis, chorion laeve and amnion
Placenta
Decidua basalis
Chorion frondosum
Decidua parietalis
Chorionic cavity
Amniotic cavity
Yolk sac
Decidua capsularis
Uterine cavity
Chorion laeve
A
Amniotic cavity
B

# Full-Term Placenta

- The placenta starts to form: Week 2
- Begins to function: Around End of Week 3
- Becomes fully functional and independent: By Week 12
- The placenta considered mature: 34 week
- At full term, the placenta is discoid with a diameter of **15 to 25 cm**
- It  is approximately **3 cm thick**
- It is weigh is about **500 to 600 g**
- At birth, it is torn from the uterine wall approximately 30 minutes after birth of the child

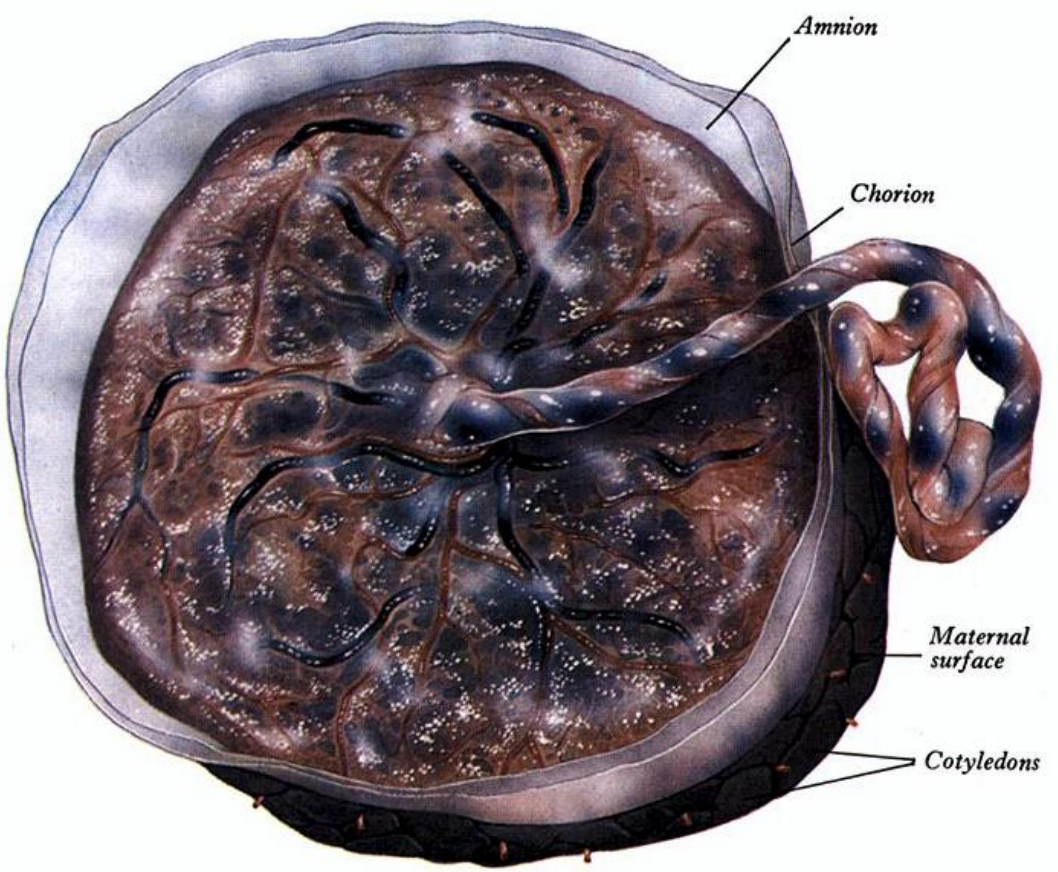
Amnion
Chorion
Maternal surface
Cotyledons

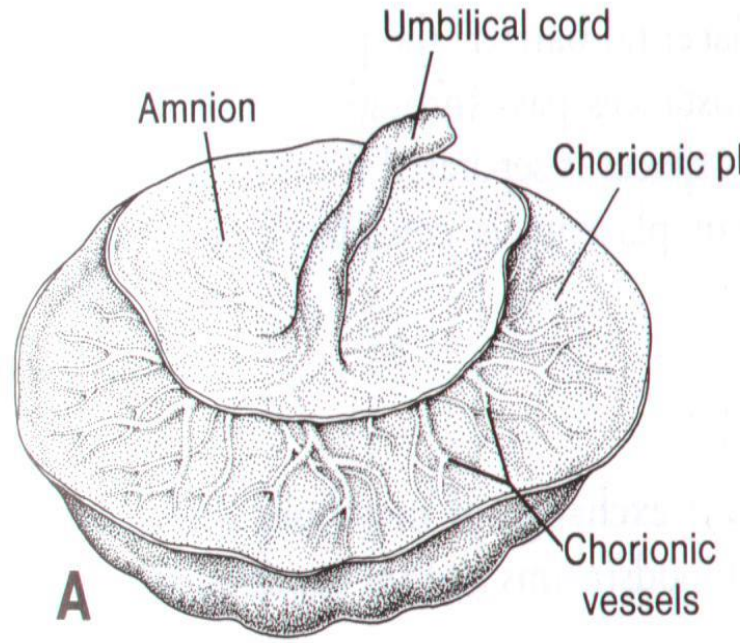
Umbilical cord
Amnion
Chorionic plate
Chorionic vessels
A

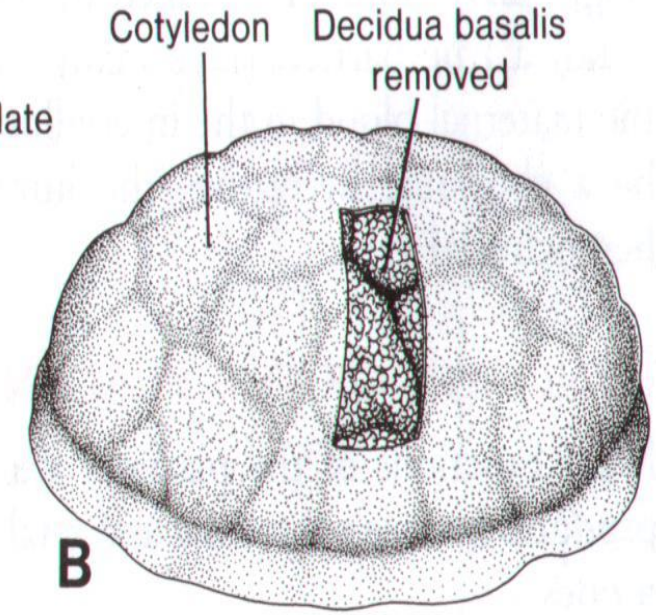
Cotyledon
Decidua basalis removed
B

# Circulation of the Placenta

- Placenta receive maternal blood through 80 to 100 **spiral arteries**
- **Oxygenated blood** inter the intervillous spaces
- **Deoxygenated blood** flows back toward the decidua, where it enters the **endometrial veins**
- Mature placenta contain approximately 150 mL of blood
- Blood of intervillous spaces change 3 to 4 times every minute

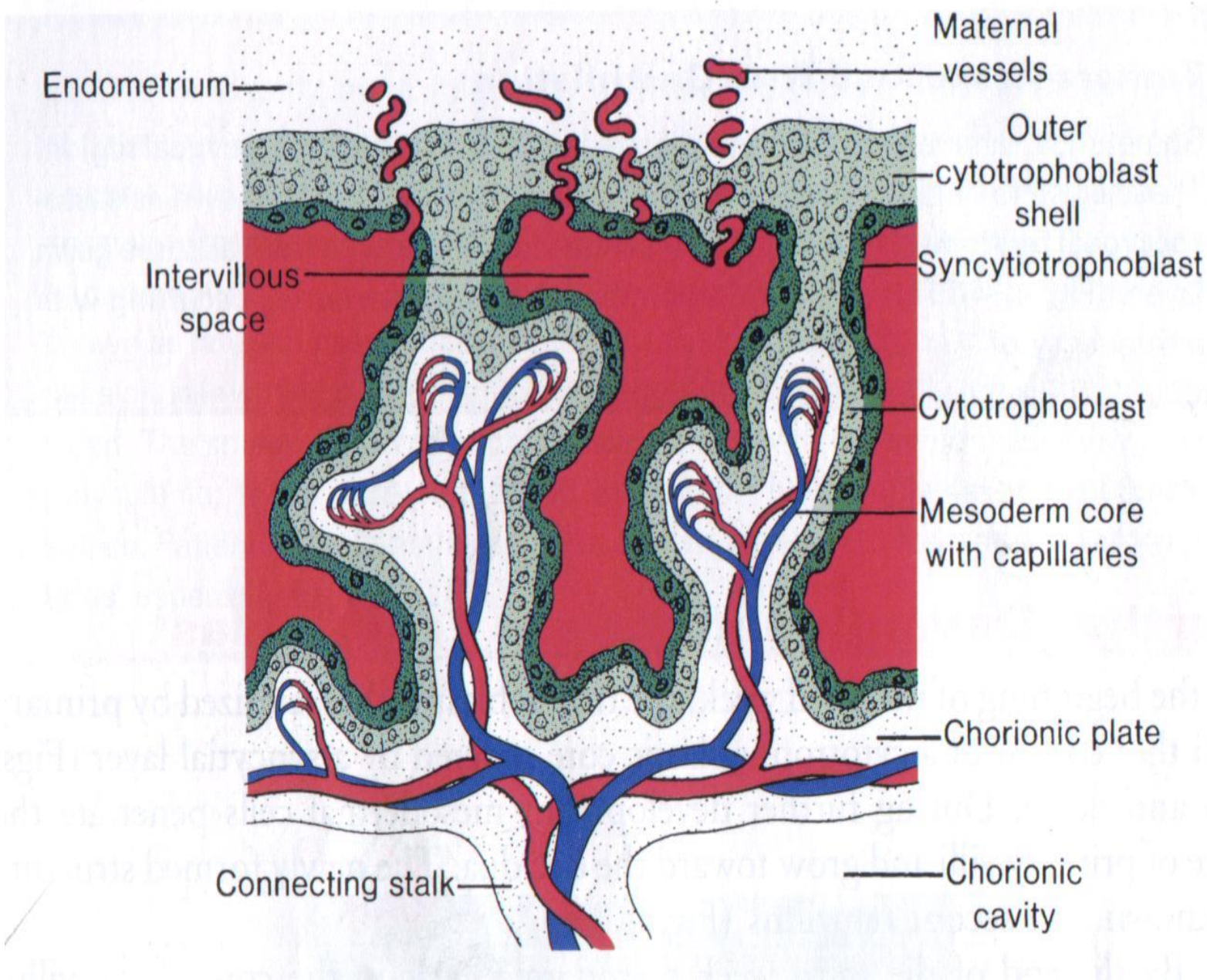
Maternal vessels
Endometrium
Outer cytotrophoblast shell
Intervillous space
Syncytiotrophoblast
Cytotrophoblast
Mesoderm core with capillaries
Chorionic plate
Connecting stalk
Chorionic cavity

# Placental membrane (barrier)

- Initially it consists of four layers
- Syncytium, cytotrophoblast, connective tissue and endothelium of the fetal capillaries
- From the 4th month become formed from two layers
- Syncytium and endothelium of the fetal capillaries

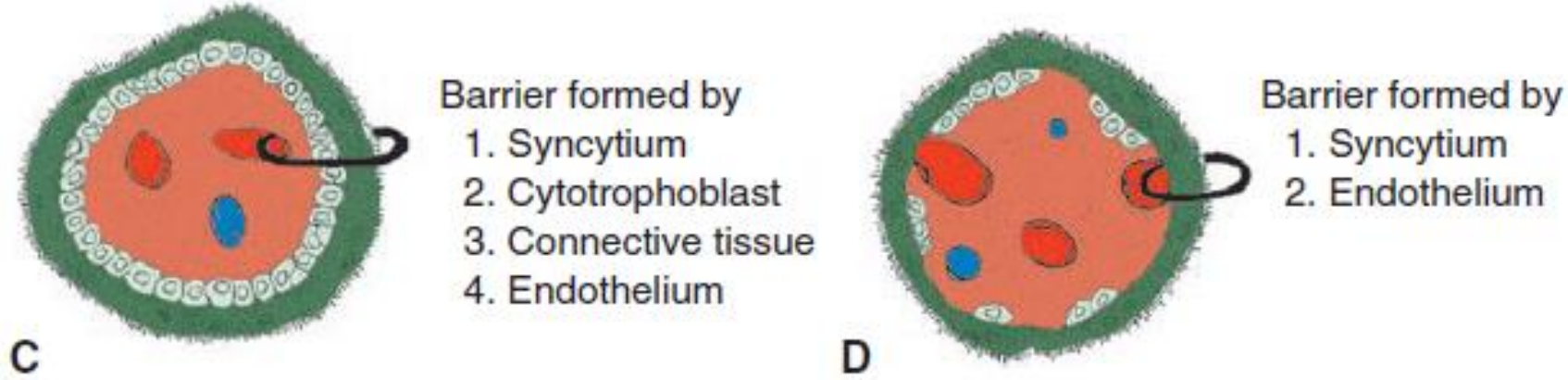

# Functions of the placenta:

- Transfer gasses
- Transport nutrients
- Excretion of wastes
- Hormone production – temporary endocrine organ – estrogen and progesterone
- Formation of a barrier – incomplete, nonselective – alcohol, steroids, narcotics, anesthetics, some antibiotics and some organisms can cross

## Fetal Membranes in Twins

Arrangement of fetal membranes in twins varies considerably, depending on the type of twins and on the time of separation in monozygotic twins.

Types of twins:

### 1- DIZYGOTIC TWINS

Approximately two-thirds of twins are **dizygotic (fraternal).**
They result from simultaneous shedding of two oocytes and fertilization by different spermatozoa.
Since the two zygotes have totally different genetic constitutions, the twins have no more resemblance than any other brothers or sisters. They may or may not be of different sex.

The zygotes implant individually in the uterus, and usually each develops its own placenta, amnion, and chorionic sac.

**Sometimes,** however, the two placentas are so close together that they fuse.

Similarly, the walls of the chorionic sacs may also come into close apposition and fuse.

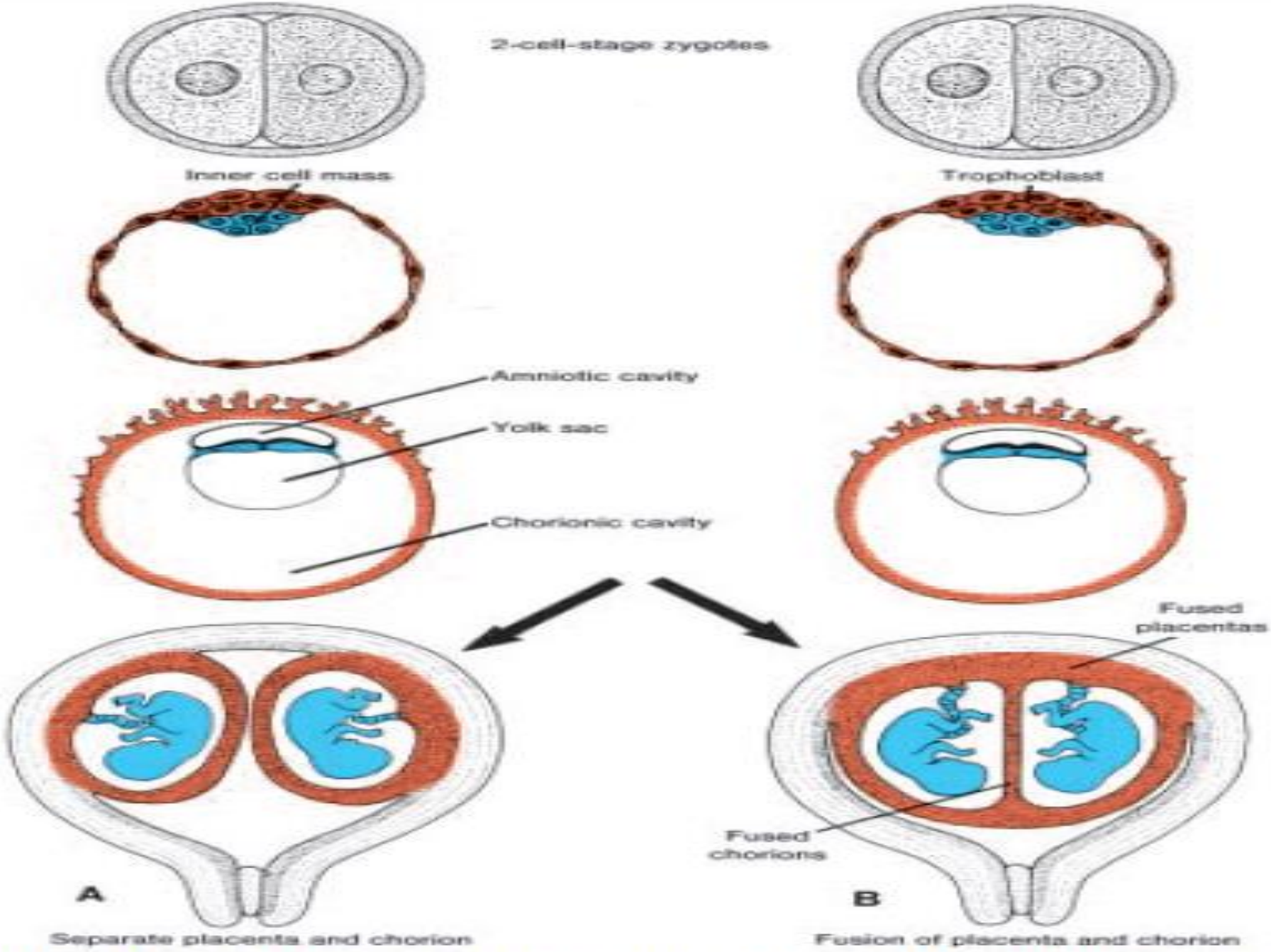


**Figure 6.17** Development of dizygotic twins. Normally each embryo has its own amnion, chorion, and placenta, **A**, but sometimes the placentas are fused, **B**. Each embryo usually receives the appropriate amount of blood, but on occasion large anastomoses

## 2- MONOZYGOTIC TWINS

The second type of twins, which develops from a single fertilized ovum, is **monozygotic (identical) twins.**
They result from splitting of the zygote at various stages of development. The earliest separation is believed to occur at the two-cell stage, in which case two separate zygotes develop. The blastocysts implant separately, and each embryo has its own placenta and chorionic sac. Although the arrangement of the membranes of these twins resembles that of dizygotic twins, the two can be recognized as partners of a monozygotic pair by their strong resemblance in blood groups, fingerprints, sex, and external appearance, such as eye and hair color.

The two embryos have **a common placenta** and a common chorionic cavity, but separate amniotic cavities (monochorionic, diamniotic).

In **rare** cases the separation occurs at the bilaminar germ disc stage, just before the appearance of the primitive streak.
This method of splitting results in formation of two partners with a common placenta and a common chorionic and amniotic sac (monochorionic, monoamniotic)..

Although the twins have a common placenta, blood supply is usually well balanced.
Although triplets are rare birth of quadruplets and so forth is rarer. In recent years multiple births have occurred more frequently in mothers given gonadotropins (fertility drugs) for ovulatory failure.

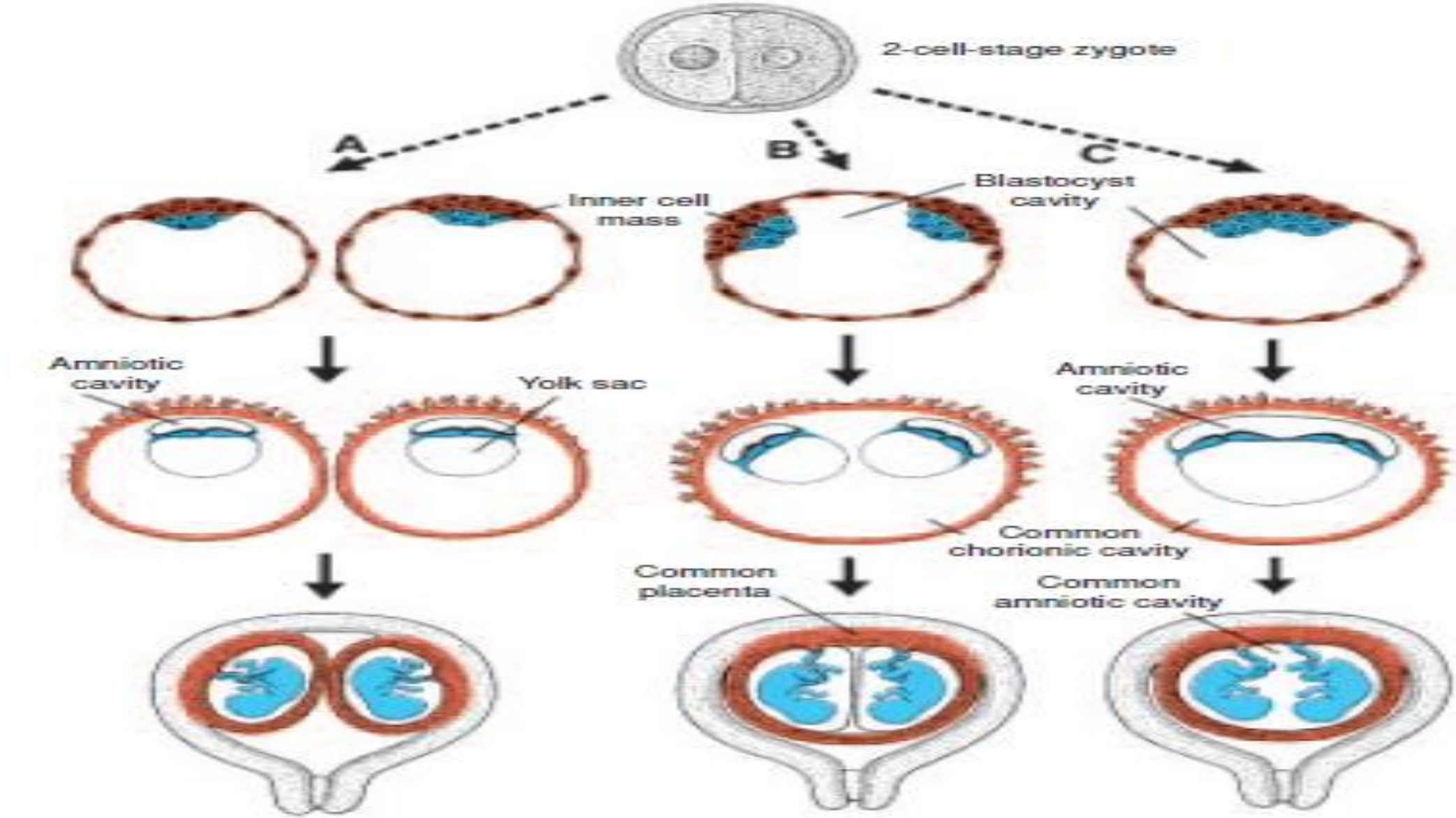


**Figure 6.18** Possible relations of fetal membranes in monozygotic twins. **A.** Splitting occurs at the two-cell stage, and each embryo has its own placenta, amniotic cavity, and chorionic cavity. **B.** Splitting of the inner cell mass into two completely separated groups. The two embryos have a common placenta and a common chorionic sac but separate amniotic cavities. **C.** Splitting of the inner cell mass at a late stage of development. The embryos have a common placenta, a common amniotic cavity, and a common chorionic cavity.

# Thank You