Histology of Muscle

Body tissues

- Epithelial tissue
- Connective tissue
- **Muscular tissue**
- Nervous tissue

Unique characteristics of M. tissue:

- Excitability: is equal to responsiveness.
- Contractility: causes the fiber to shorten resulting in a pull on bones or the movement of specific body part.
- Elasticity: is the muscle's ability to return to its original length when tension is released.
- Extensibility: is capability of extending in length in response to the contraction of the opposing M fiber.

Terminology & keywords

- **Sarcoplasm** replaces the term cytoplasm.
- **Sarcoplasmic reticulum** instead of smooth E.R.
- **Sarcomere** is the repetitive sub-function unit of the contraction apparatus.
- **Myocytes** are the muscle cells containing the myofibrils, nucleus, mitochondria , etc…
- **Myofibrils** are the long cylindrical filament bundles found in the myocyte.

Terminology & keywords

- **Sarcolemma** is the muscle cell membrane.
- The **sarcolemma** has tubular infoldings called transverse or **T-tubules.**
- Adjacent to each T-tubule are expanded **terminal cisternae** of the sarcoplasmic R.
- The **T- tubules** and the **terminal cisternae** called the **triad**.
- This triad carry the depolarization from the **sarcolemma** to the reticulum deep to the **sarcomere**.

- **Myofilaments**: are proteins organized into thin and thick filaments (actin , myosin).

1. **Actin:**

G-actin is a globular form.

F-actin is the polymer forming thin microfilaments.

2. **Myosin**: motor proteins consist of sequence of amino acids, it moves along actin filaments while hydrolyzing ATP. It has head, neck and tail forming the thick filaments.

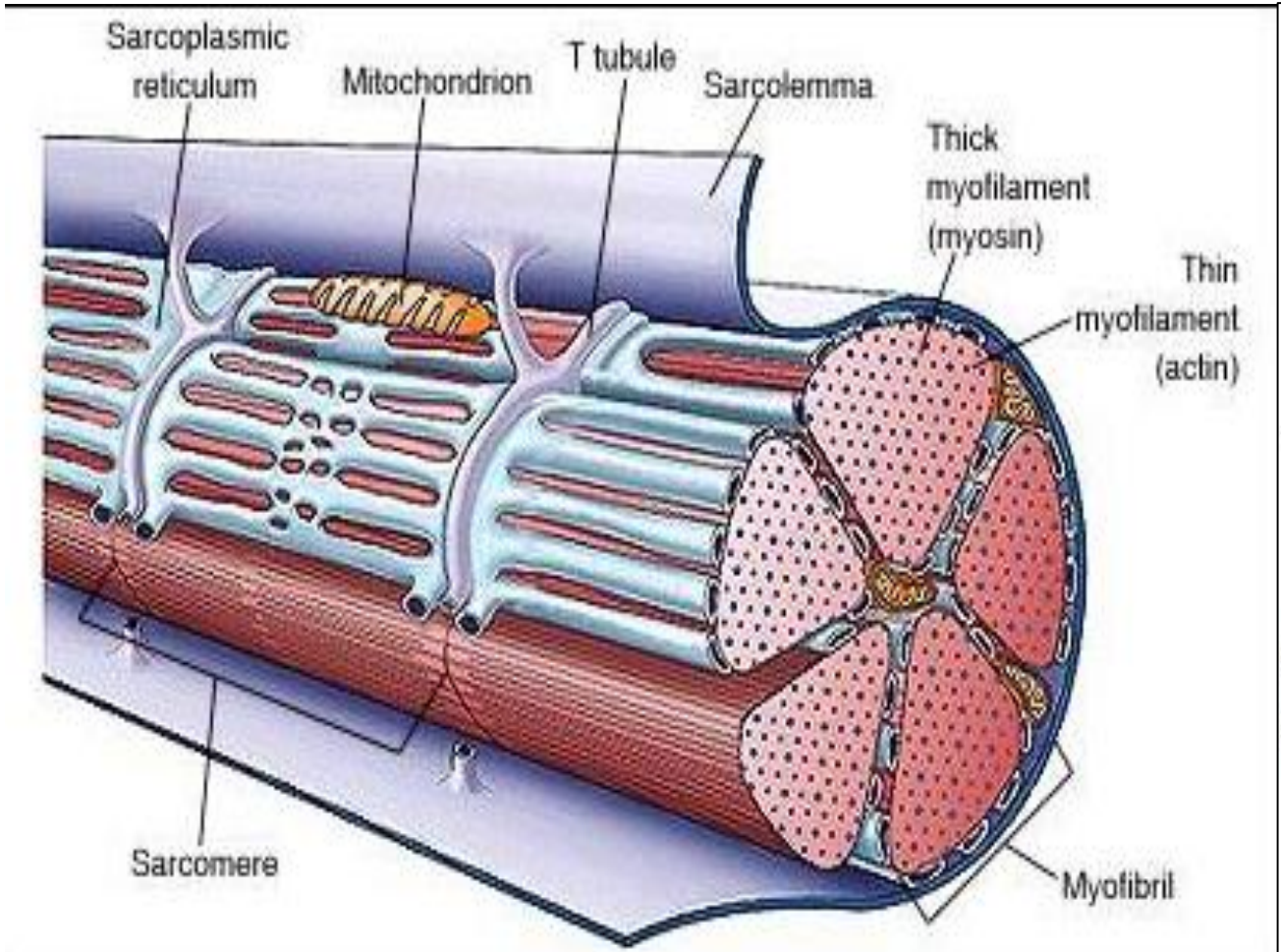
Sarcoplasmic reticulum
Mitochondrion
T tubule
Sarcolemma
Thick myofilament (myosin)
Thin myofilament (actin)
Sarcomere
Myofibril

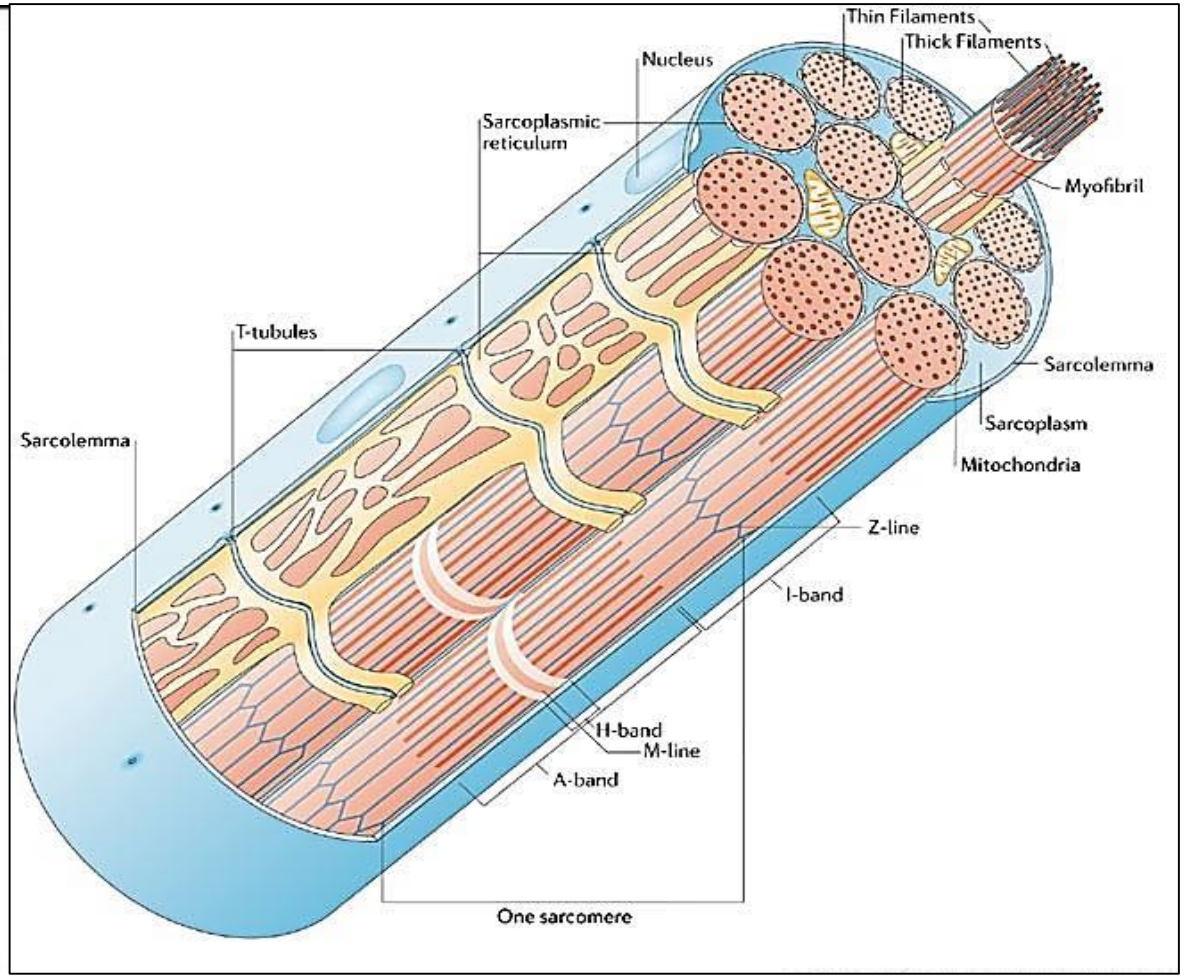
Thin Filaments
Thick Filaments
Nucleus
Sarcoplasmic reticulum
Myofibril
T-tubules
Sarcolemma
Sarcolemma
Sarcoplasm
Mitochondria
Z-line
I-band
H-band
M-line
A-band
One sarcomere

Myocyte

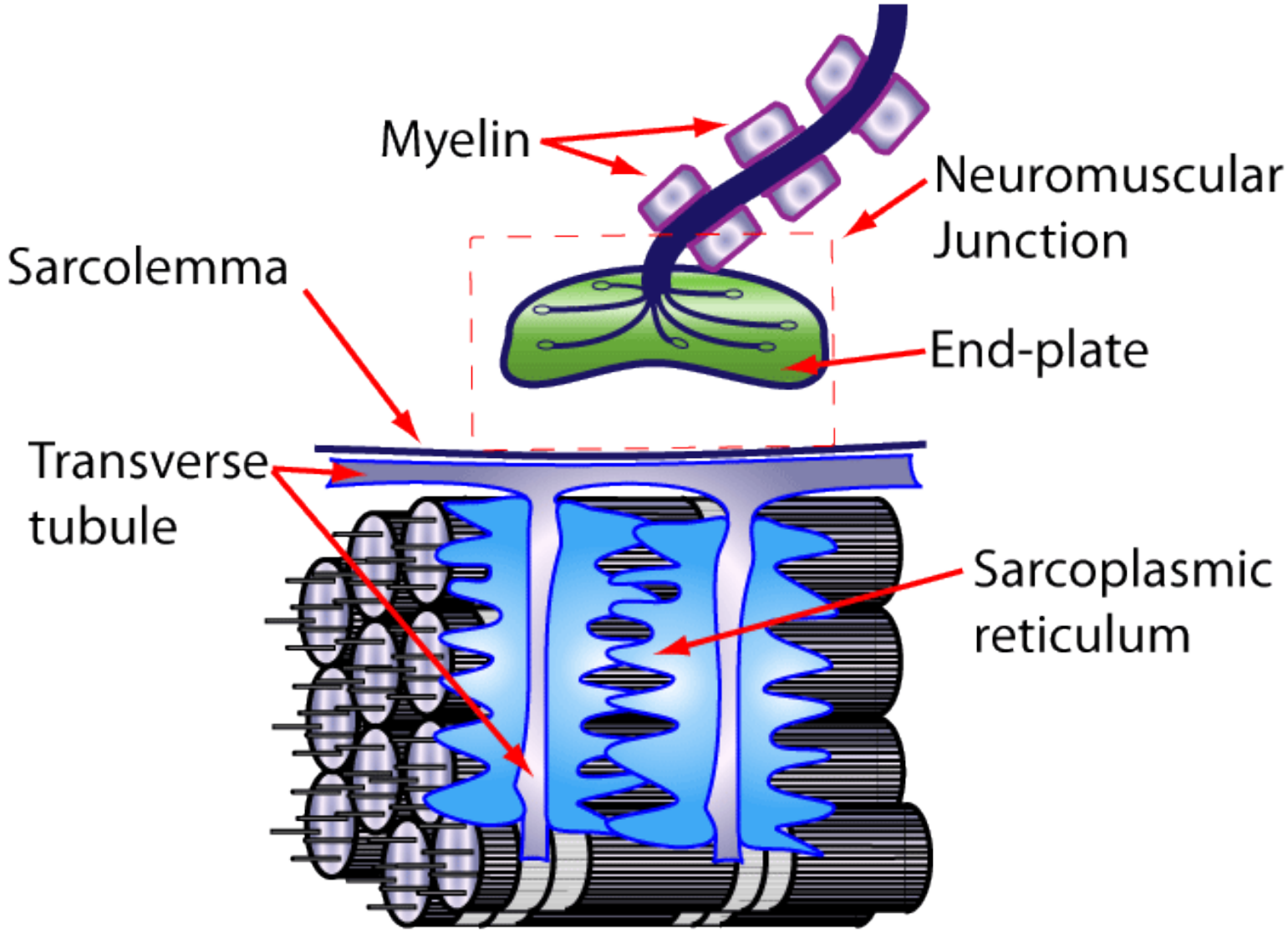

The neuromuscular junction

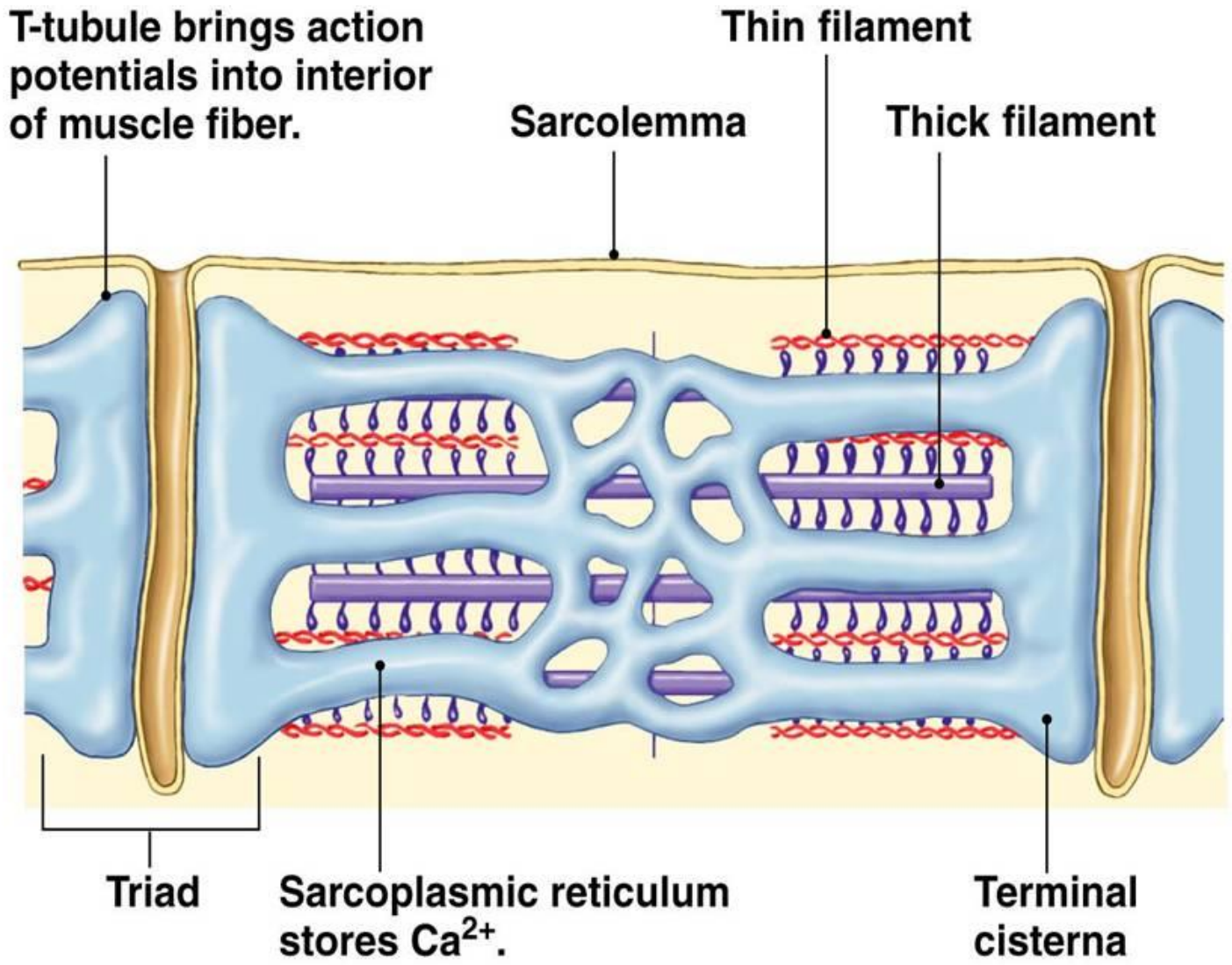

Structure of T tubules

Types of muscles

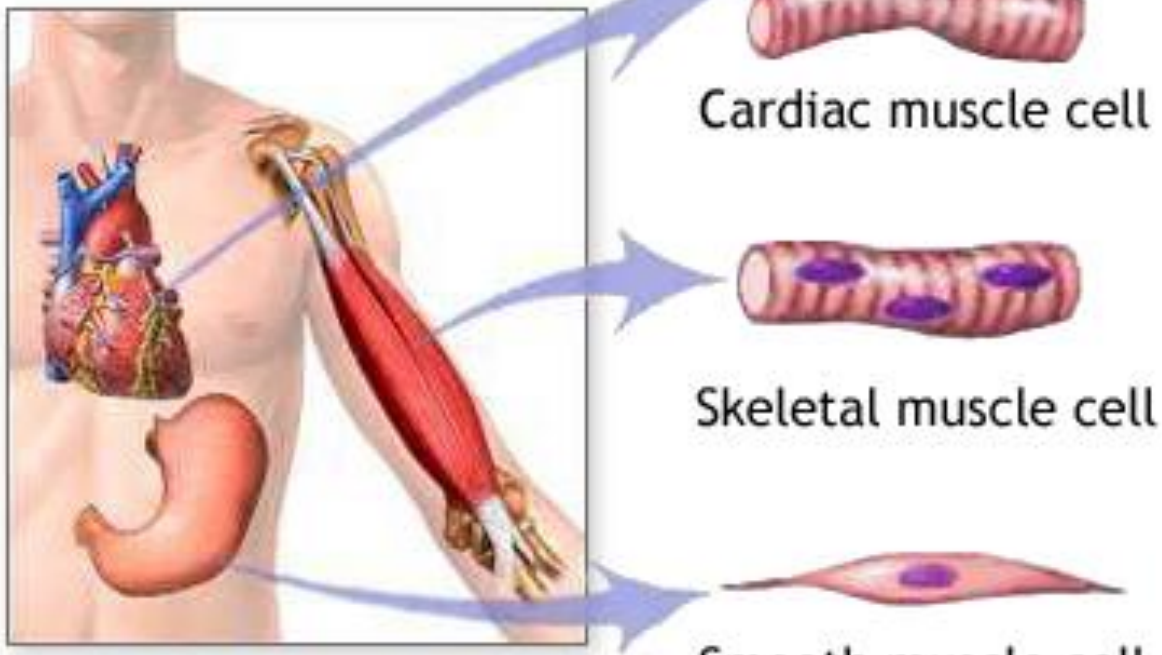

Cardiac muscle cell

Skeletal muscle cell

Smooth muscle cell

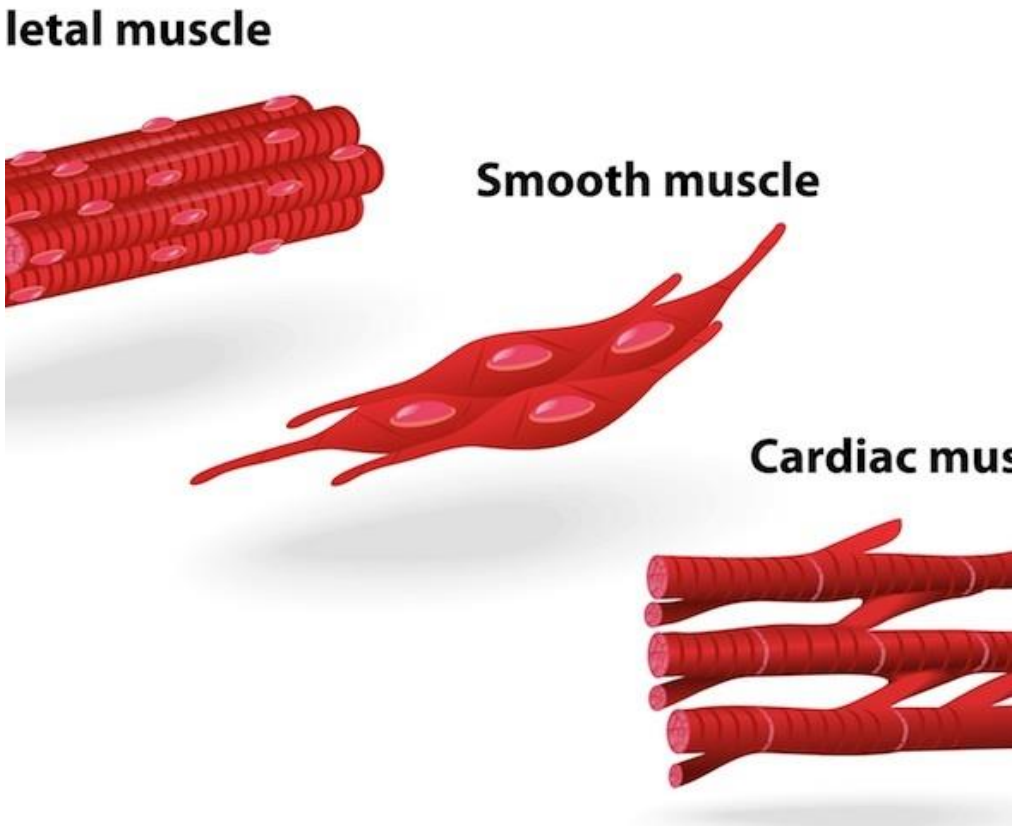

Skeletal muscles

- Contain very long **bundles** that run **longitudinally** (myofibrils).
- The cells are **multi-nucleated.**
- It has **cross striations**.
- **Forceful** quick contraction.
- Under **voluntary** control.

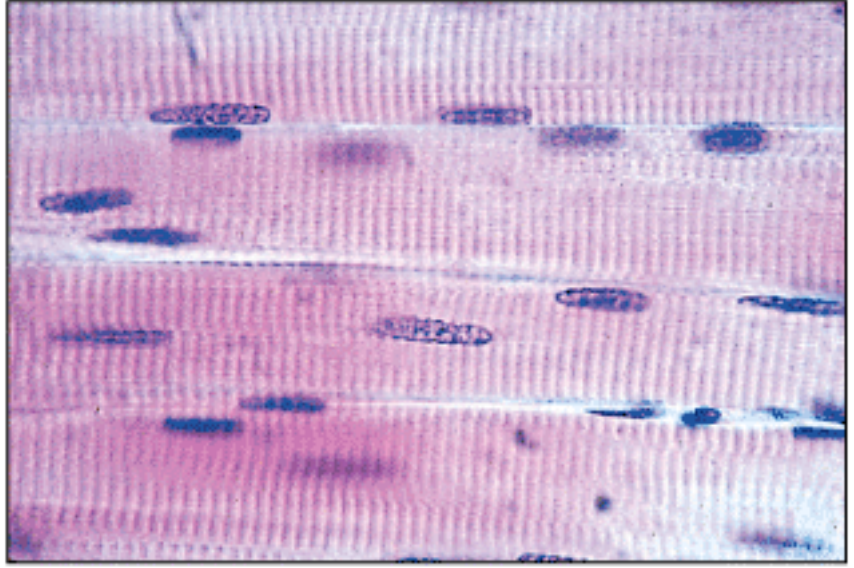

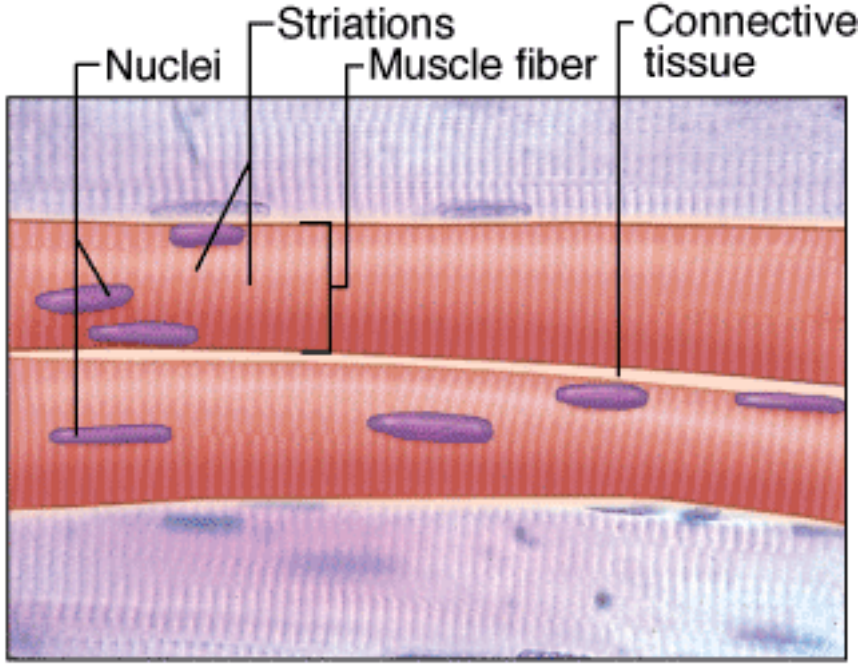

a Skeletal muscle

Organization of the Skeletal M.

There are 3 layers of C.T organizing the contractile fibers in all types of muscles:

1. **Epimysium:** External sheath of dense irregular C.T that surrounds the entire muscle. Septa from these tissues extend inwards carrying blood vessels, large nerves and lymphatics
2. **Perimysium:** Thin C.T that immediately surround each bundle of muscle fibers (fascicle). Each fascicle of muscle fibers works together as a functional unit. Nerves, blood vessels and lymphatics penetrate the perimysium to supply the fascicle.
3. **Endomysium:** Very thin delicate layer of reticular fibers lie within the fascicles. It surrounds the external lamina of each muscle fiber. Nerve fibers and capillaries form a network bringing O2 to the muscle.

Collagen in the three C.T layers is able to transmit the mechanical force generated by the contracting fibers.

All the three layers plus the **deep fascia** are continuous with the tendon at **myo-tendinous junction.**

This **myo-tendinous** join the muscles to the bone, skin or another muscle.

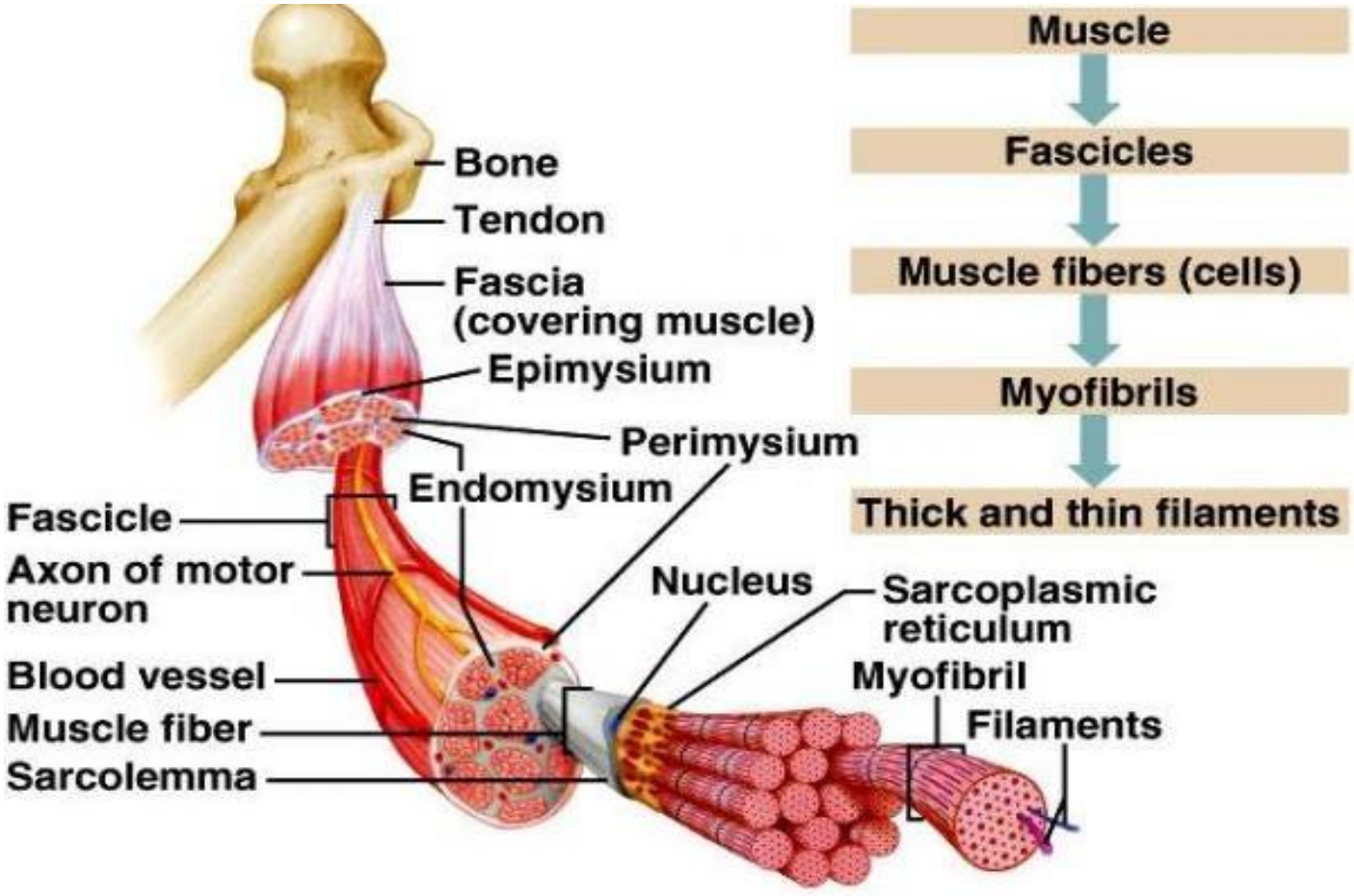

Organization within the M. fibers

- The **sarcoplasm** contain myofibrils that run parallel to the long axis of the fiber.
- Each fibril is showing alternating **light** and **dark** bands.
- The dark is the **A-band** while the light one is the **I-band**.
- Each A-band is bisected by the **M-line.**
- Each I-band is bisected by a dark transverse line the **Z-disc**.

- **Sarcomere** is the repetitive functional subunit of the myofibril.
- It extends between the two **Z- discs**.
- The **A** and **I** banding pattern in sarcomeres is due to the thick and thin filaments of the **myosin** and **actin**.

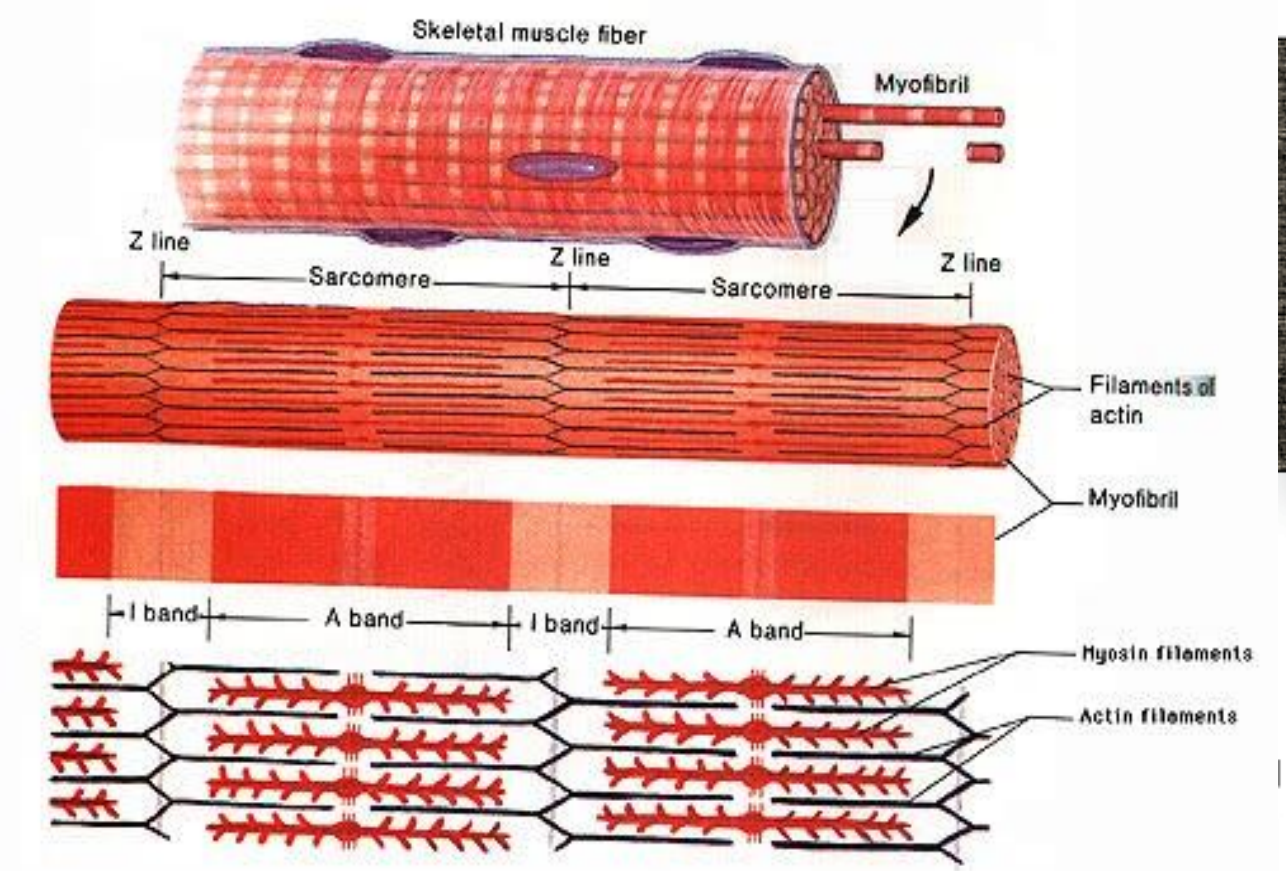

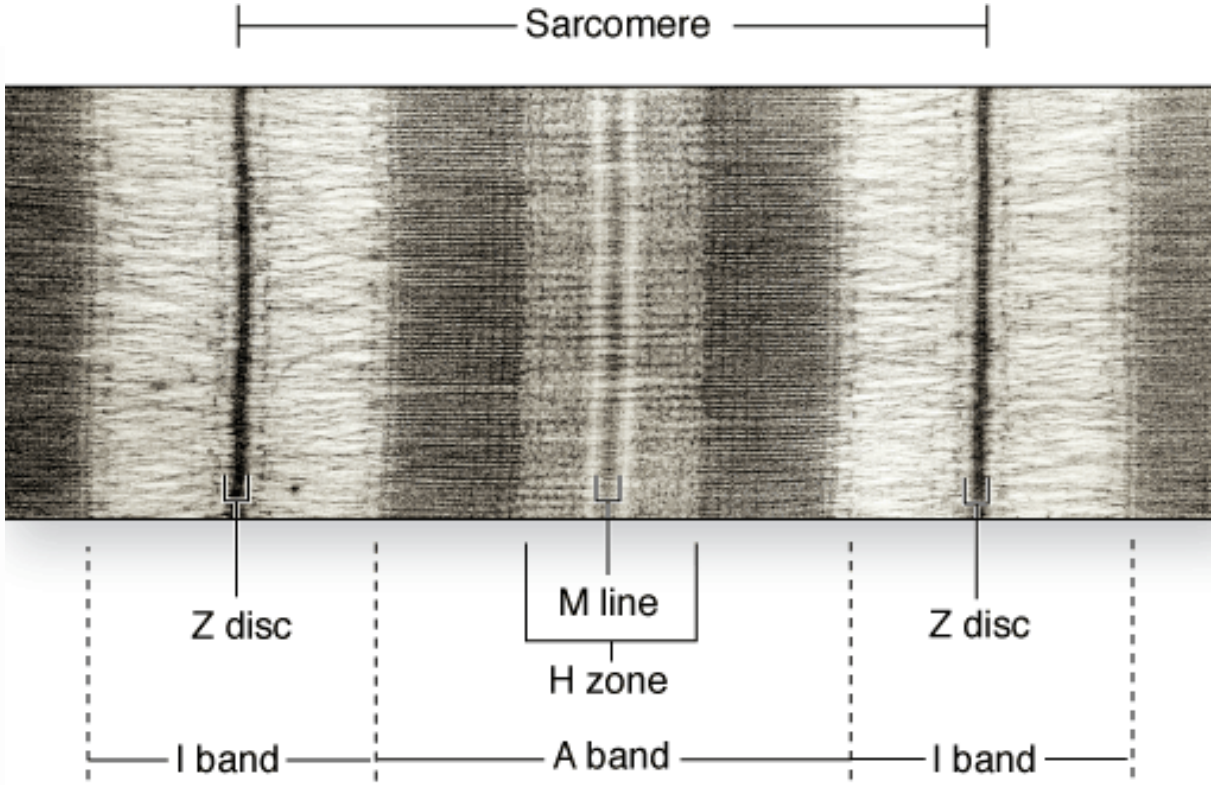

Structure of a myofibril

Sarcomere

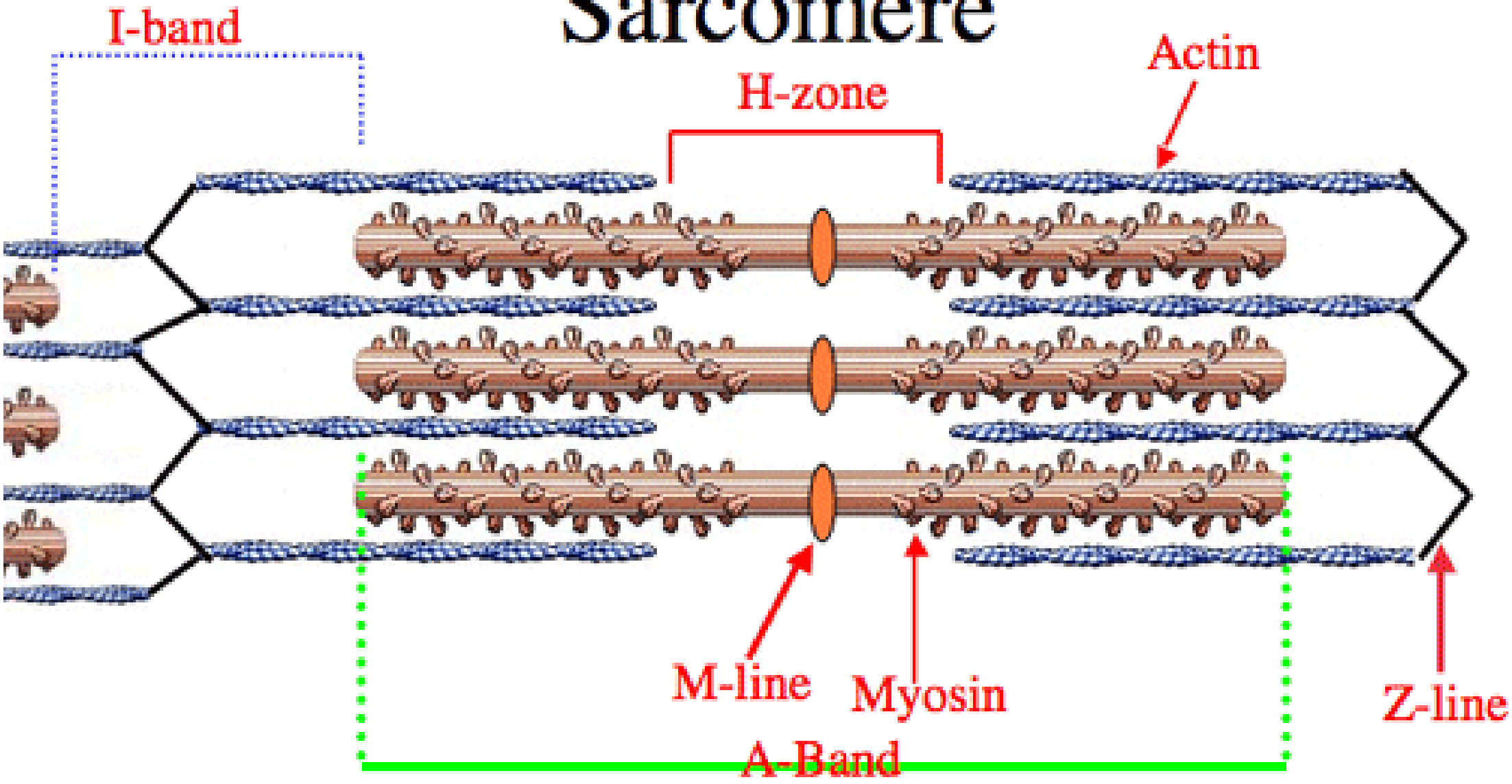

Thick filaments

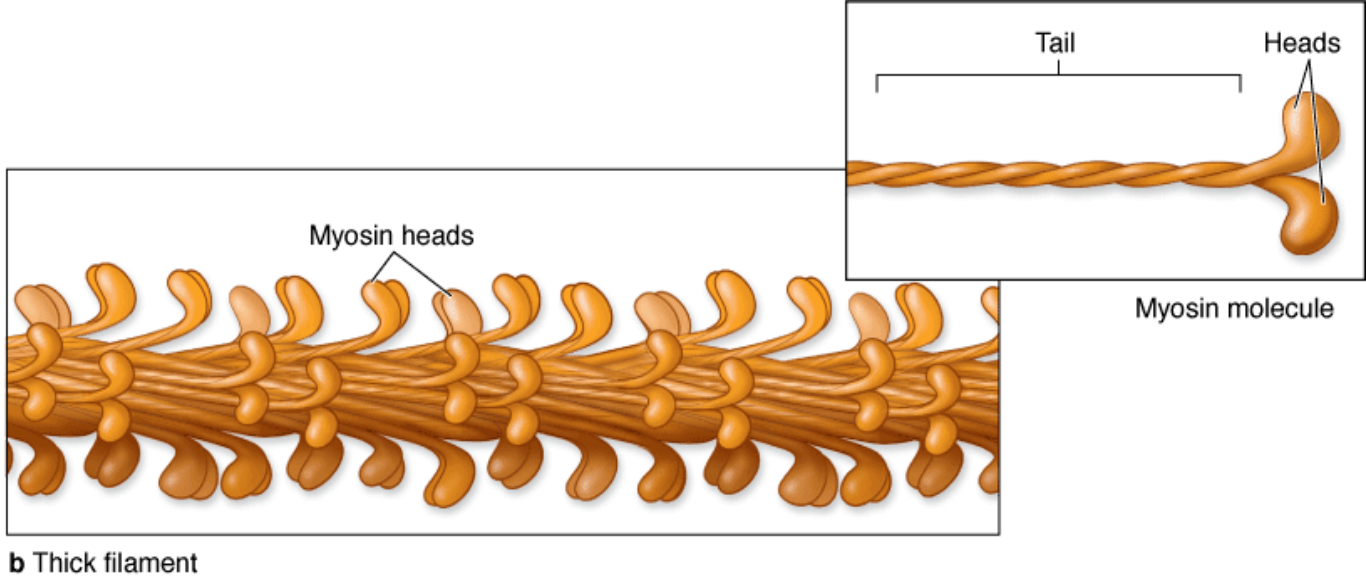

b Thick filament

- Formed of **myosin** protein filaments.
- Occupy the **A band.**
- Myosin has **2 heavy** chains and **2 light** chains
- **Heavy** chains are **twisted** forming **the tail.**
- **Light** chains form the **2 heads**.
- The **2 heads** bind to actin (transient **cross bridge**) and to the **ATP** for energy release.

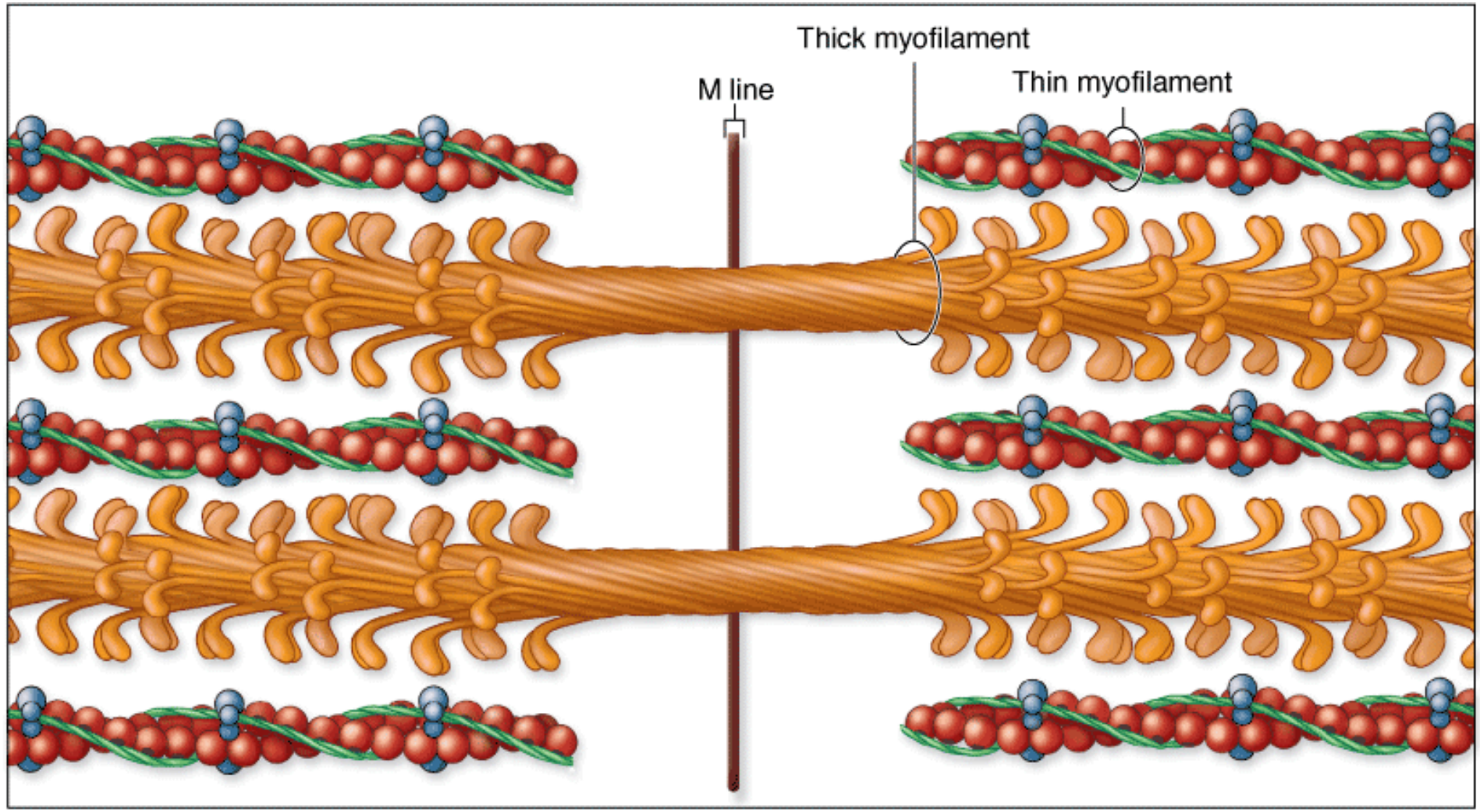

c Comparison of thick and thin filaments

Thin filaments

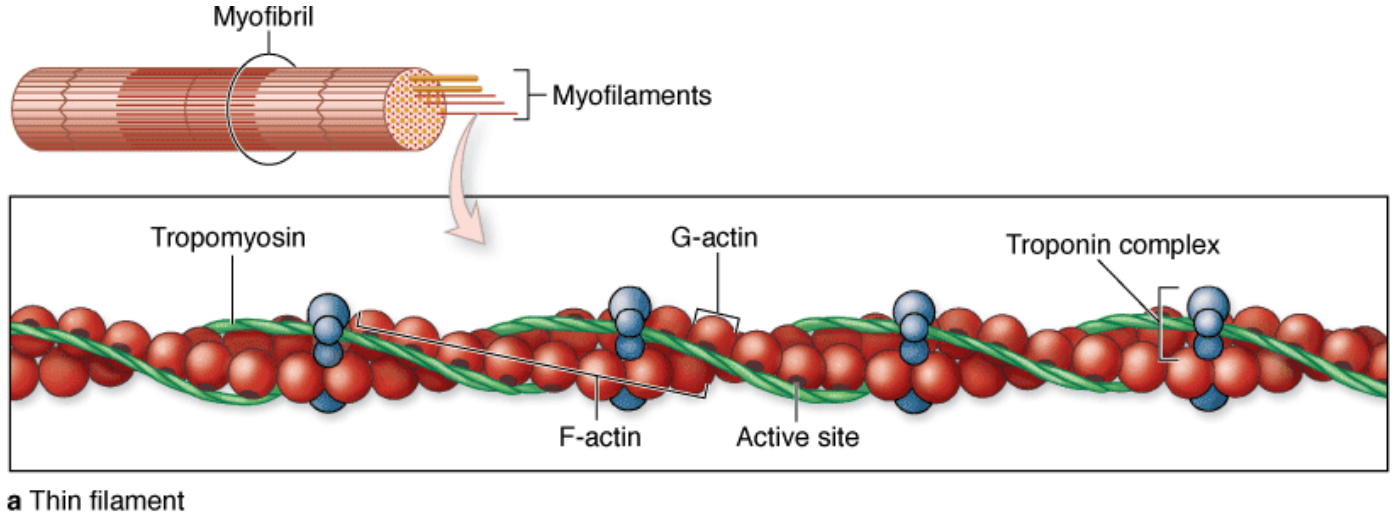

a Thin filament

- These are **actin** filaments.
- **Helical** in shape.
- **Run between** the thick filaments .
- Each **G-actin** monomer contain a **binding site** for myosin.
- It has also 2 tightly associated proteins; **tropomyosin** and **troponin.**

Muscle spindles and tendon organs

- Striated M and myotendinous junctions contain sensory receptors.
- These receptors act as proprioceptors (posture & walking).
- **Muscle spindles** are stretch receptors found among the muscle fascicle.
- They detect and respond to change in the length of the muscles.

Muscle spindles and tendon organs

- **Golgi tendon organs** play the same role of the muscle spindles.
- Encapsulated sensory axons found in the collagen of the myotendinous junction.
- They detect and response to change in tension within the tendon.
- They help to regulate the amount of the effort to perform different movement.

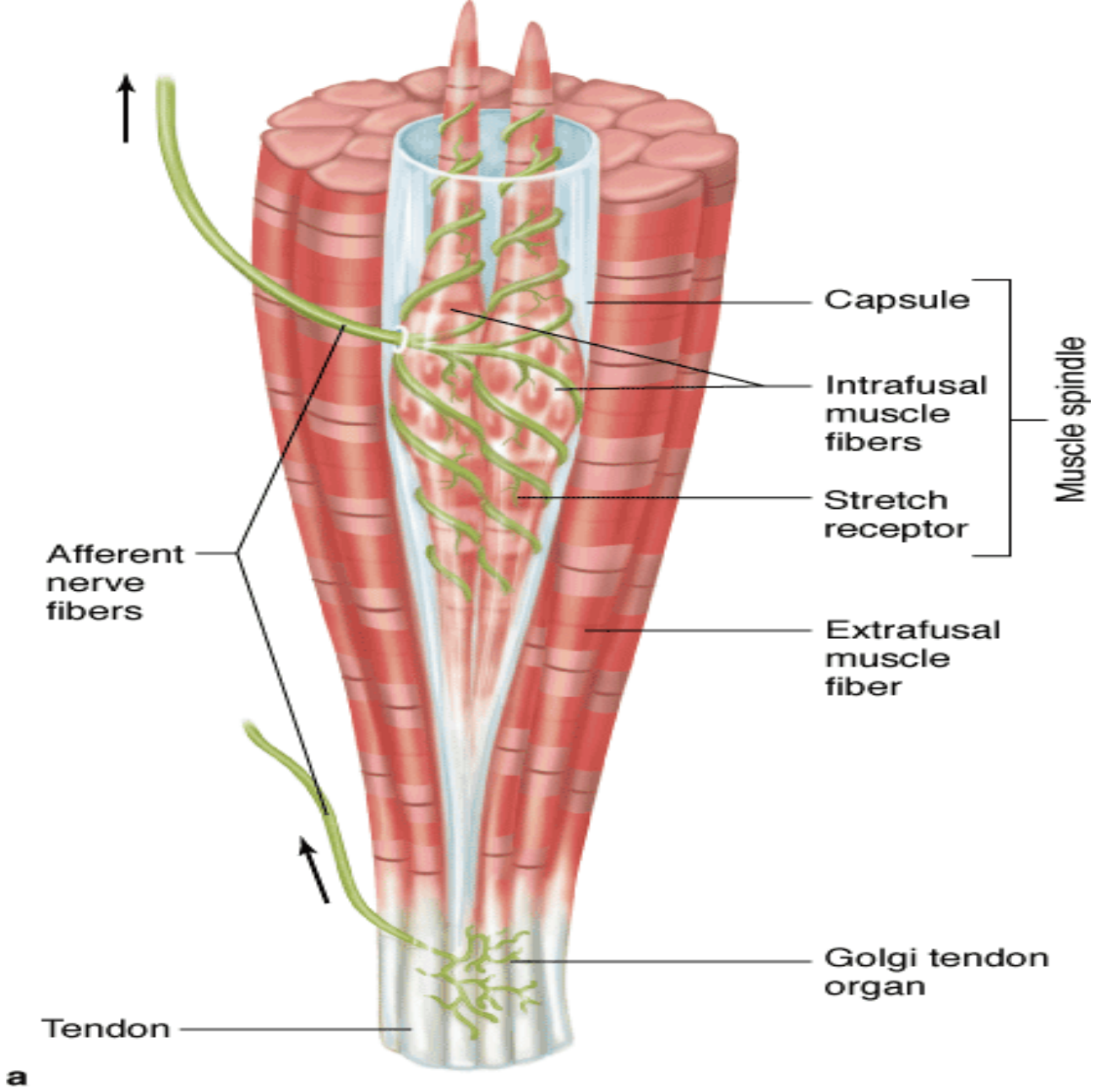

Muscle spindles and tendon organs

Types of the skeletal muscles

- According to the:

✓Protein isoform,
✓Density of the surrounding capillaries,
✓No. of mitochondria,
✓Level of the glycogen & myoglobin.

The muscles are divided into three types.

Type 1, Slow oxidative:

- ✓ It contracts for a long period w/o fatigue.
- ✓ Having many mitochondria.
- ✓ Many surrounding capillaries.
- ✓ Much myoglobin.
- ✓ It stain dark red.
- ✓ Posture muscles of the back.

Type 2, fast glycolytic:

- ✓ specialized for rapid short-term contraction.
- ✓ few mitochondria and few capillaries.
- ✓ anaerobic metabolism of the glycogen.
- ✓ appear white.
- ✓ extra-ocular muscles.

Type 3, fast oxidative-glycolytic:

- ✓ Fibers with intermediate physiological and histological features between the other two types.
- ✓Major muscles of the leg.

Cardiac muscle

- Composed of elongated **branched** cells.
- Has **cross** striations .
- Cells are bound together by structure called **intercalated** disc.
- Intercalated disc are **unique** to cardiac muscles.
- Contraction is vigorous **rhythmic** and i**nvoluntary**.

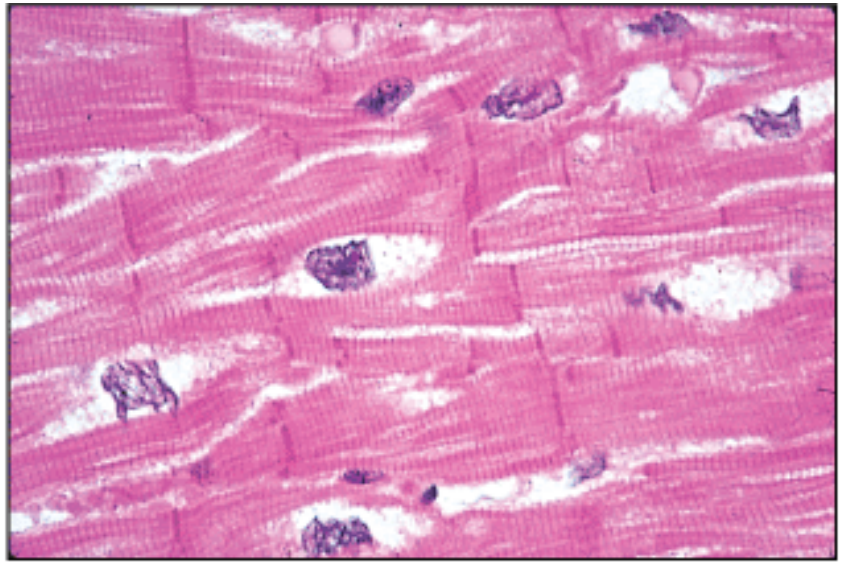

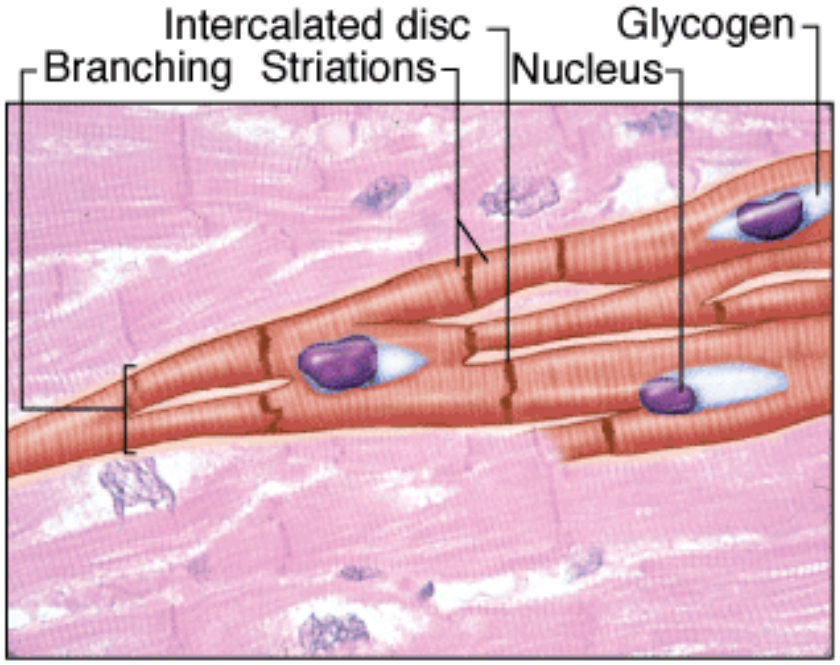

b Cardiac muscle

- During embryonic development, C.M cells form interdigitating processes.
- Cells within one fiber branch & join cells in adjacent fibers.
- Consequently, the heart consists of tightly knit bundles of cells, interwoven in spiraling layers.
- This make the heart’s contraction wavy.
- Mature C.M. cell is 15-30 μm diameter and 85-120 μm long.
- It has only one nucleus, centrally located.
- Endomysium surrounding the muscle cells is rich in capillaries.
- Perimysium is thick in certain areas making the cardiac skeleton.

- A unique feature is **inter-calated** discs.
- They cross the fibers at **irregular interval** where the myocardial cells join.
- They represent interfaces between cells and consist of **many junctional complexes**.
- Many **desmosomes** and **adheren**t junctions provide strong adhesion during contraction
- **Gap junctions** provide ionic continuity between cells.

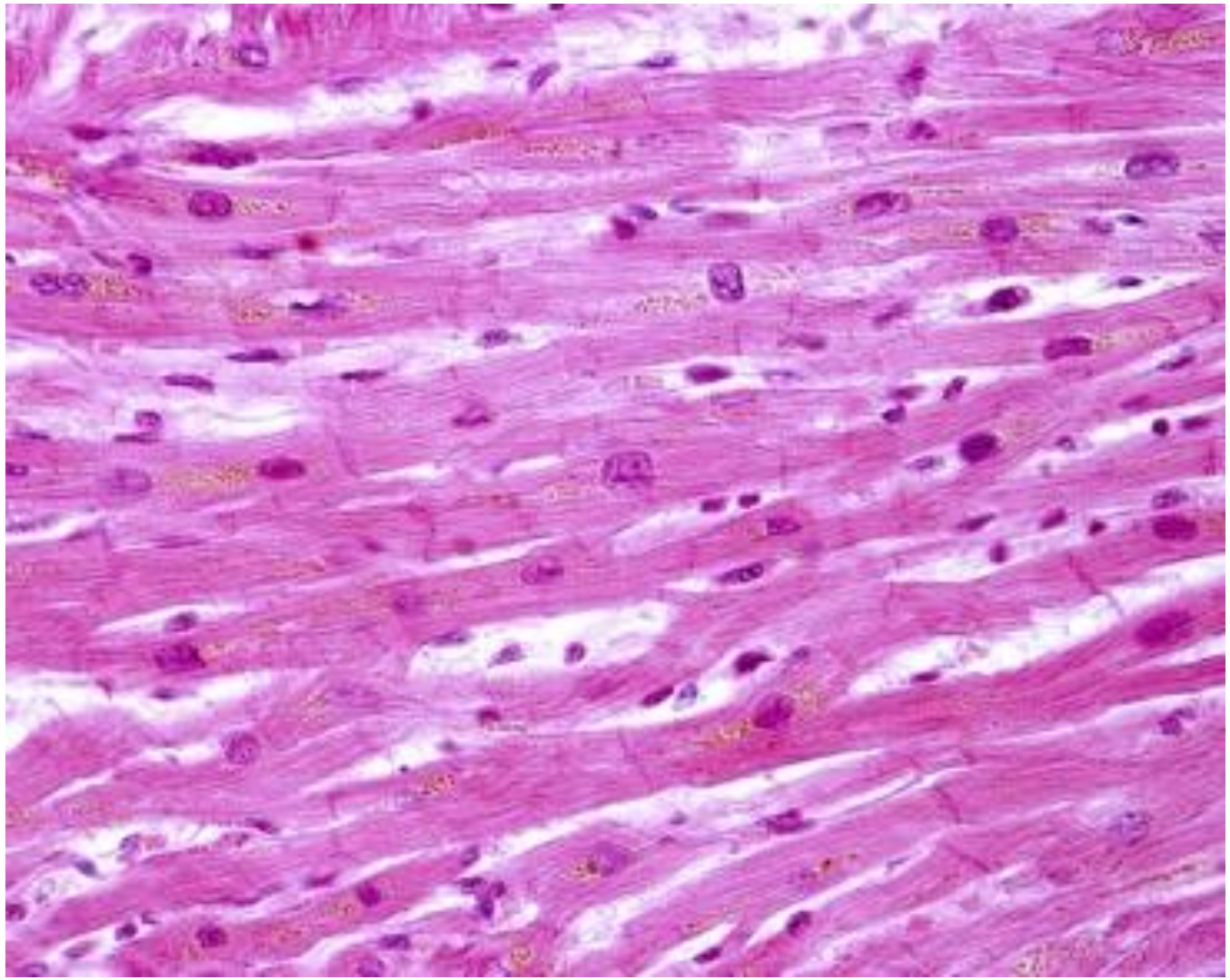

Cardiac Muscle

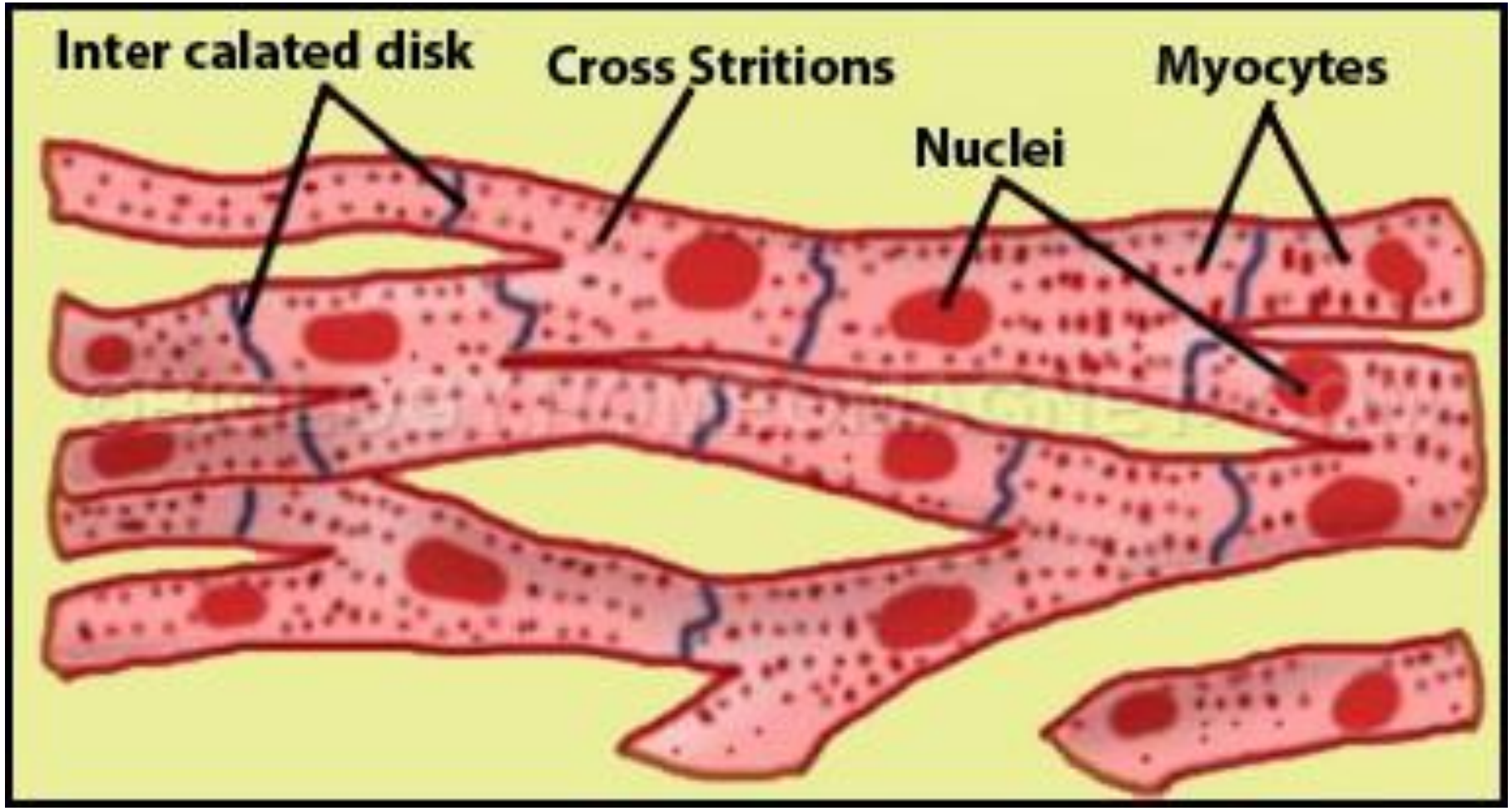

Cardiac Muscle

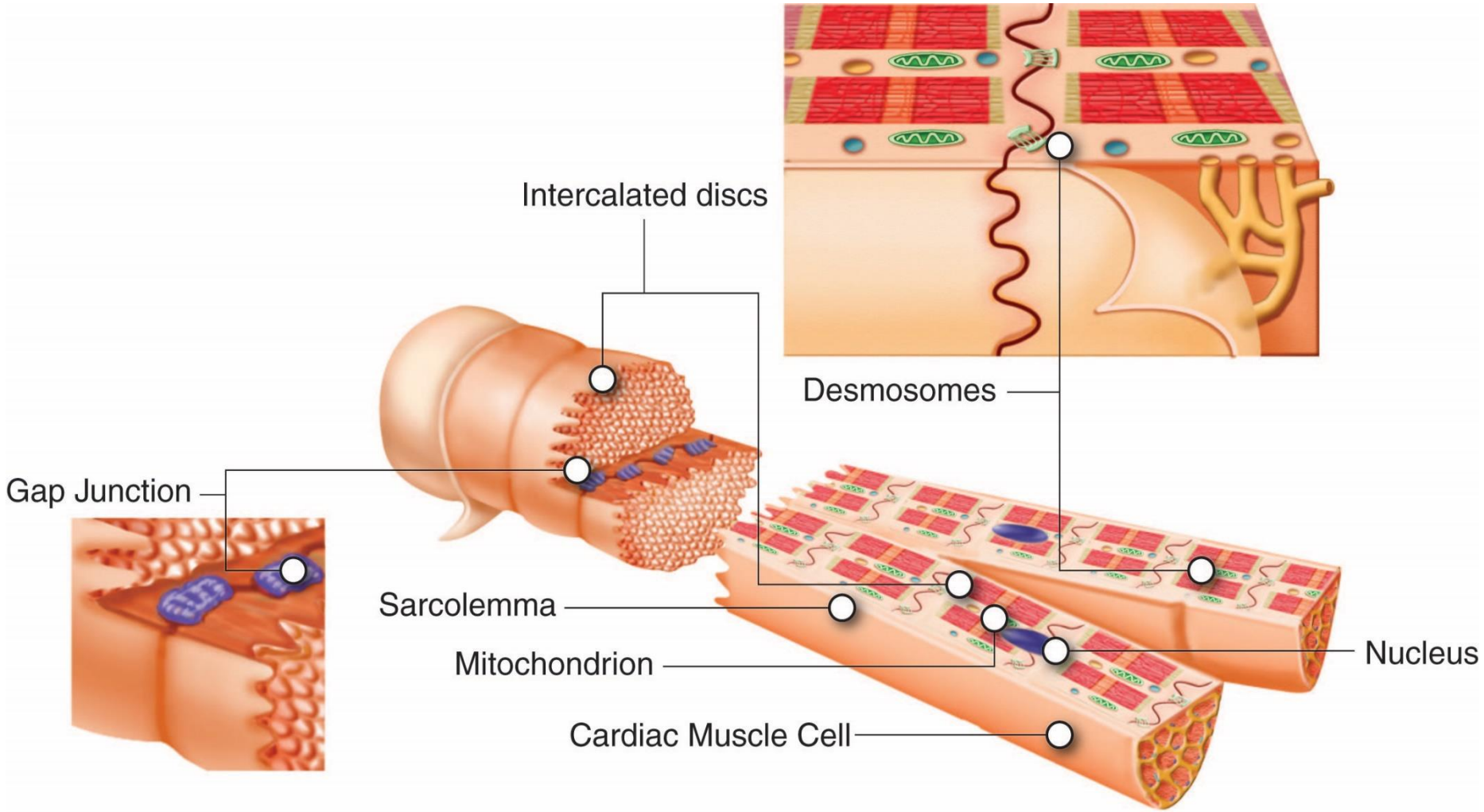

Cardiac Muscle

Smooth muscles

- Consists of collections of **fusiform** cells.
- **It lacks striations**
- **Slow involuntary** contractions.
- Their **endomysium** is formed of type I and III collagen.
- The cells are linked by numerous **Gap junctions.**
- Smooth m. **lack T-tubules** and have rudimentary sarcoplasmic Reticulum.
- The actin is not associated with troponin and tropomyosin.
- Instead it uses calmodulin and myosin light chain kinase (MLCK) to produce contraction.

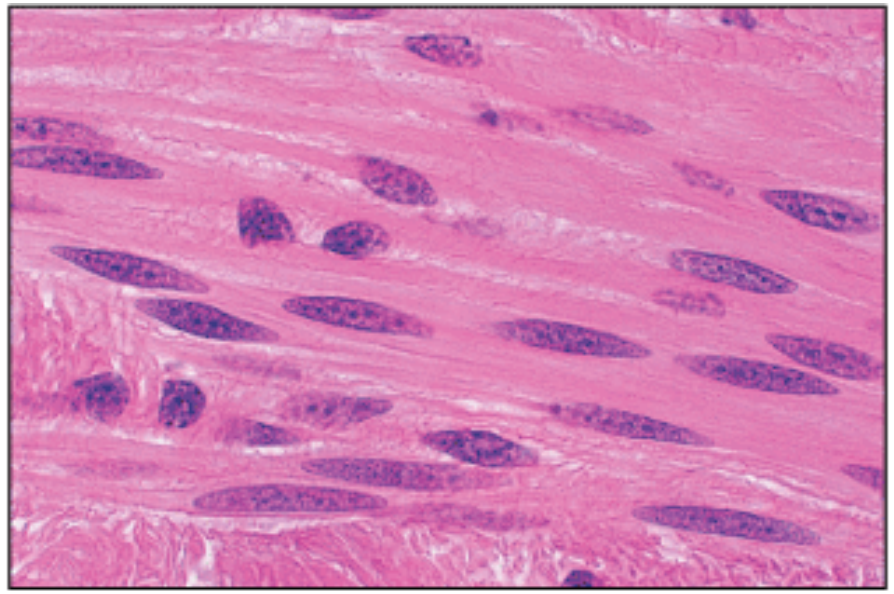

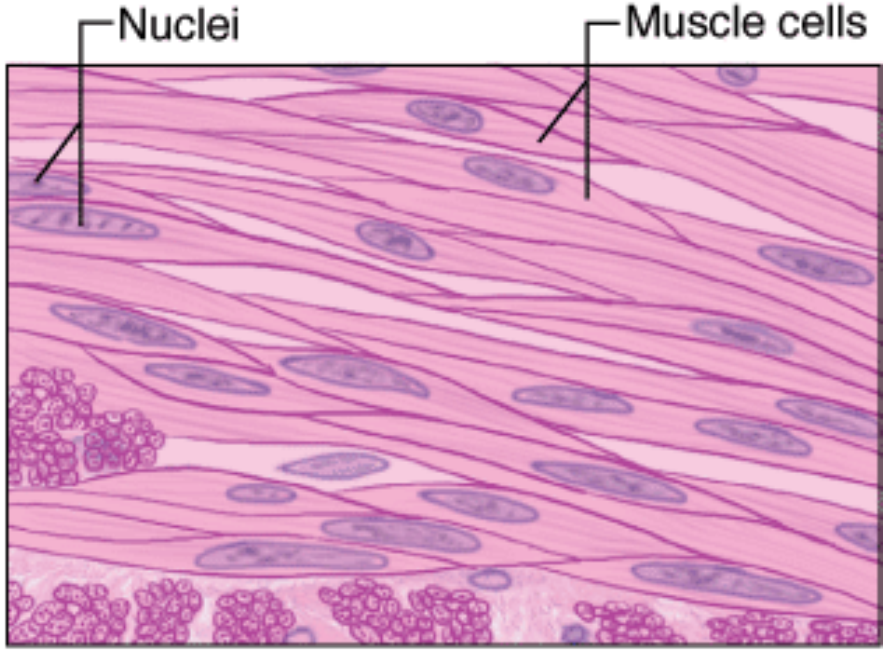

c Smooth muscle

- Specialized for slow, steady contraction under the influence of the autonomic nerves and various hormones.

- Major components of:

✓ blood vessels

✓Digestive

✓Urinary

✓Respiratory

✓Reproductive

Smooth M

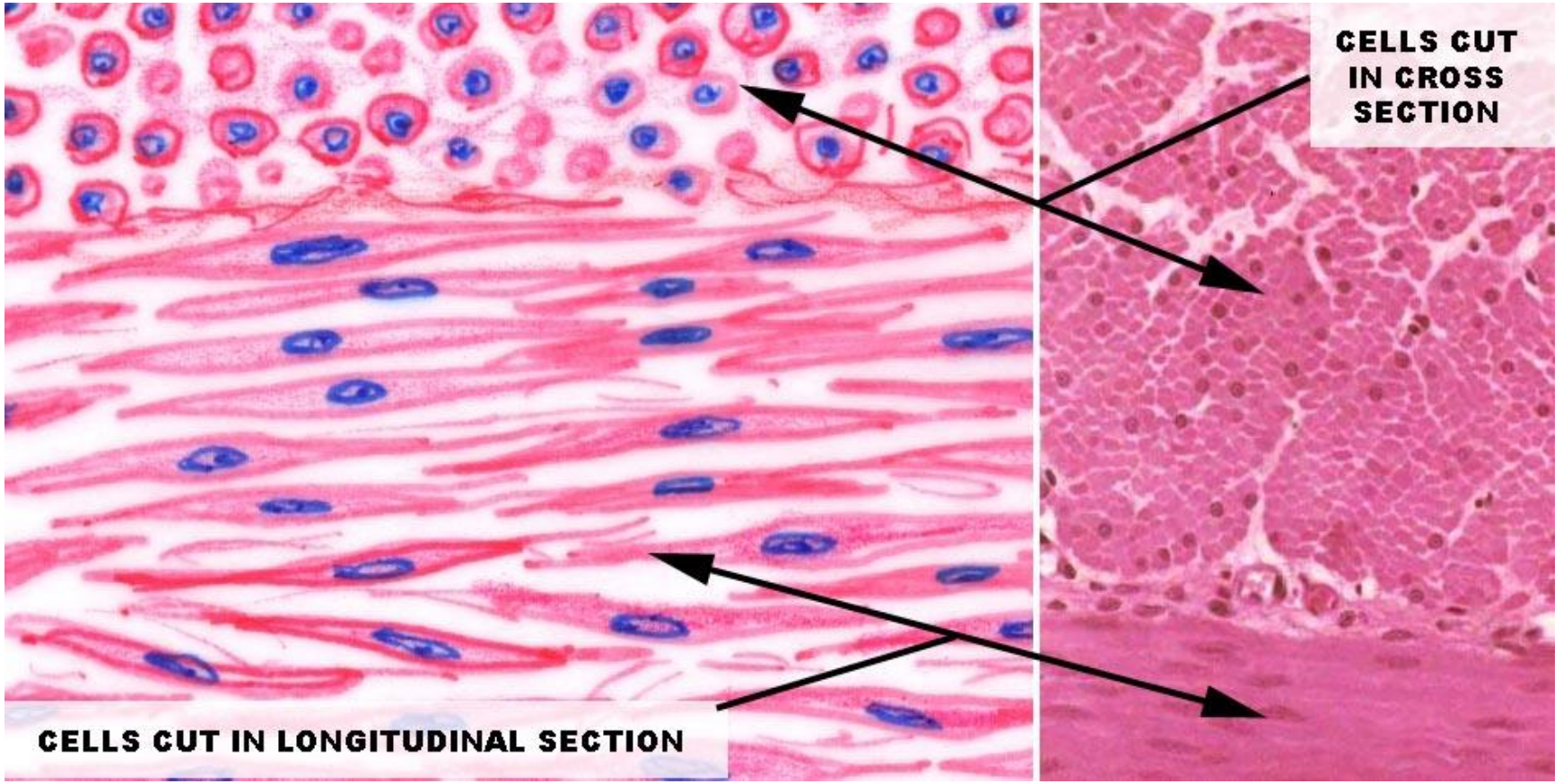
CELLS CUT IN CROSS SECTION
CELLS CUT IN LONGITUDINAL SECTION

Smooth m. contraction

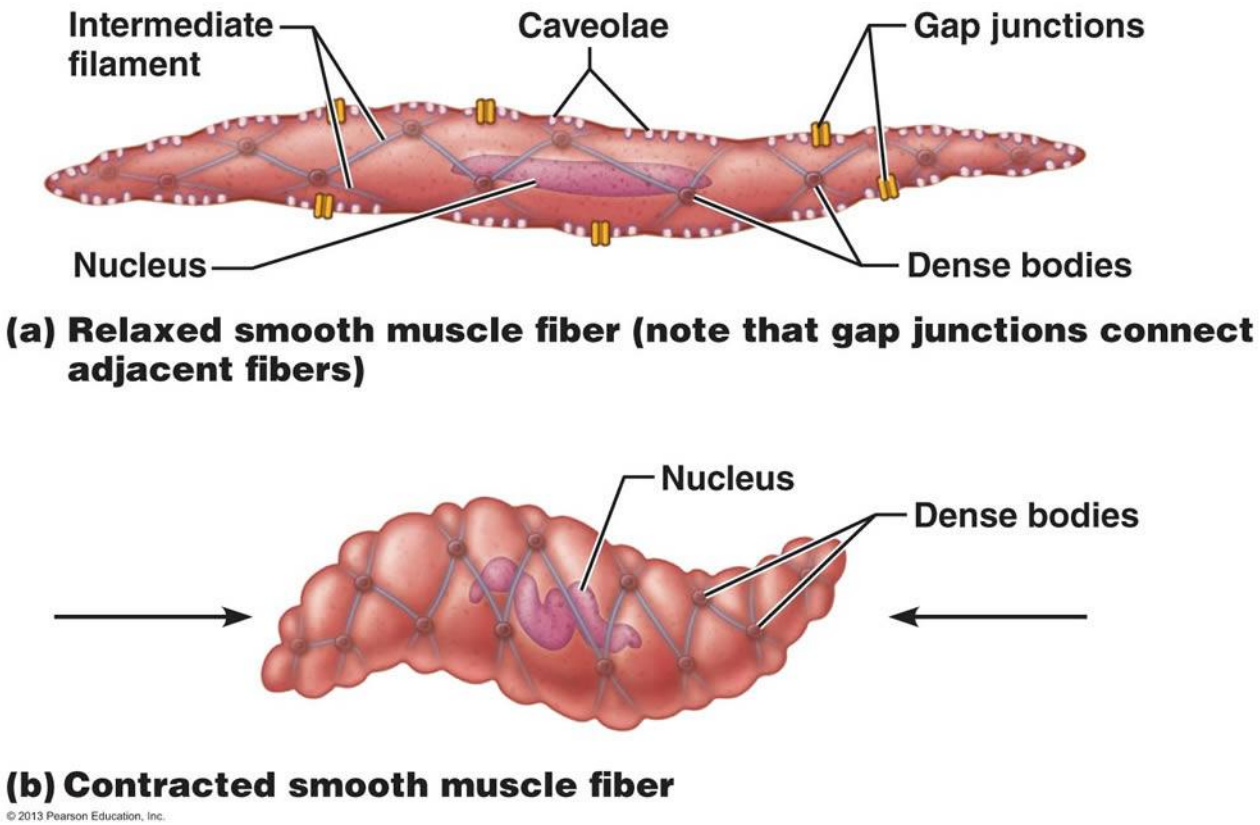

Regeneration

- **Skeletal muscle**, although the multinucleated cells cannot undergo mitosis, the tissue can still display limited regeneration. The source of regenerating cells is the sparse population of mesenchymal satellite cells that lies within the external lamina of each mature muscle fiber. Satellite cells are inactive, reserve myoblasts that persist after muscle differentiation. The regenerative capacity of skeletal muscle is limited, however, occurring less well after major muscle trauma.
- **Cardiac muscle** lacks satellite cells and shows very little regenerative capacity beyond early childhood. Defects or damage (eg, infarcts) to heart muscle are generally replaced by proliferating fibroblasts and growth of connective tissue, forming myocardial scars.
- **Smooth muscle**, composed of simpler, smaller, mononucleated cells, is capable of a more active regenerative response. After injury, viable smooth muscle cells undergo mitosis and replace the damaged tissue.

Thank You