THE SECOND WEEK OF DEVELOPMENT

Dr. Musab N. Husein
MBChB, MSc

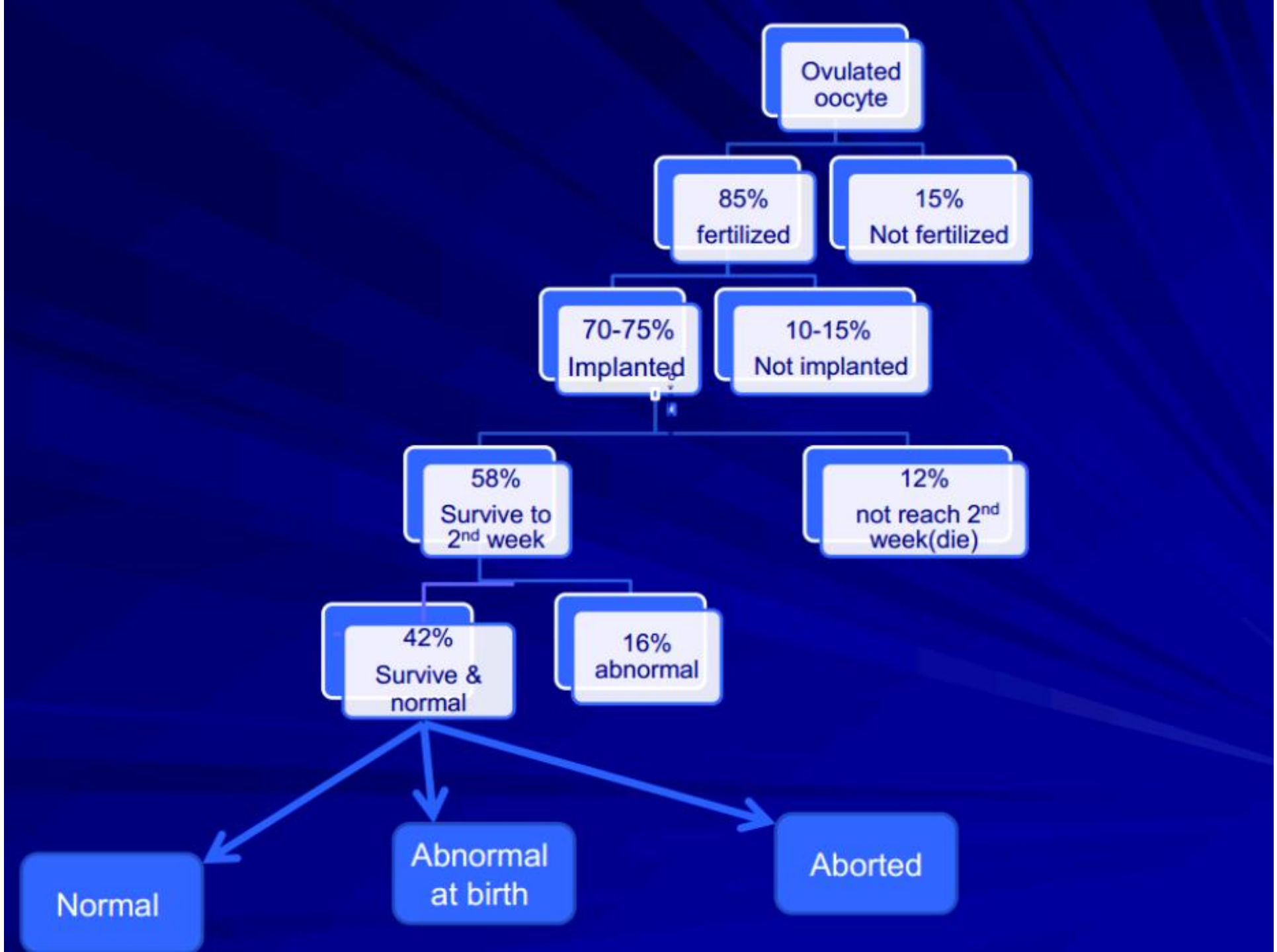
Ovulated oocyte
85% fertilized
15% Not fertilized
70-75% Implanted
10-15% Not implanted
58% Survive to 2nd week
12% not reach 2nd week(die)
42% Survive & normal
16% abnormal
Normal
Abnormal at birth
Aborted

THE SECOND WEEK OF DEVELOPMENT IS THE WEEK OF TWOS, BECAUSE OF THE FOLLOWING:

1- The trophoblast differentiates into 2 layers .

2- The emberyoblast differentiates into 2 layers .

3- The primary mesoderm splits into 2 .

4- Starting of formation of the 2 cavities.

❖ The second week of development is significant for:

1. ***The formation of the bilaminar disc (two-layers emberyo) – this will give rise to all the tissues and organs of the body.***
2. ***The completion of implantation .***

DAY 8

❖**Major events :**

1- Blastocyte partially embedded .

2- Trophoblast differentiate .

3- Emberyoblast differentiate .

4- Cavity appear in epiblast .



1- BLASTOCYST EMBEDDED

Blastocyst partially embedded .

The endometrial mucosa changes :

- edematous .
- highly vascular .
- secrete glycogen and mucus from its large glands.



2- TROPHOBLAST :

➢The trophoblast differentiates into:

a. Inner mononucleated cytotrphoblastic cells.

b. Outer multinucleated syncytiotrophblastic.



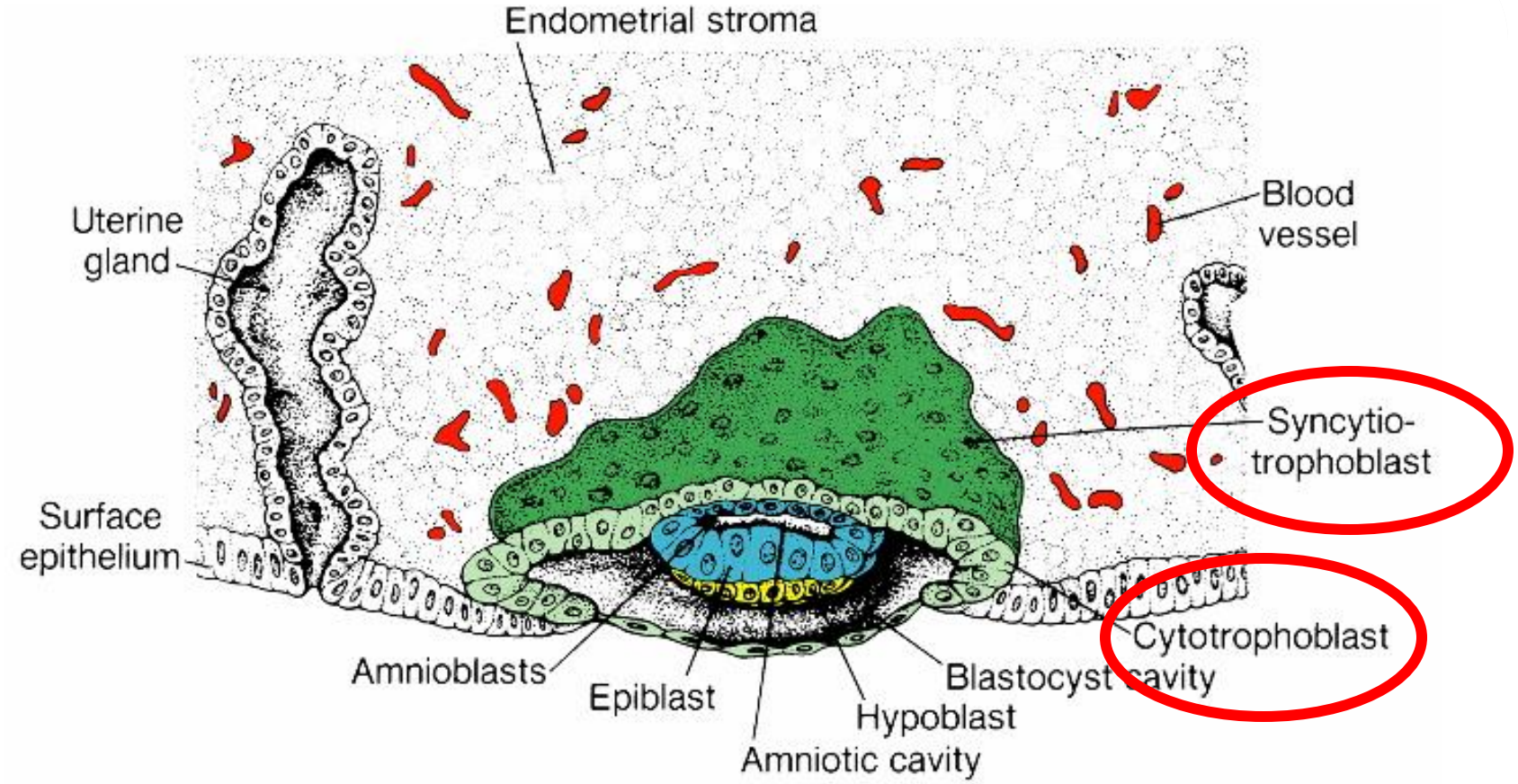

Figure 3.1 A 7.5-day human blastocyst, partially embedded in the endometrial stroma. The trophoblast consists of an inner layer with mononuclear cells, the cytotrophoblast, and an outer layer without distinct cell boundaries, the syncytiotrophoblast. The embryoblast is formed by the epiblast and hypoblast layers. The amniotic cavity appears as a small cleft.

Copyright © 2003 Lippincott Williams & Wi

TROPHOBLAST DEFFRENTIATION

❖ Syncitiotrophoblasts :

- secrete proteolytic enzymes, that break down extracellular matrix around cells alow passage of blastocyst into endometrial wall .
- secrete Human Chorionic Gonadotropin (hCG), hormone.



HUMAN CHORIONIC GONADOTROPIN

- Initially secreted by syncitiotrophoblasts during week two.
- Detected in maternal blood and urine and is the basis of pregnancy tests.

❖ **<u>Human Levels</u>** :

levels peak at 8 to 10 weeks of pregnancy, then decline and are lower for rest of pregnancy .



HUMAN CHORIONIC GONADOTROPIN

❖**Functions:**

- Promotion of corpus luteum .
- Angiogenesis of uterine vasculature .
- Immuno-suppression and blockage of phagocytosis of invading trophoblast cells .
- Growth of uterus in line with fetal growth .



Ovary

Uterus

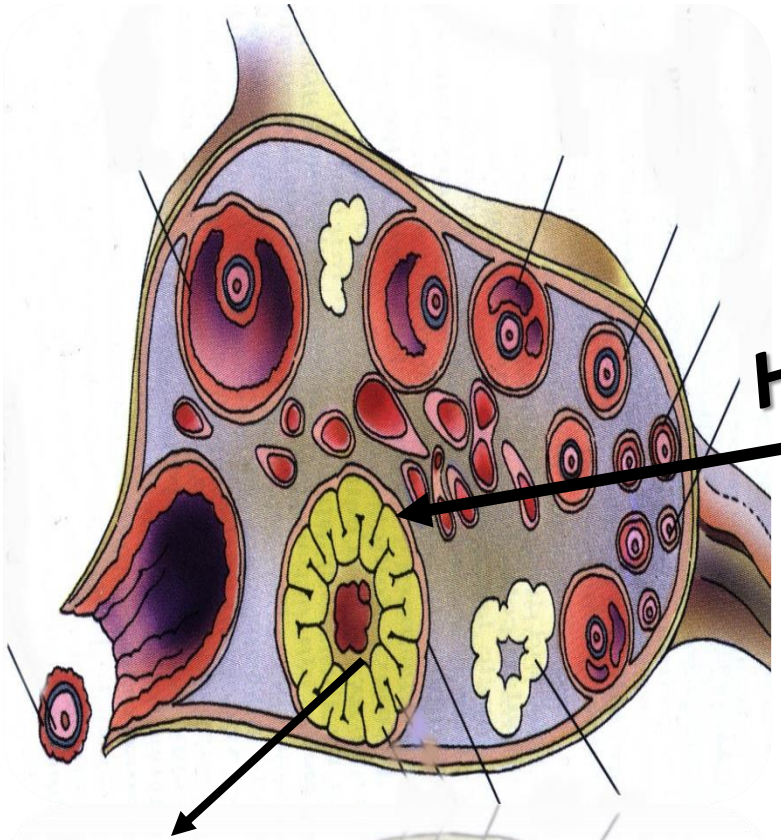

HCG

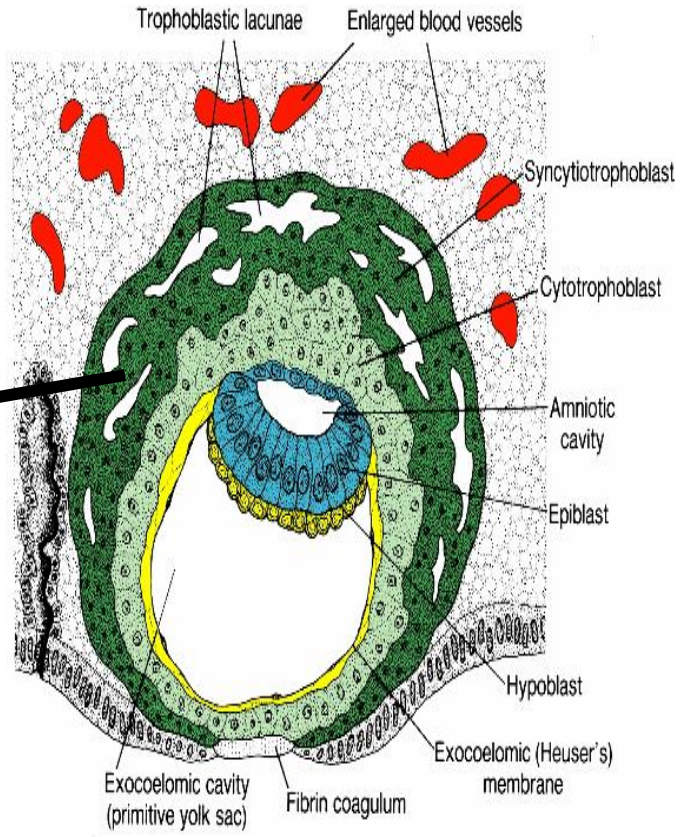

Produces P+ E to maintain the pregnancy

3-EMBERYOBLAST

(BILAMINAR GERM DISC)

The inner cell mass is differentiated into:

❑- **Epiblast** = ectoderm (high columnar cells facing the amniotic cavity).

❑- **Hypoblast**= endoderm (small cuboidal cells facing blastocyst cavity .

Together these layers form a flat disc.



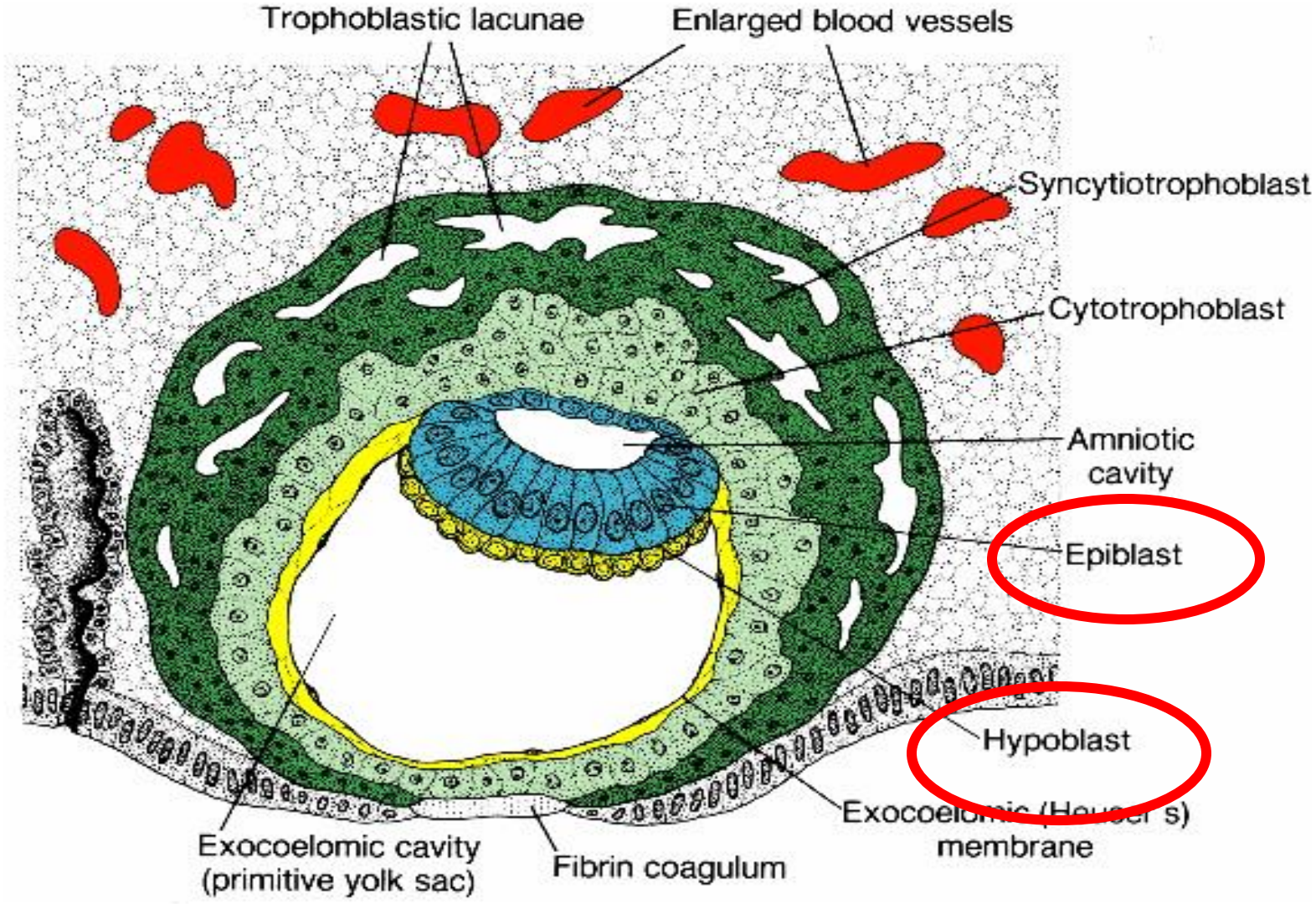

BILAMINAR GERM DISC

4- Amniotic cavity.

- Cavity apperas within the epiblast to form the ***amniotic cavity.***
- The epiblast will surround the amniotic cavity (amnioblast) so form ***membrane.***



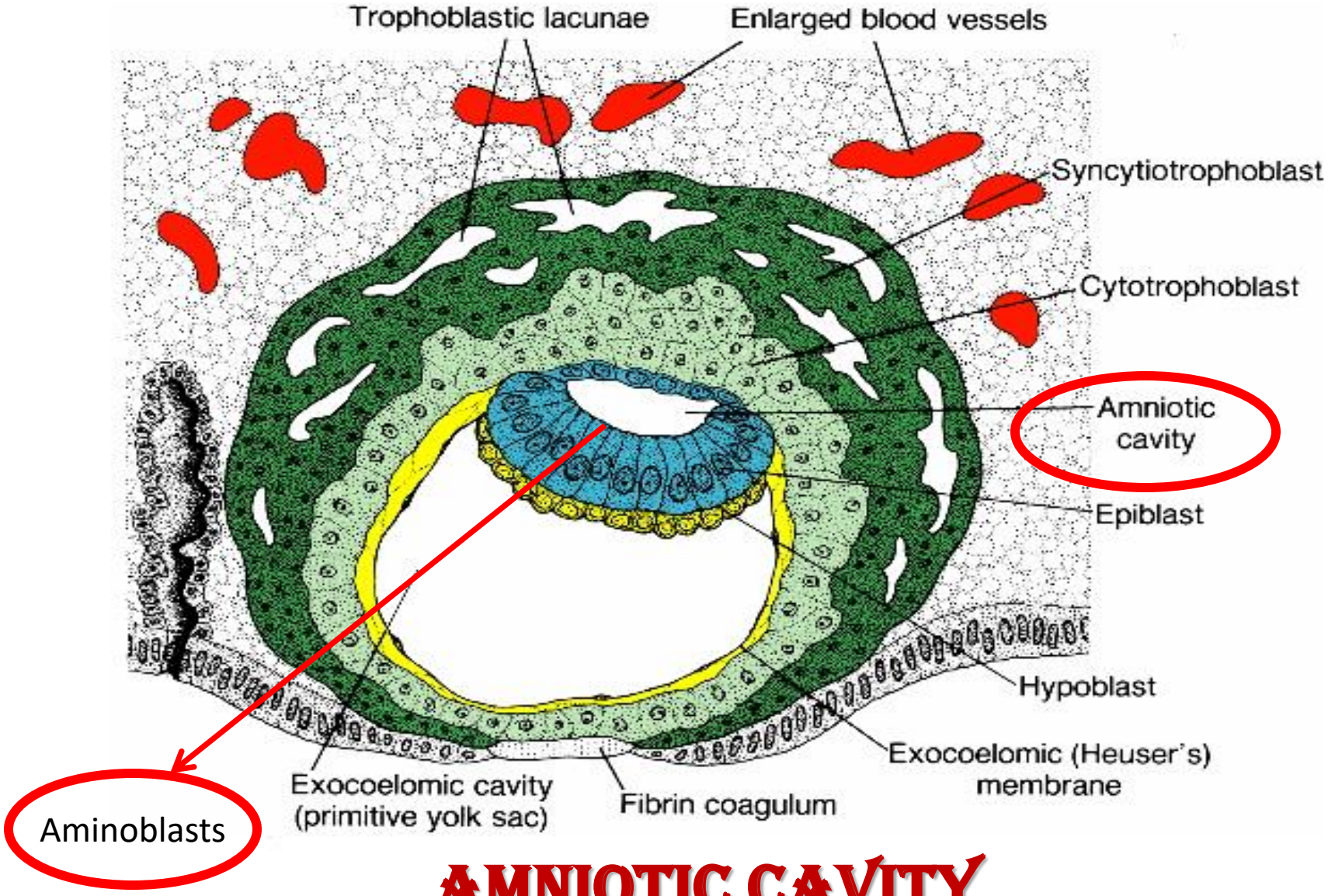

AMNIOTIC CAVITY

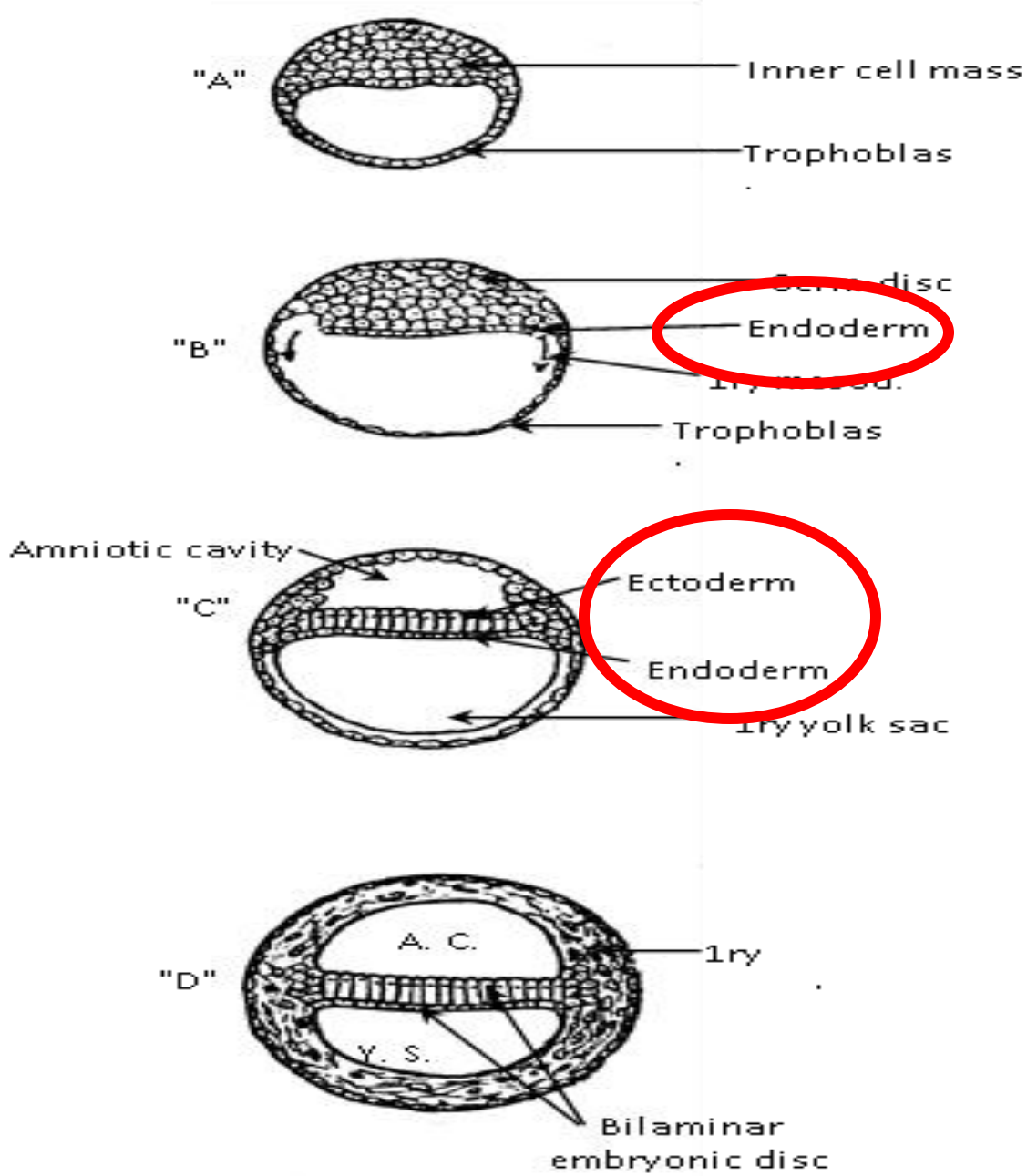

Fig. 36: Differentiation of the inner cell mass.

SUMMARY OF DAY 8

1- Blastocyst partially embedded .

2- Trophoblast differentiate .

3- Emberyoblast differentiate .

4- Cavity appear in epiblast .

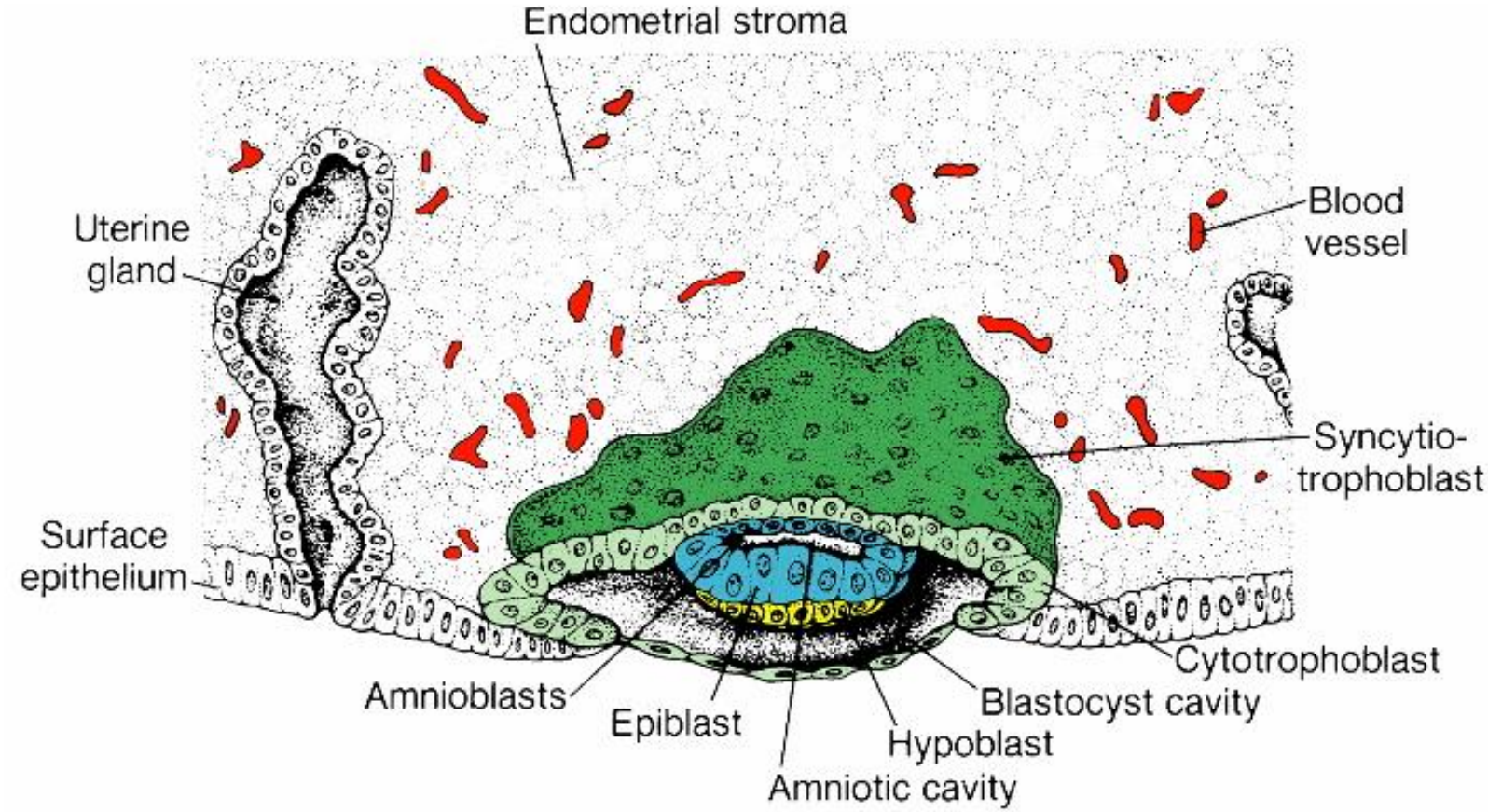

Figure 3.1 A 7.5-day human blastocyst, partially embedded in the endometrial stroma. The trophoblast consists of an inner layer with mononuclear cells, the cytotrophoblast, and an outer layer without distinct cell boundaries, the syncytiotrophoblast. The embryoblast is formed by the epiblast and hypoblast layers. The amniotic cavity appears as a small cleft.

Copyright © 2003 Lippincott Williams & Wilkins

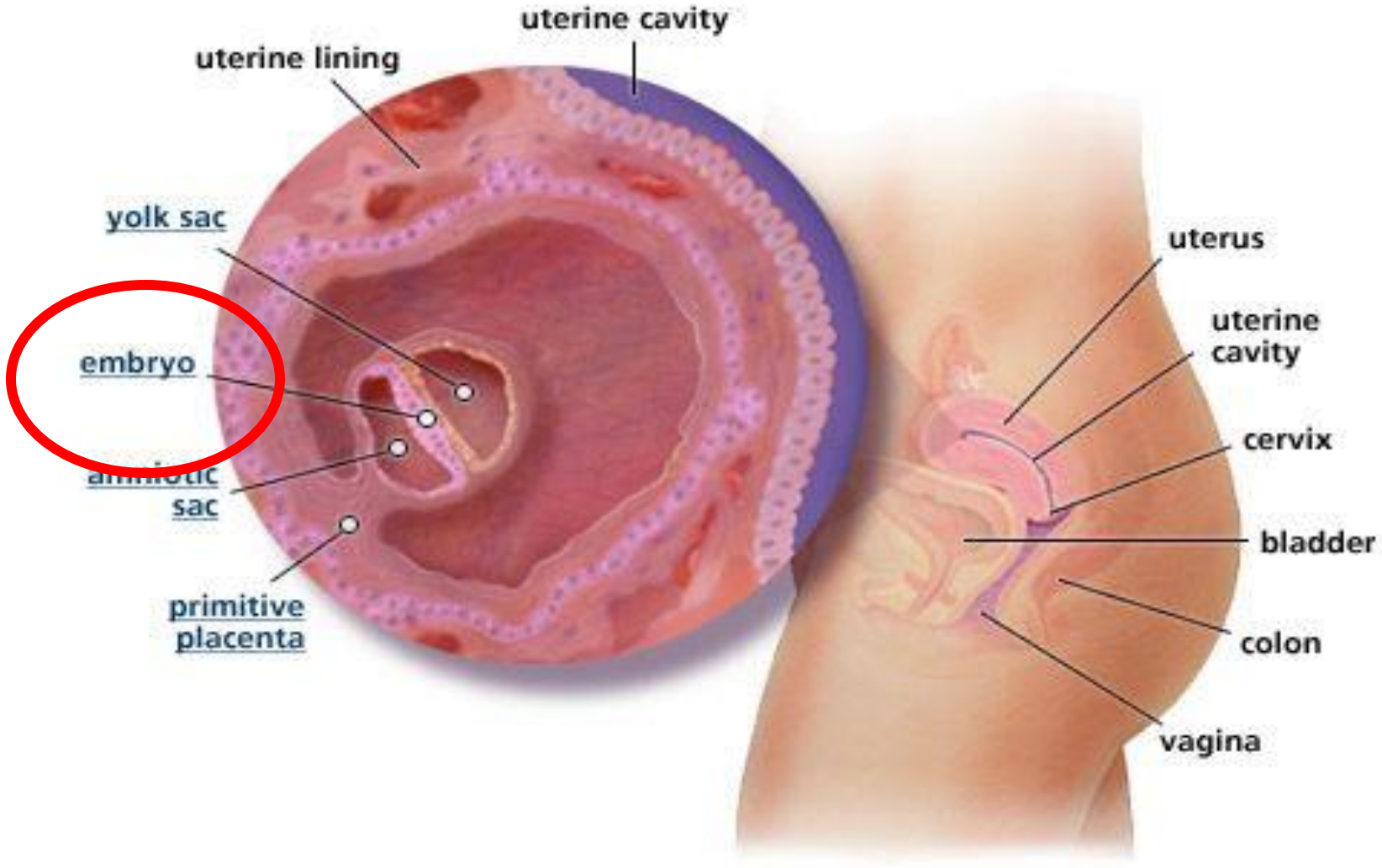
uterine cavity
uterine lining
yolk sac
embryo
amniotic sac
primitive placenta
uterus
uterine cavity
cervix
bladder
colon
vagina

DAY 9

❖**<u>Major events :</u>**

1- Blastocyst deeply embedded .

2- Penetration site closed by fibrin coagulum .

3- lacunae stage .

4-Exocoelomic membrane formed from flat cell from hypoblast forming exocoelomic cavity (primetive yolk sak) .



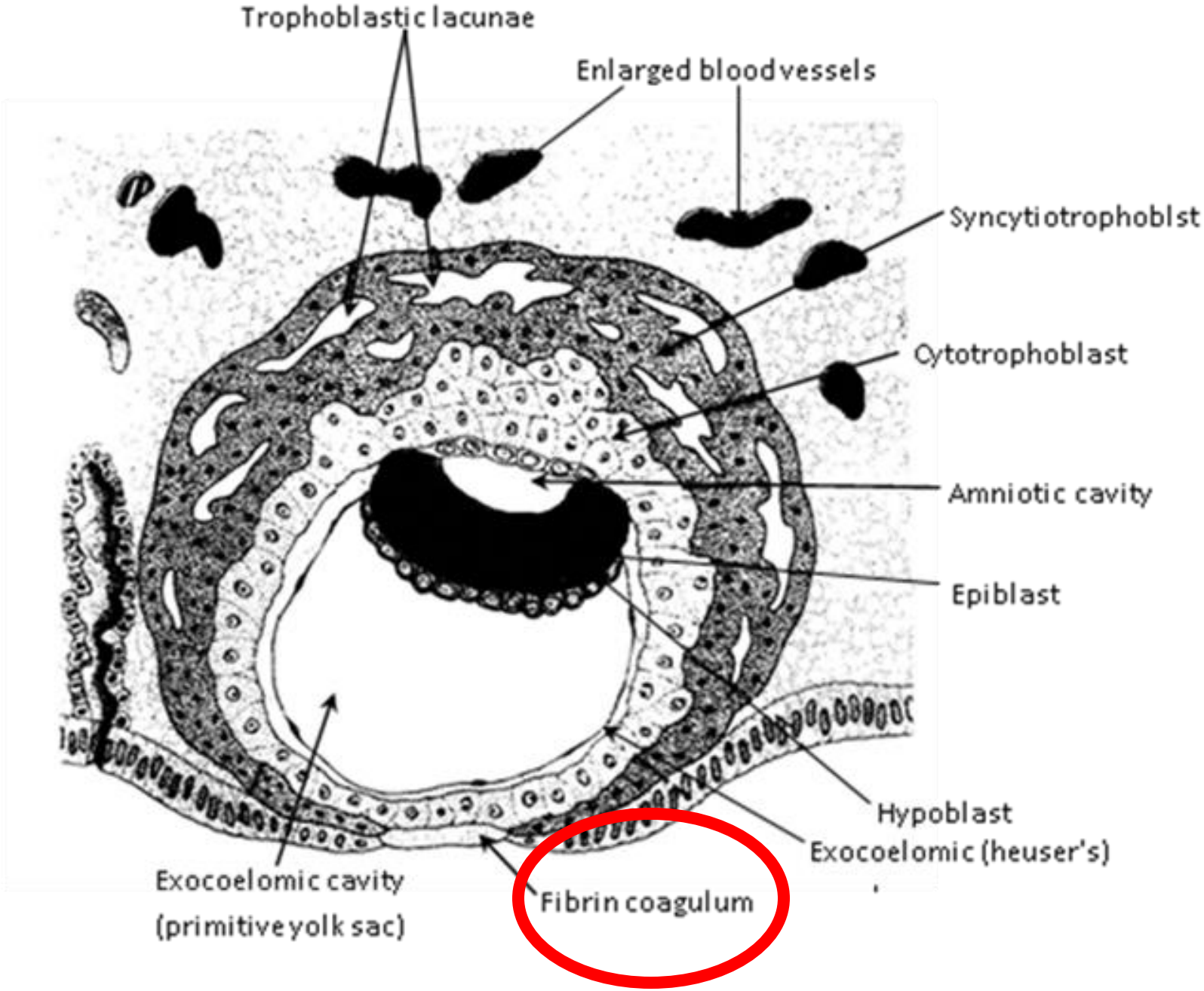

Fig. 34: Drawing of a 9 day human blastocyst.

LACUNAE STAGE

- The syncytiotrophoblast erodes the maternal tissues
- Vacuoles appear in cyncytium , then fuse to form lacunae stage.



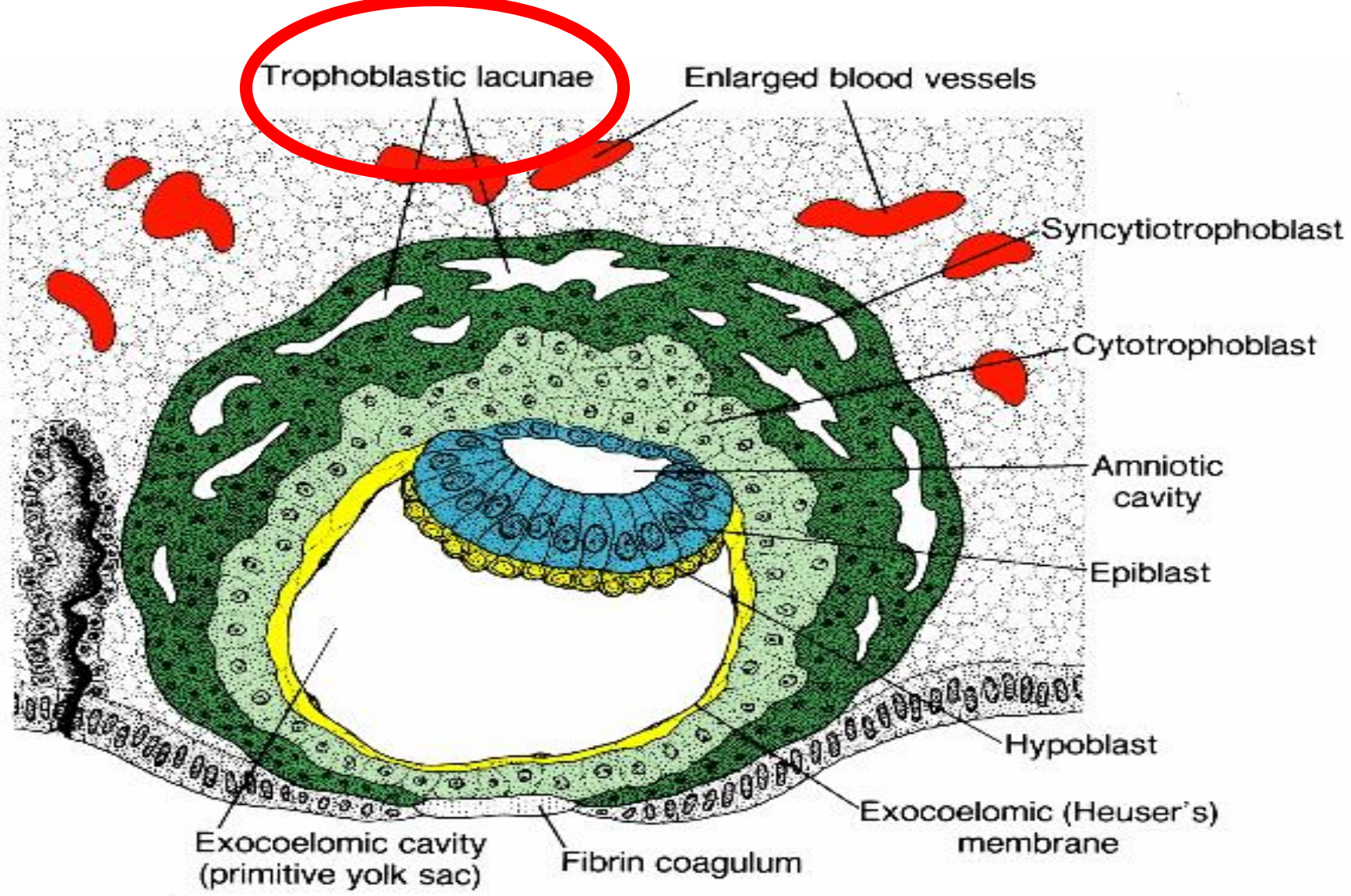

LACUNAE STAGE

4_ EXOCOELOMIC CAVITY

(PRIMETIVE YOLK SAK) .

- The hypoblast cells migrate and line the inner surface of cytotrophoblast ,forming the exocoelomic membrane (heuser) which limits a space called the exocoelomic cavity (**primary or primitive yolk sac**).
- This cavitiy allow movement of the emberyonic disc .
- The yolk sac contains no yolk- the embryo is nourished from the lacunar networks- but may have a role in selective transfer of nutrients .

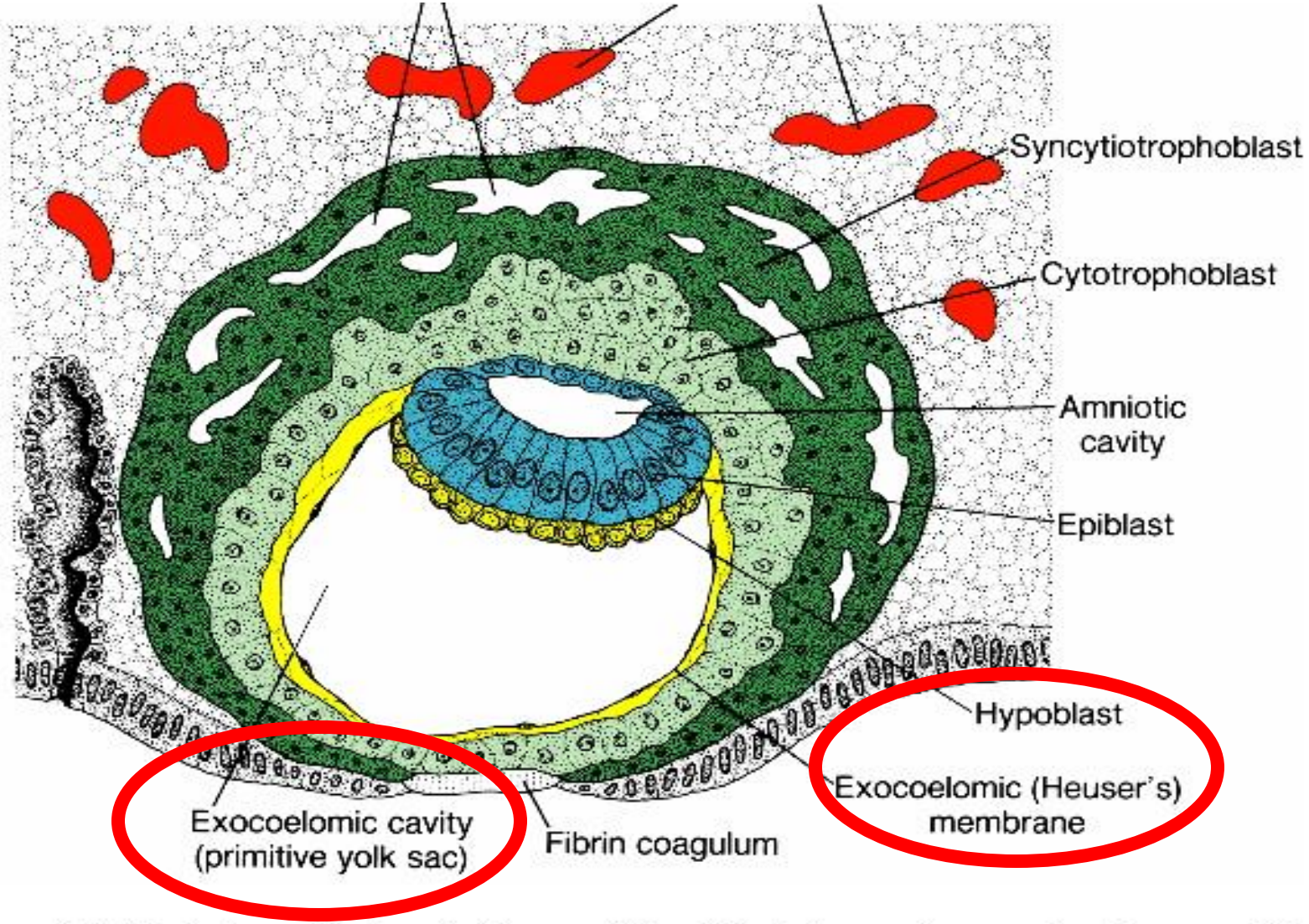

Figure 3.3 A 9-day human blastocyst. The syncytiotrophoblast shows a large number of lacunae. Flat cells form the exocoelomic membrane. The bilaminar disc consists of a layer of columnar epiblast cells and a layer of cuboidal hypoblast cells. The original surface defect is closed by a fibrin coagulum.

Copyright © 2003 Lippincott Williams & Wilkins

EXOCOELOMIC CAVITY

Summary

1- Blastocyt deeply embedded .

2- Penetration site close by fibrin coagulum .

3- lacunae stage .

4- Exocoelomic membrane formed from flat cell from hypoblast forming exocoelomic cavity (primetive yolk sak) .



DAY 11 – 12

❖ **Major events** :

1- Trophoblast completely embedded .

2- Blastocyst slightly protrude to lumen .

3- Uteroplacental circulation establish .

4- Formation of the extra-embryonic mesoderm and extra-embryonic cavity (*chorionic cavity*) .

5- Decidua reaction .

UTEROPLACENTAL CIRCULATION :

- Trophoblast characterize by lacunae forming intercommunicating network.
- Sinusoids appear (deep erosion of cyncytium cell in endothelium of maternal capillary .
- Lacunae became continuous with sinusoids (uteroplacental circulation)

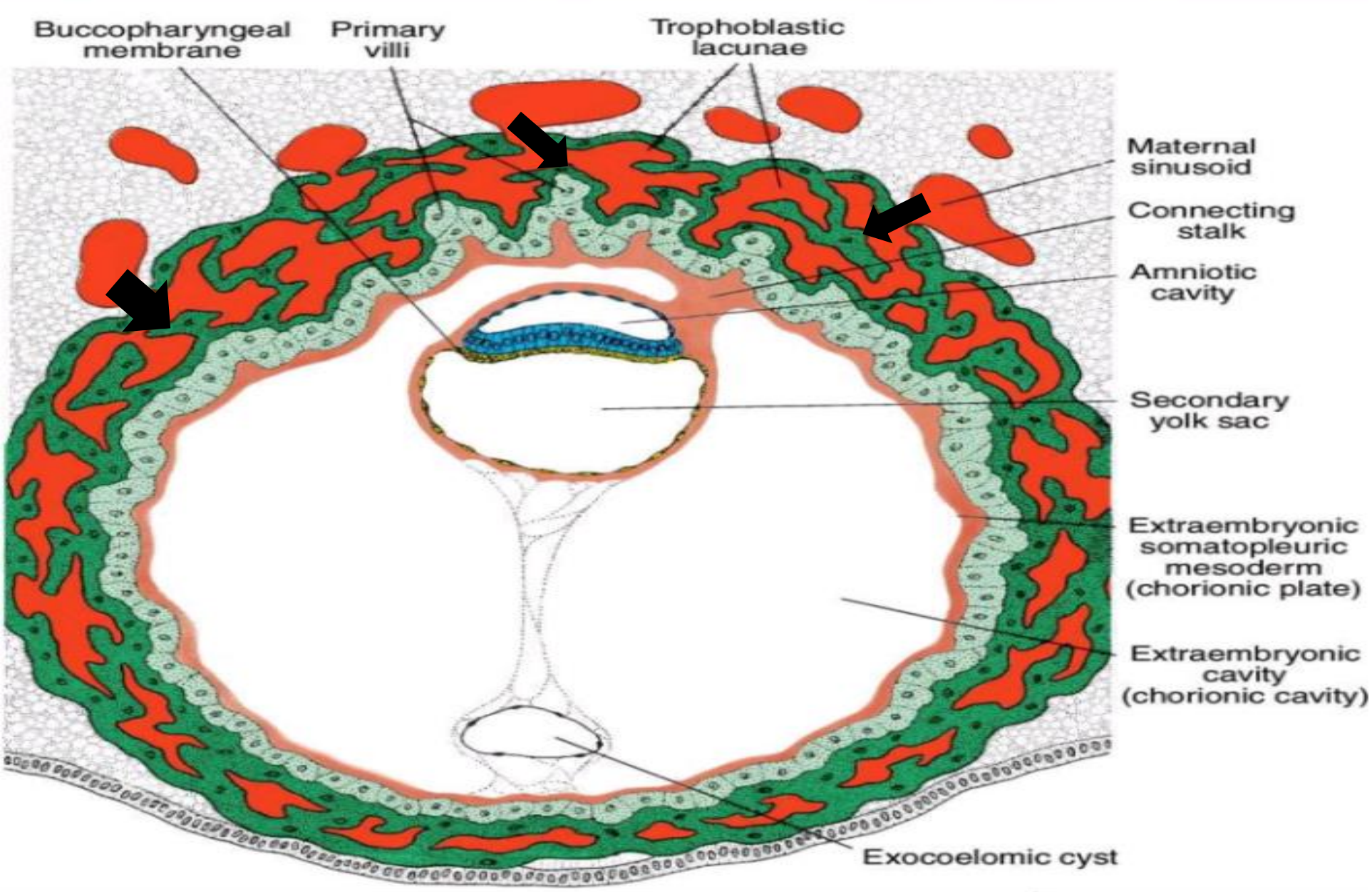

Uteroplacental circulation

4- Extra-embryonic mesoderm and extraembryonic cavity

- Cells derived from the yolk sac appears between the inner surface of the cytotrophoblasts and the outer surface of the yolk sac cavity , these cells form the *extra-embryonic (primary) mesoderm*.
- They fill the space between the trophoblasts, the amnion and yolk sac cavities.

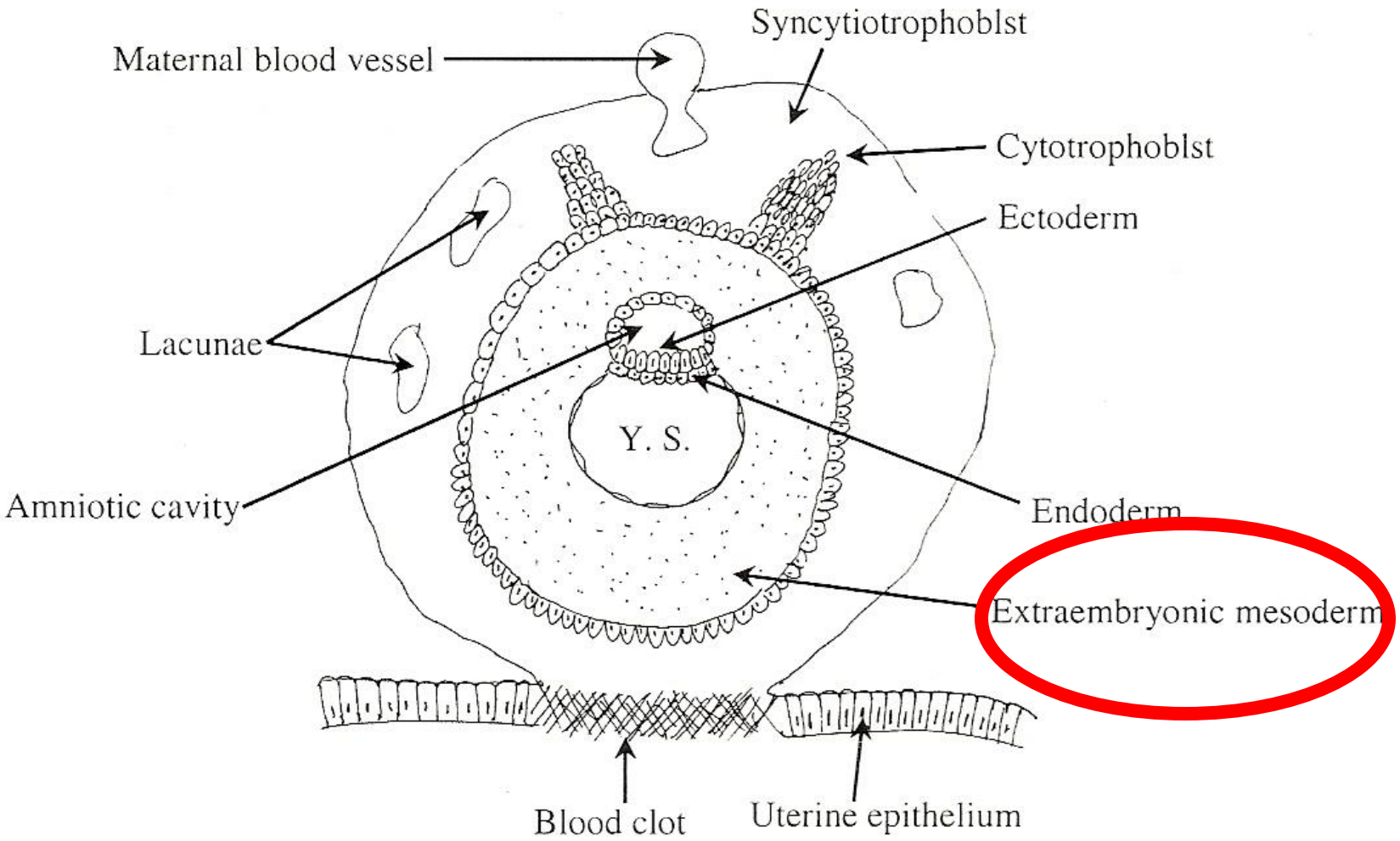

THE EXTRA-EMBRYONIC MESODERM

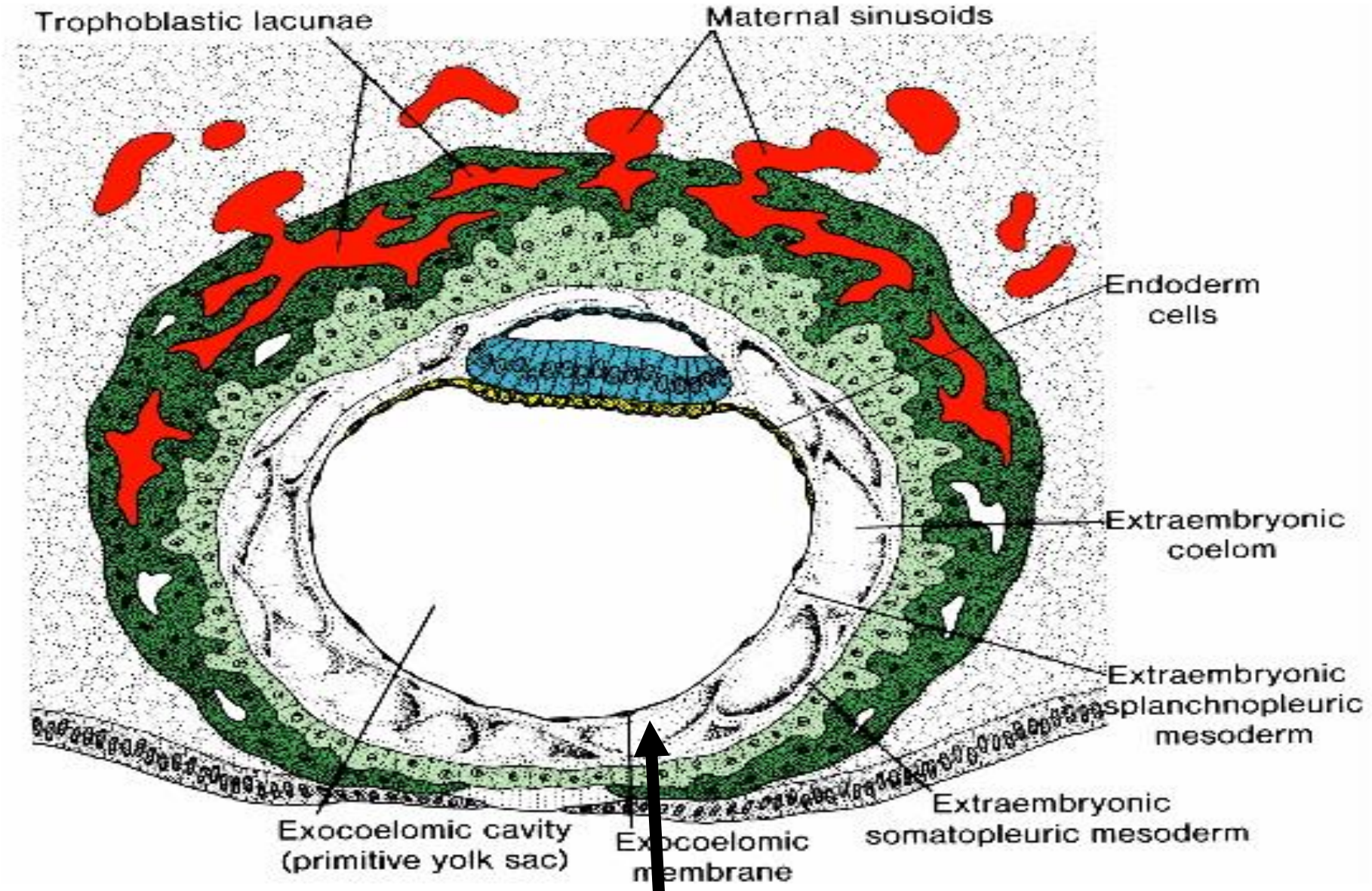

THE EXTRA-EMBRYONIC MESODERM

4- Extra-embryonic mesoderm and extraembryonic cavity

- Large spaces develop in the extraembryonic mesoderm and coalesce to form extraembryonic cavity ***chorionic cavity***.
- It surrounds the primitive yolk sac and amniotic cavity except where the germ disc is connected to the trophoblasts by the *connecting* *stalk* or *body stalk*.

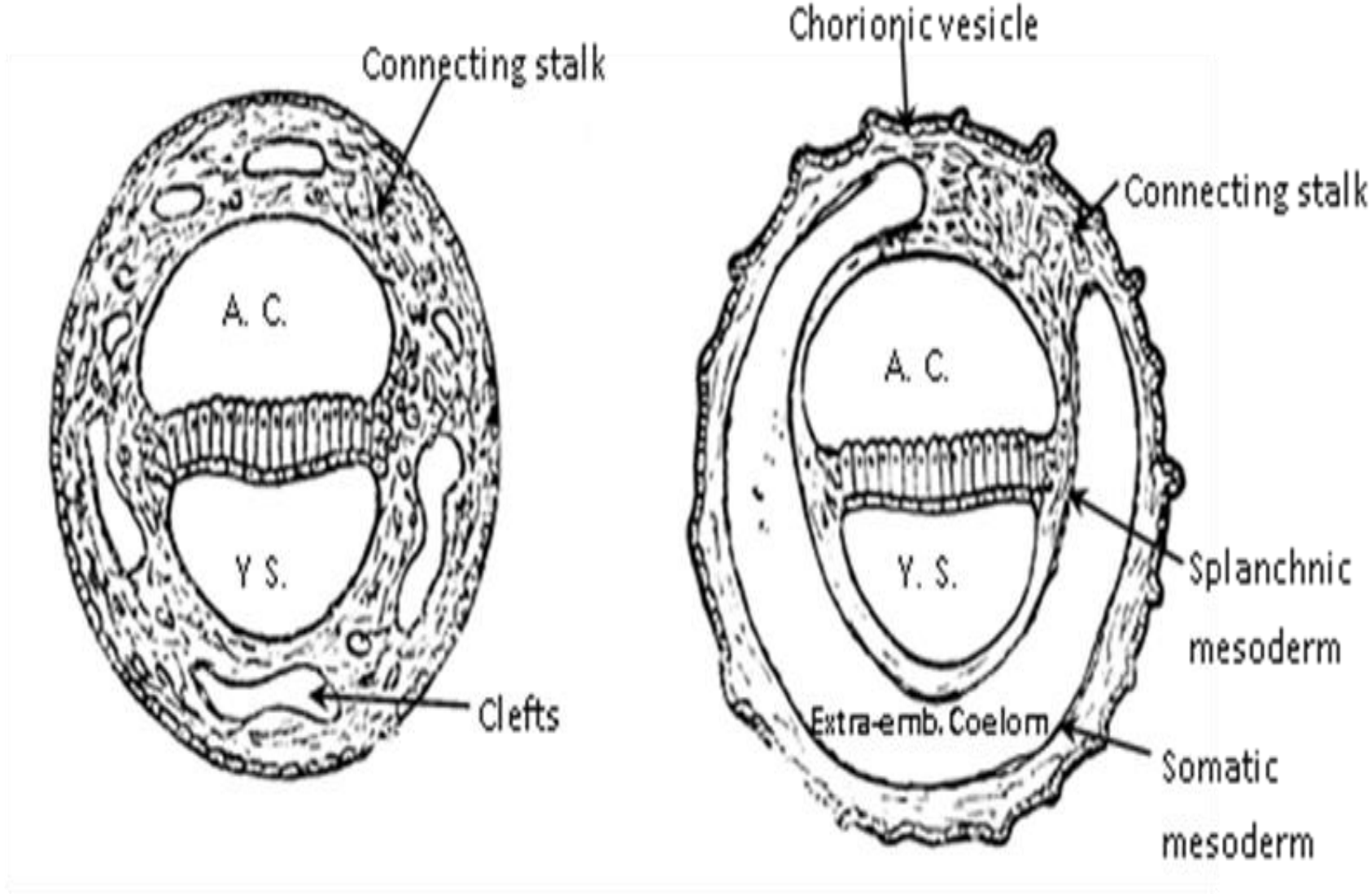

Fig. 36: Formation of the extra-embryonic coelom.

4- EXTRA-EMBRYONIC MESODERM AND EXTRAEMBRYONIC CAVITY

➢The extraembryonic cavity (chorionic cavity)divides the extraembryonic mesoderm into :

1/ extraembryonic **somatopleuric mesoderm :** (lines the trophoblast, and covers the amnion).

2/ extraembryonic **splanchnopleuric mesoderm:** (covers the yolk sac).

➢-Extraembryonic somatic mesoderm, cytotrophoblast, and syncytiotrophoblast constitute the chorion.

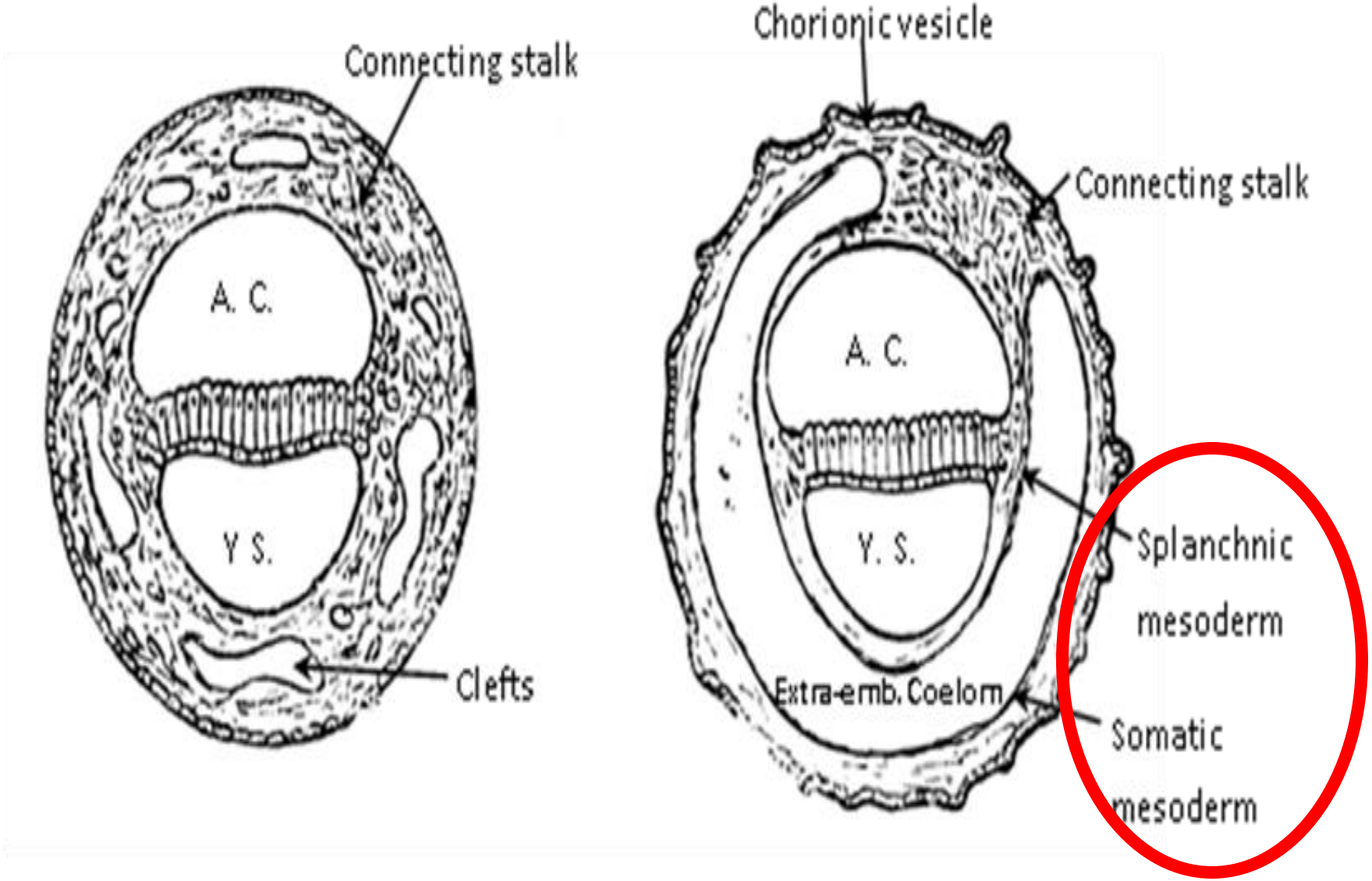

Fig. 36: Formation of the extra-embryonic coelom.

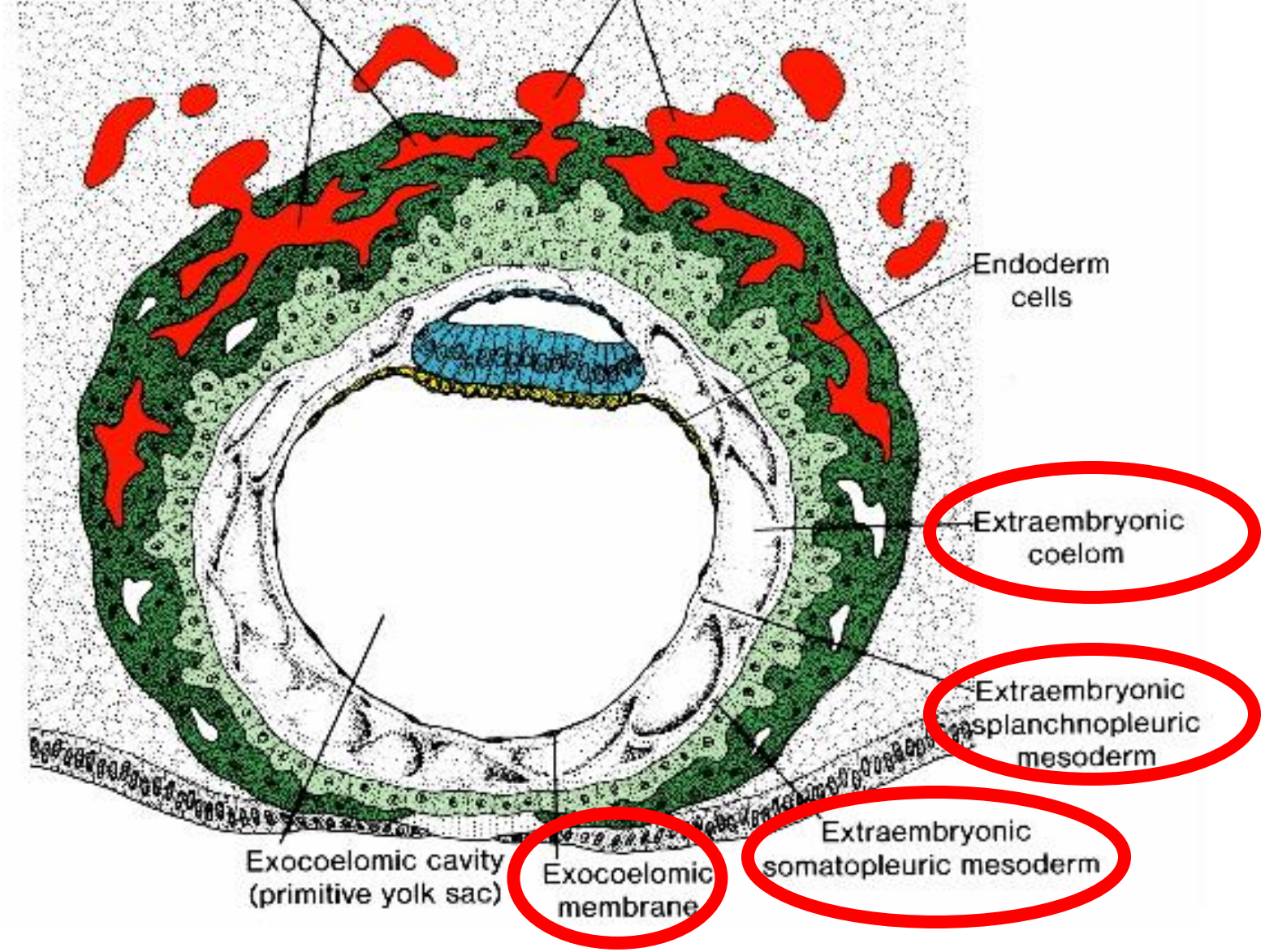

Figure 3.4 Human blastocyst of approximately 12 days. The trophoblastic lacunae at the embryonic pole are in open connection with maternal sinusoids in the endometrial stroma. Extraembryonic mesoderm proliferates and fills the space between the exocoelomic membrane and the inner aspect of the trophoblast.

5- DECIDUA REACTION

- occurs initially at site of implantation and includes both cellular and matrix changes reaction spreads throughout entire uterus.
- The endometrium has undergone changes cells have become filled with glycogen and lipids the nutrients spill into the connective tissue .

- The endometrium becomes the decidua and forms 3 distinct anatomical regions (at approximately 3 weeks) :

1/ Decidua Basalis : at implantation site .

2/ Decidua Capsularis : enclosing the conceptus .

3/ Decidua Parietalis : the remainder of uterus.

SUMMARY

1- Trophoblast completely embedded .

2- Blastocyte slightly protrude to lumen .

3- Uteroplacental circulation establish .

4- Formation of the extra-embryonic mesoderm and extra-embryonic cavity (*chorionic cavity*) .

5- Decidua reaction .

DAY 13

❖ **Major events :**

1- Surface defect completely healed .
2- Formation of the Primary villi .
3- Formation of the Secondary yolk sac or definitive yolk sac .
4- Excoelomic cyst .
5- Connecting stalk .

1- SURFACE DEFECT COMPLETELY HEALED

- Bleeding occur due to implantation site at day 28 of menstruation called false menstruation .
- Lead to false estimation of date of delivery .

2- PRIMARY VILLI

- **Primary villi:**

  The cytotrophoblast is cellular and expands mitotically into the syncytiotrophoblast to form primary chorionic villi.

- Cells from these villi can be removed for early genetic testing for the fetus (chorionic villus sampling).

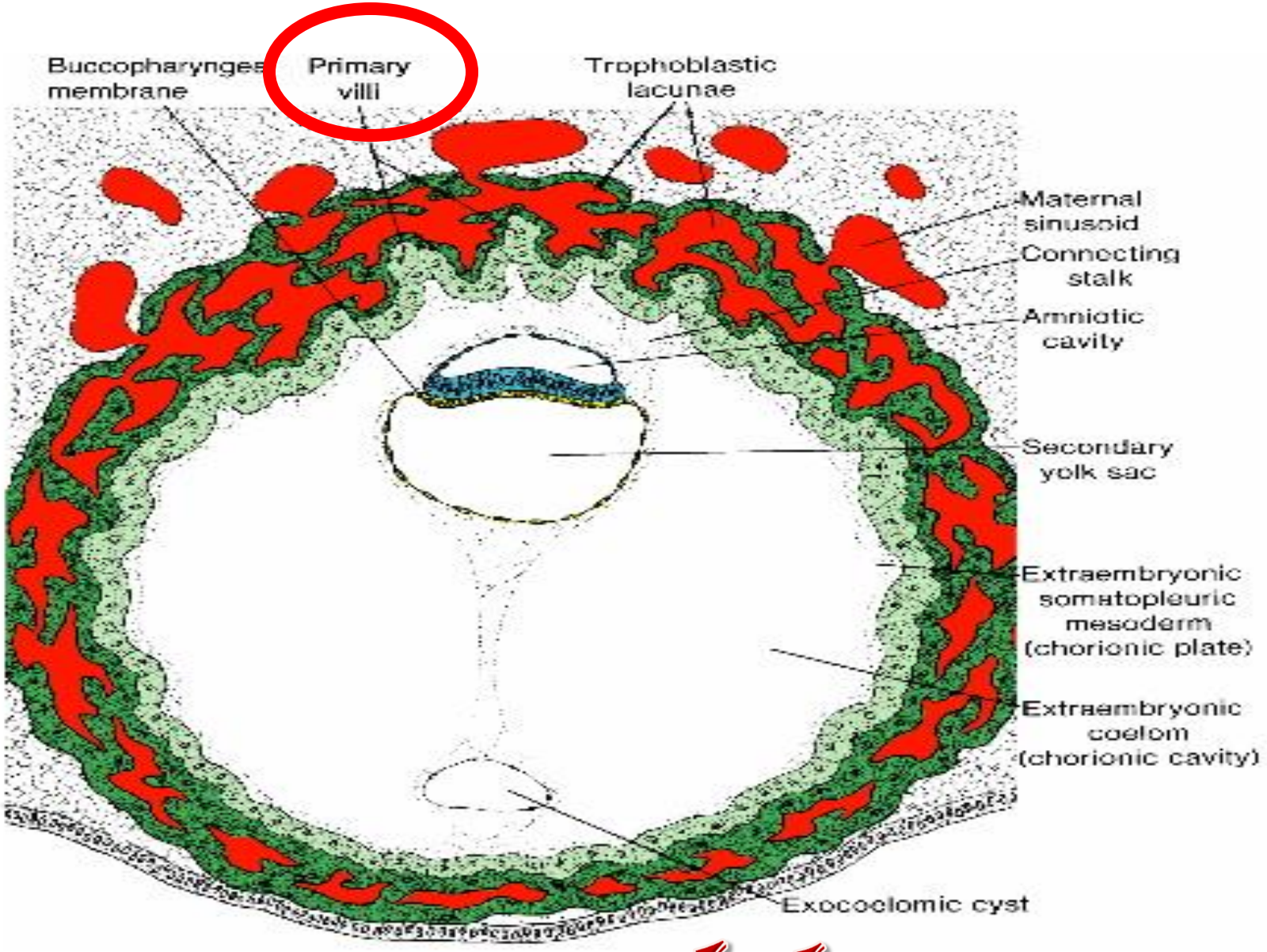

PRIMARY VILLI

3- Secondary Yolk Sac

- The hypoblast will form a new cellular layer lining the inside of the exocoelomic membrane, forming a cavity called secondary or definitive yolk sac.

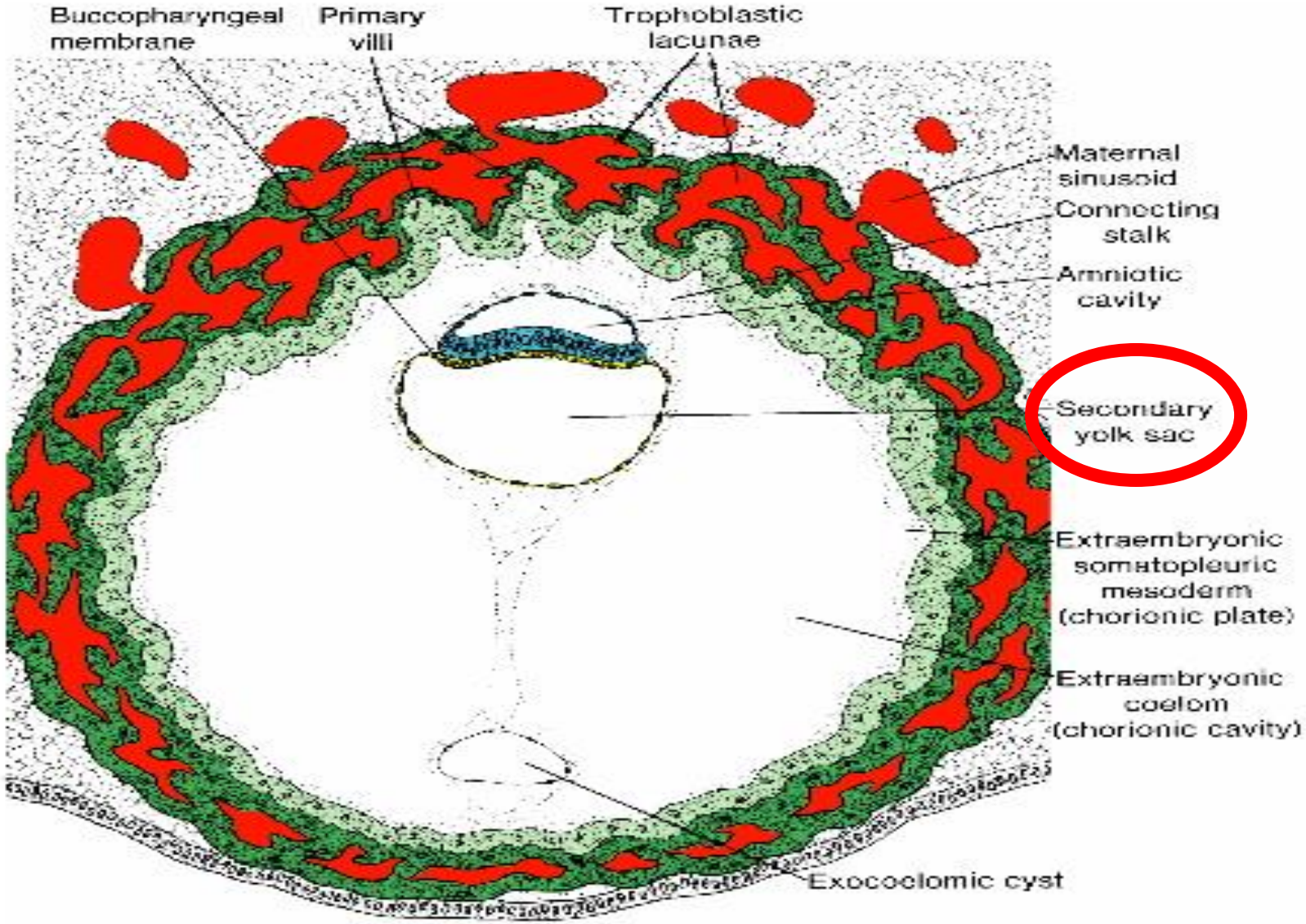

SECONDARY YOLK SAC

4-EXOCOELOMIC CYST

- Exocoelomic membrane lining the exocoelomic cavity is largely pinched off forming the exocoelomic cysts that are often seen floating in the chorionic cavity.

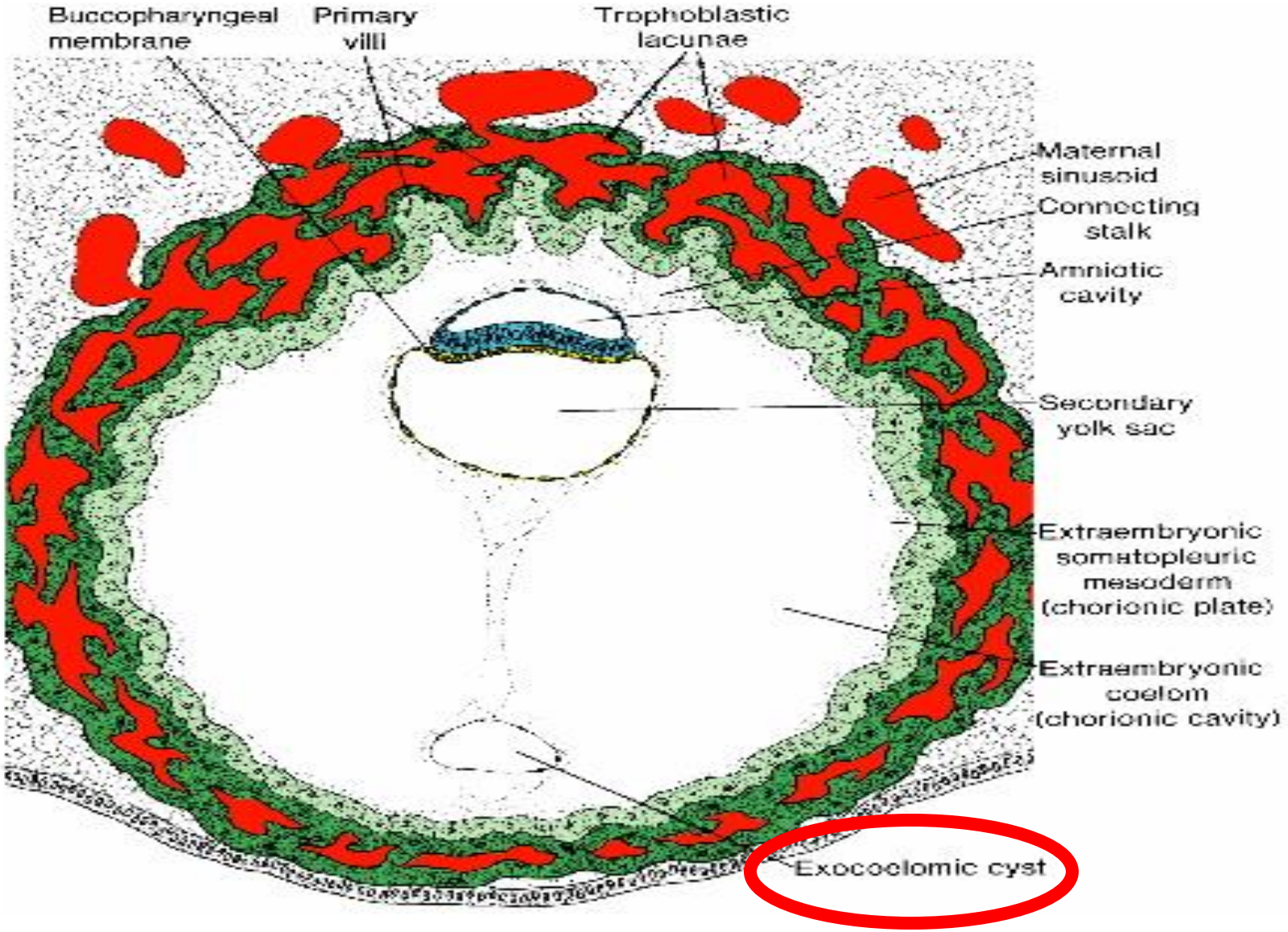

EXCOELOMIC CYST

5- CONNECTING STALK

- Extraembryonic somatic mesoderm also forms the connecting stalk that is the primordium of the umbilical cord.
- The amniotic cavity and yolk sac are suspended in the chorionic cavity by the connecting stalk.

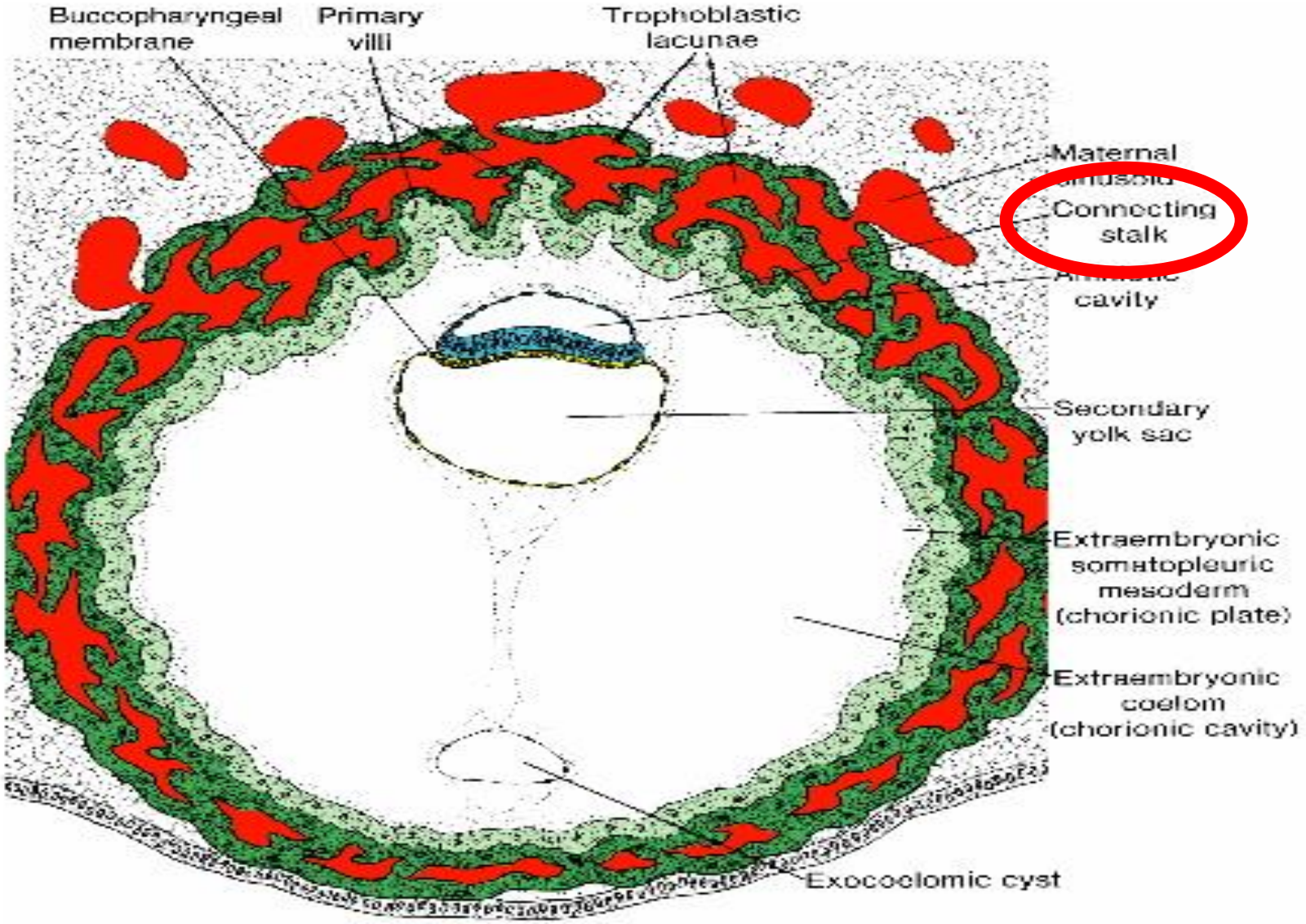

CONNECTING STALK

SUMMERY

1- Surface defect completely healed .

2- formation of the Primary villi .

3- Formation of the Secondary yolk sac or definitive yolk sac .

4- Excoelomic cyst .

5- Connecting stalk .

- *At the end of the second week it is possible to distinguish the dorsal (amniotic cavity) from the ventral (yolk sac) of the embryo.*

CLINICAL APPLICATION:

❖EARLY PREGNANCY TESTING:

HCG detected in maternal blood or urine as early as day 10 of pregnancy and is the basis for pregnancy tests.

CLINICAL APPLICATION

❖Hydatidiform mole :

- Haploid sperm fertilizing an egg without a female pronucleus. This evidence is derived from the fact that while cells of moles are diploid, their entire genome is paternal.
- only the conceptus trophoblast layers proliferates and not the embryoblast, no embryo develops (Pregnancy with little or no embryonic tissue).
- Moles secrete high levels of hCG (but may be normal) and may produce **choriocarcinoma**.
- Prenatal diagnosis by ultrasound analysis demonstrates the absence of embryo .
- Following a first molar pregnancy, there is approximately a 1% risk of a second molar pregnancy.

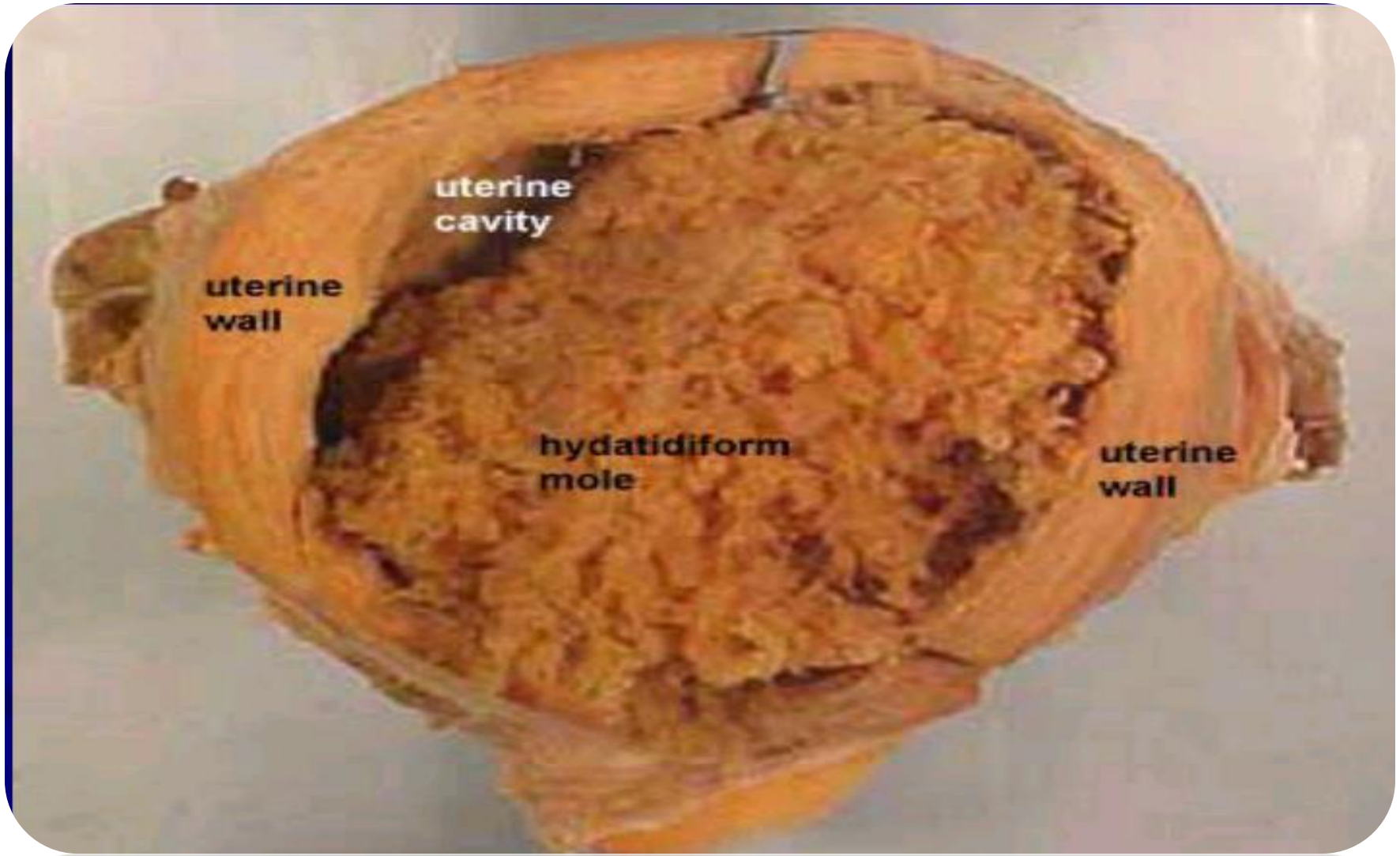

HYDATIDIFORM MOLE

CLINICAL APPLICATION

- Functional differences : genetic diseases depend on whether the defective or missing gene is inherited from the father or the mother.
- Examples :

- Deletion on chromosome 15 from a father produces Prader-Willi syndrome.
- If from the mother results in Angelman syndrome .

Angelman syndrom



Angelman Syndrome is a rare neurological disorder disorder characterized by severe congenital mental retardation, unusual facial appearance, and muscular abnormalities



pws





SUMMARY

The second week of development is the week of twos, because of the following:

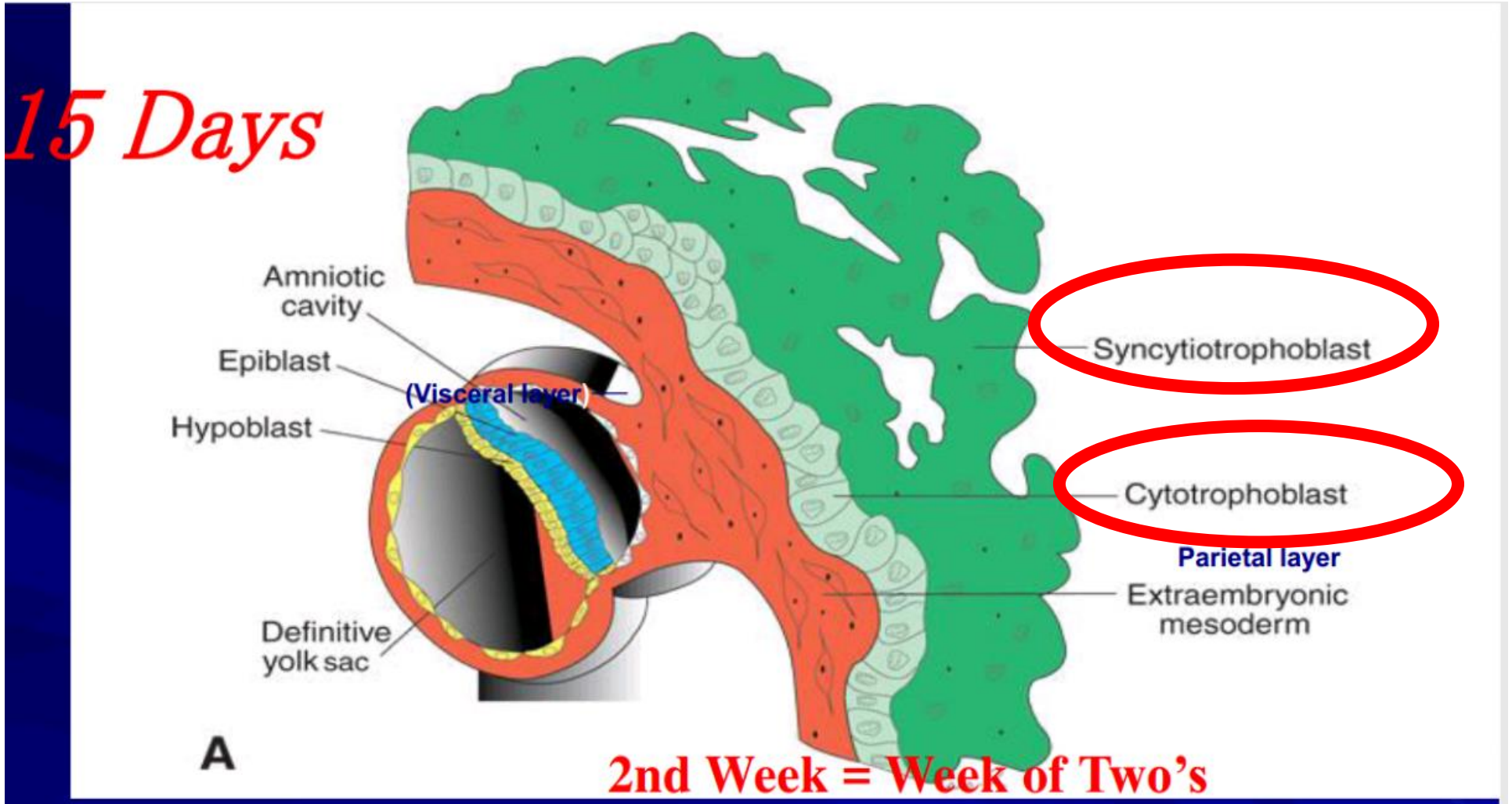

SUMMARY

The second week of development is the week of twos, because of the following:

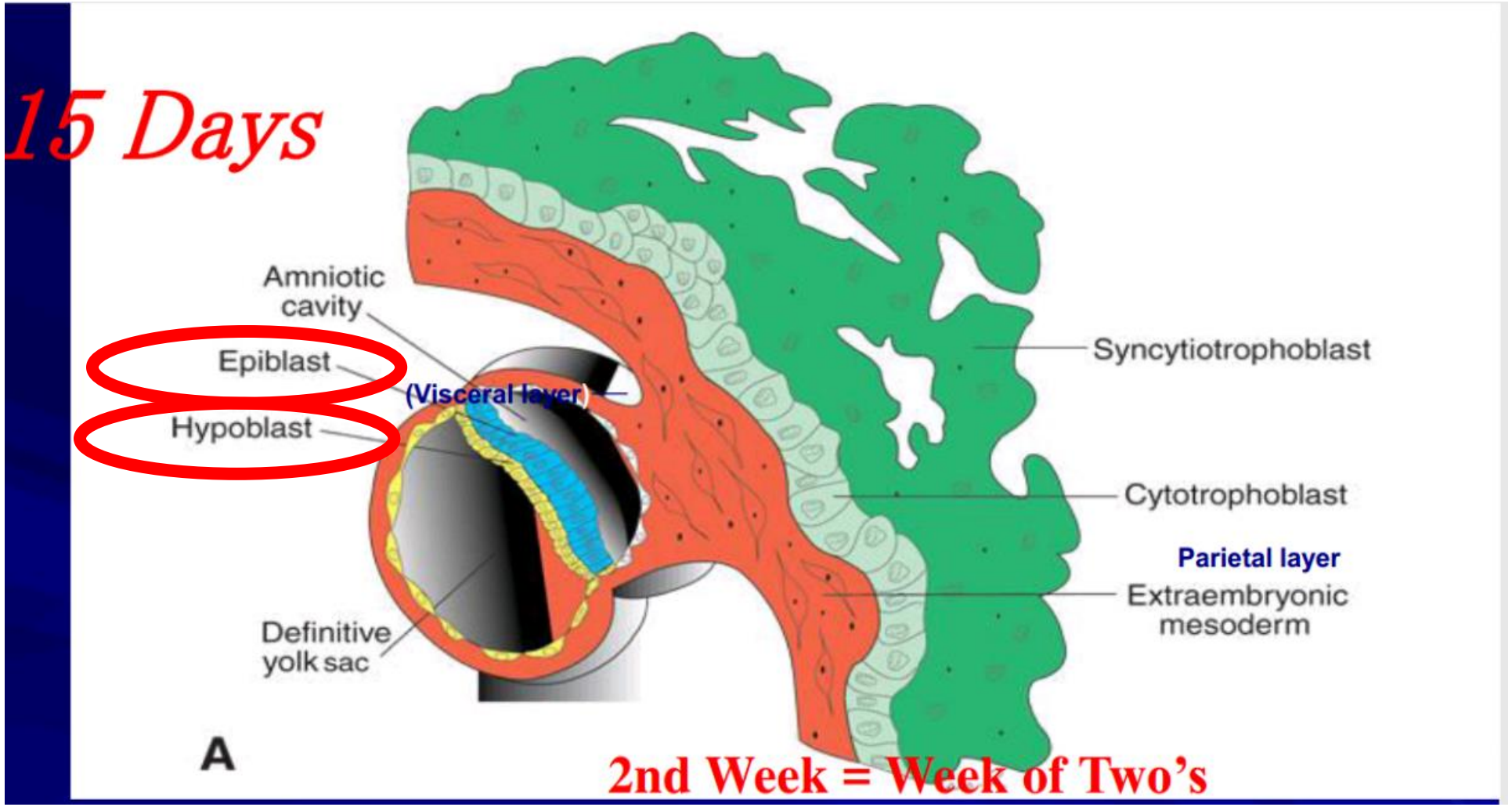

SUMMARY

The second week of development is the week of twos, because of the following:

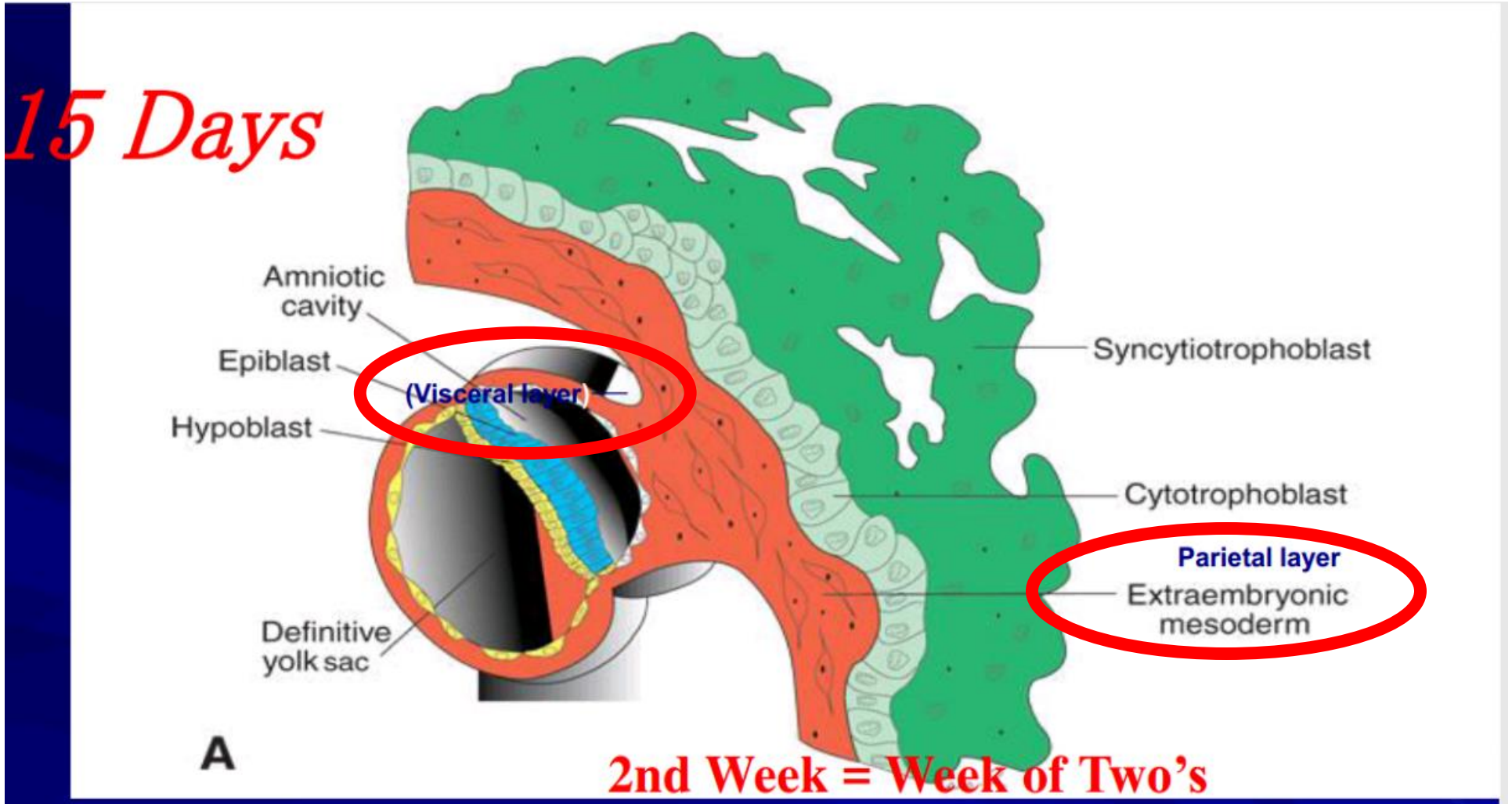

SUMMARY

The second week of development is the week of twos, because of the following:

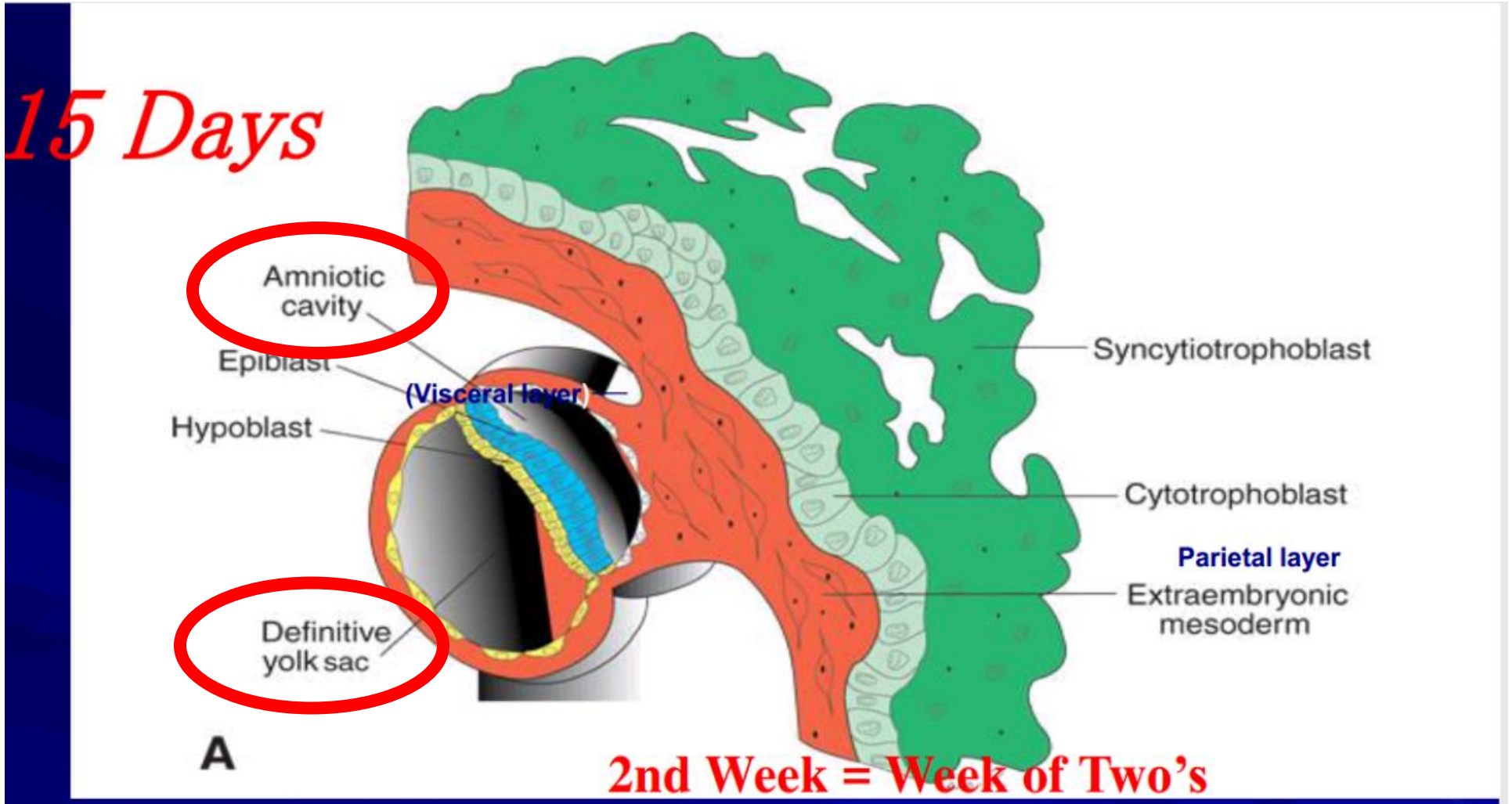

Thank You