Histology of Cartilage

- Cartilage is a specialized form of connective tissue characterized by an **extracellular matrix (ECM)** and cells called **chondrocytes.**

- Chondrocytes synthesize and secrete the ECM and the cells themselves are located in matrix cavities called **lacunae.**

- Collagen, hyaluronic acid, proteoglycans, and small amounts of several glycoproteins are the principal macromolecules present in all types of cartilage matrix.

- It is strong, flexible, and firm consistency due to firm extracellular matrix.
- It is avascular and is nourished by the diffusion of nutrients from capillaries in adjacent connective tissue (perichondrium) or by synovial fluid from joint cavities.
- It contains chondrocytes embedded in the matrix.
- It has no lymphatic vessels or nerves.
- Because cartilage is devoid of blood capillaries, chondrocytes metabolize glucose mainly by anaerobic glycolysis. Nutrients from the blood diffuse from the perichondrium to reach the deeper chondrocytes. Transport of water and solutes in the matrix is promoted by the pumping action of intermittent cartilage compression and decompression.

Functions

1. Support soft tissues
2. Shock-absorbing and sliding area for joints and facilitates bone movements
3. Essential for the development and growth of long bones both before and after birth
4. Allows the tissue to bear mechanical stresses without permanent distortion
5. Sliding area for joints and facilitates bone movements

Cartilage can grow by two mechanisms

- Appositional growth:

chondroblasts in perichondrium differentiate into chondrocytes, start producing matrix, and add to existing cartilage

- Interstitial growth:

proliferation and hypertrophy of existing chondrocytes

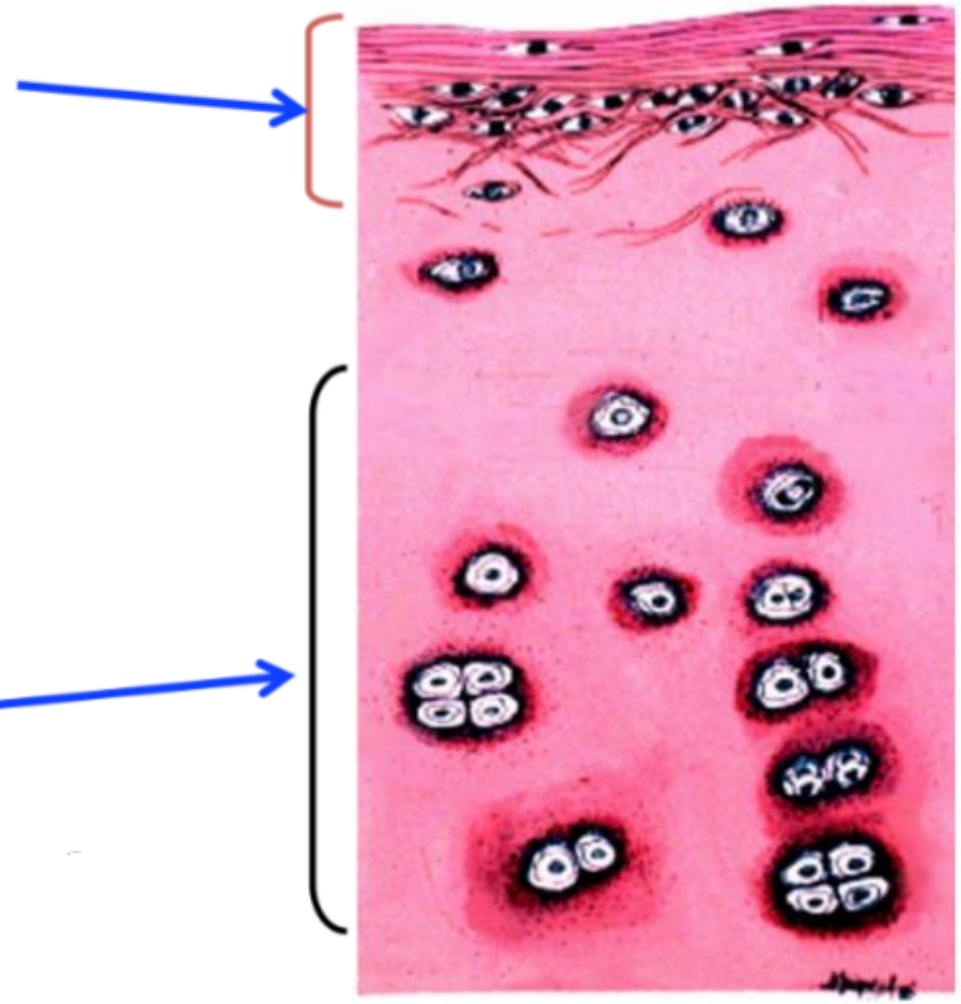

Cartilage cells

1. Chondroblasts:

- These cells are extremely important in chondrogenesis due to their role in forming both the Chondrocytes and cartilage matrix which will eventually form cartilage.
- These cells contain an extensive Golgi complex, abundant rough endoplasmic reticulum (RER), lipid droplets, and glycogen.

2- Chondrocytes:

- Mature cartilage cells that are embedded within lacunae in the matrix.

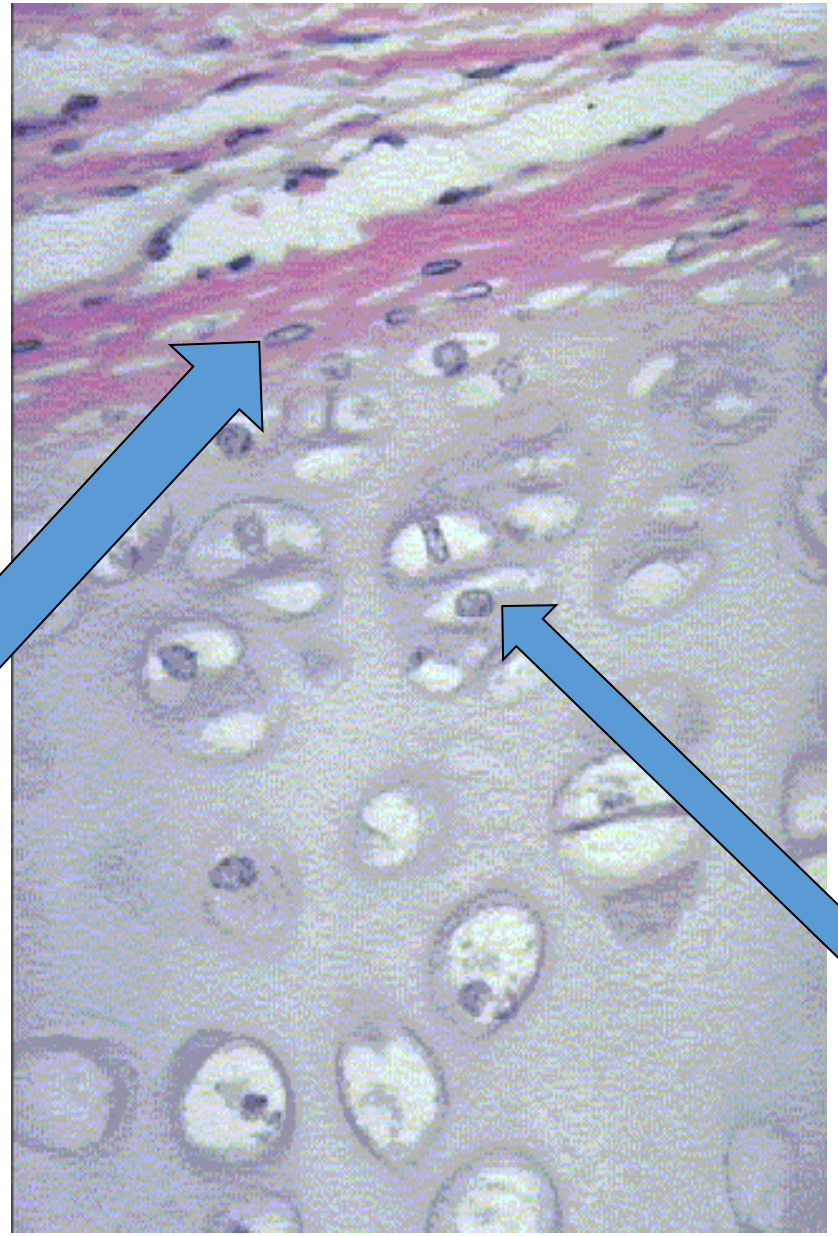

Chondroblasts

Chondrocytes

Matrix

- It is composed of an amorphous ground substance containing proteoglycan and chondronectin, in which type II collagen is embedded.

- Matrix that is adjacent to chondrocytes is called the territorial matrix. This part of the matrix is poor in collagen but rich in proteoglycans.

Perichondrium

- It is a sheath of dense connective tissue that surrounds cartilage in most places except at articular surfaces, forming an interface between the cartilage and the tissue supported by the cartilage. The perichondrium gives the vascular supply for the avascular cartilage and also contains nerves and lymphatic vessels.
- **It consists of**

1. Outer fibrous layer containing type I collagen, fibroblasts, and blood vessels.
2. Inner cellular (chondrogenic) layer containing chondrogenic cells and chondroblasts.

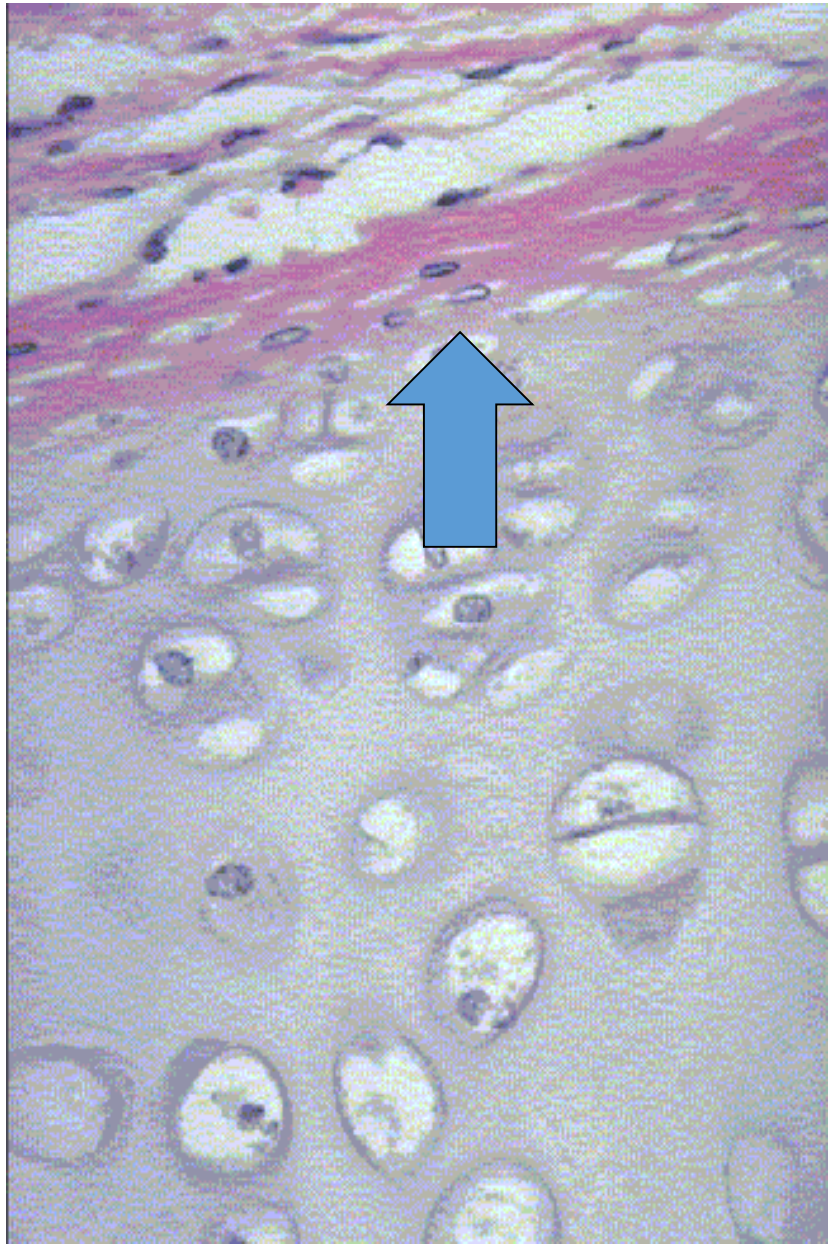

Perichondrium

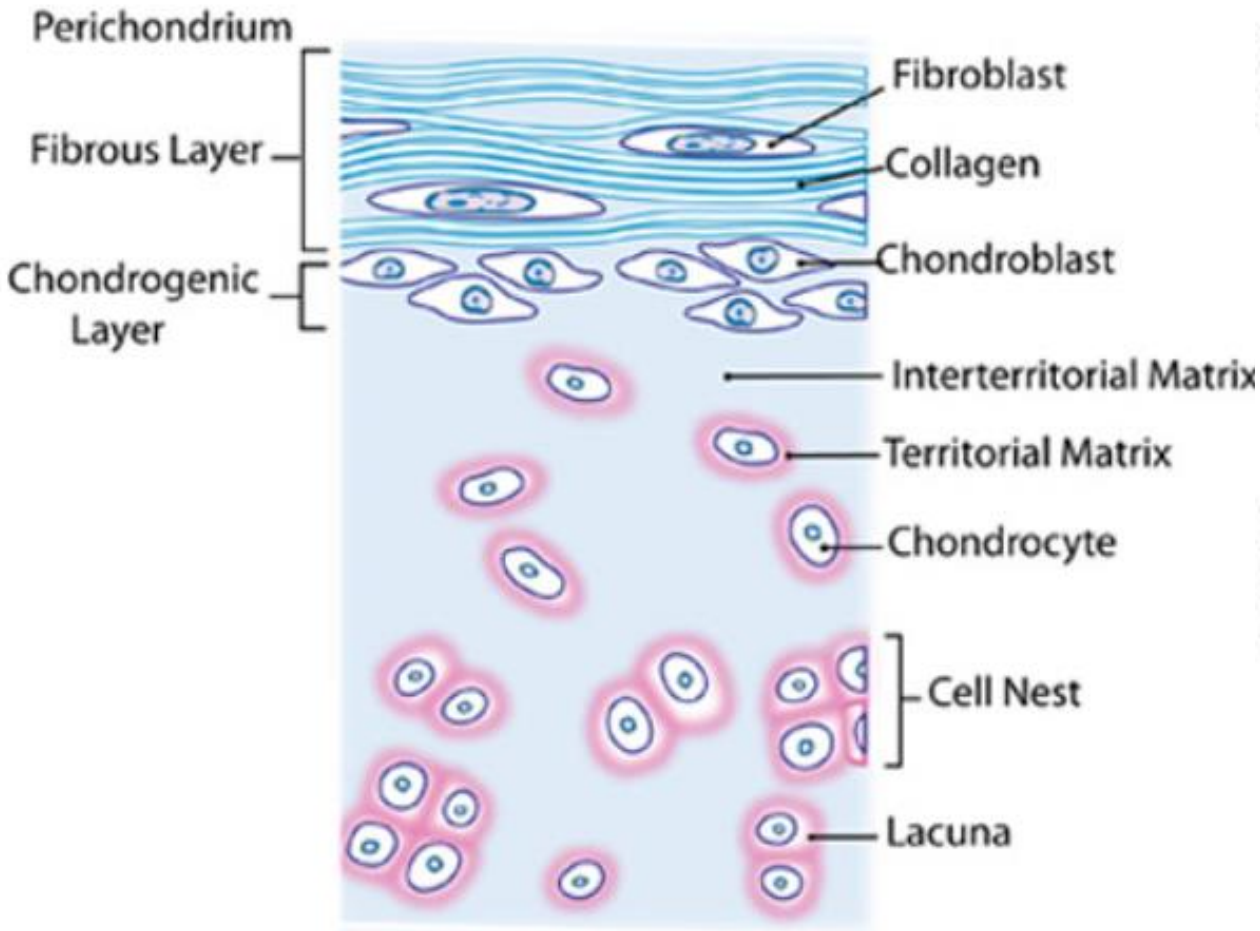

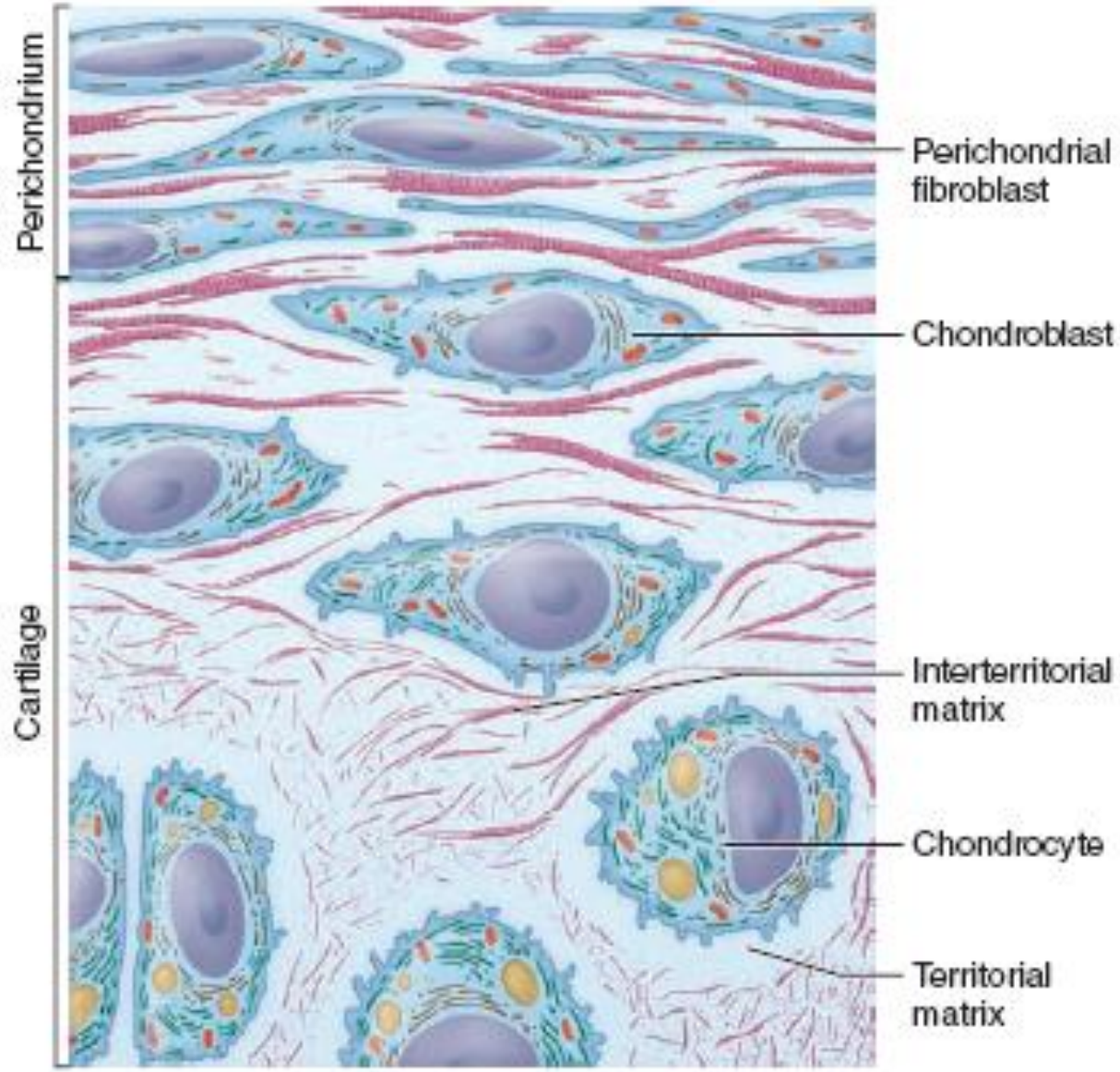

Hyaline cartilage- magnified

Hyaline cartilage- magnified

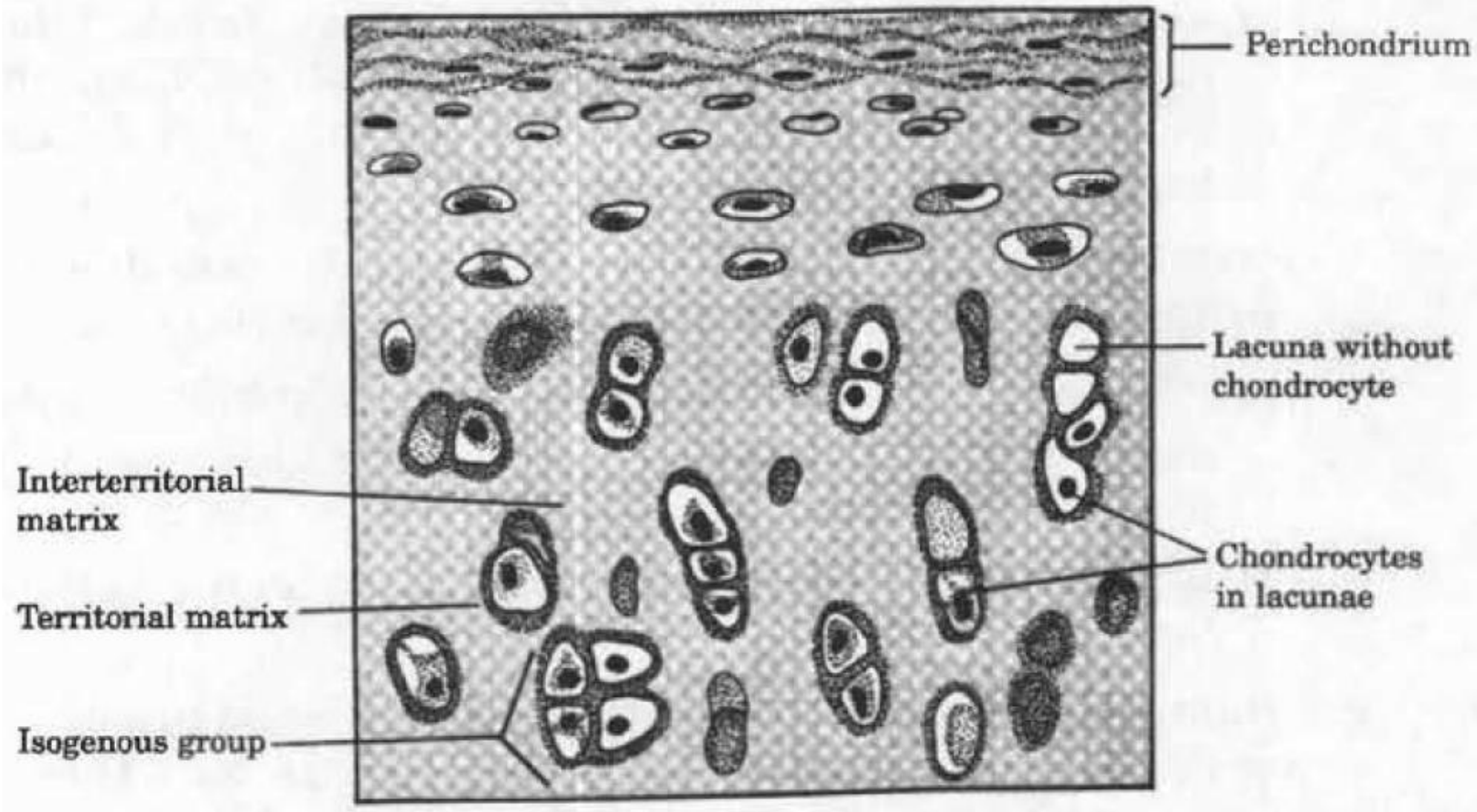

Hyaline cartilage- magnified

Types of cartilages

1. Hyaline cartilage
2. Elastic cartilage
3. Fibrocartilage

1. Hyaline cartilage

- Hyaline cartilage is the most abundant cartilage and serves as a temporary skeleton in the fetus until it is replaced with bone.

- Hyaline cartilage is located in the articular surfaces of the movable joints (articular cartilage), in the walls of larger respiratory passages (nose, larynx, trachea, bronchi), in the ventral ends of ribs (costal cartilage) and in the **epiphyseal plate,** where it is responsible for the longitudinal growth of bone.

Articular cartilage:

- It is type of hyaline cartilage, white and smooth and covers the ends of bones in joints.

- It is has no perichondrium.

- Articular hyaline cartilage does not repair quickly, slow to recover from damage due to its avascularity and fibroblasts may proliferate and form a scar, preventing complete regeneration of the cartilage.

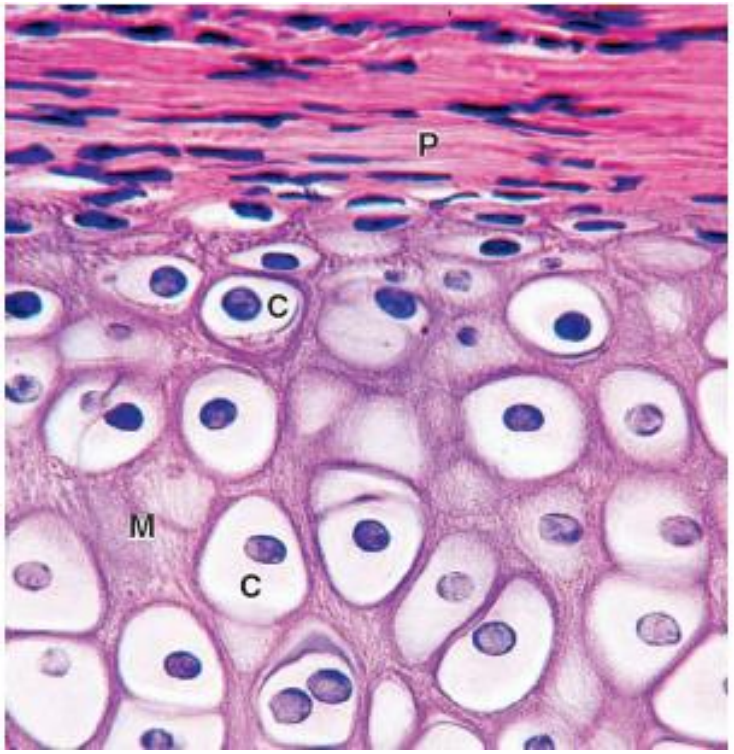

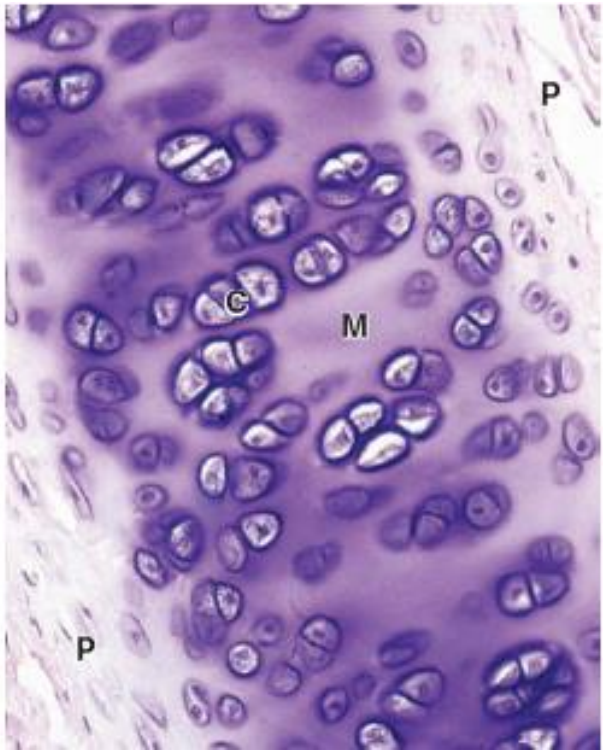

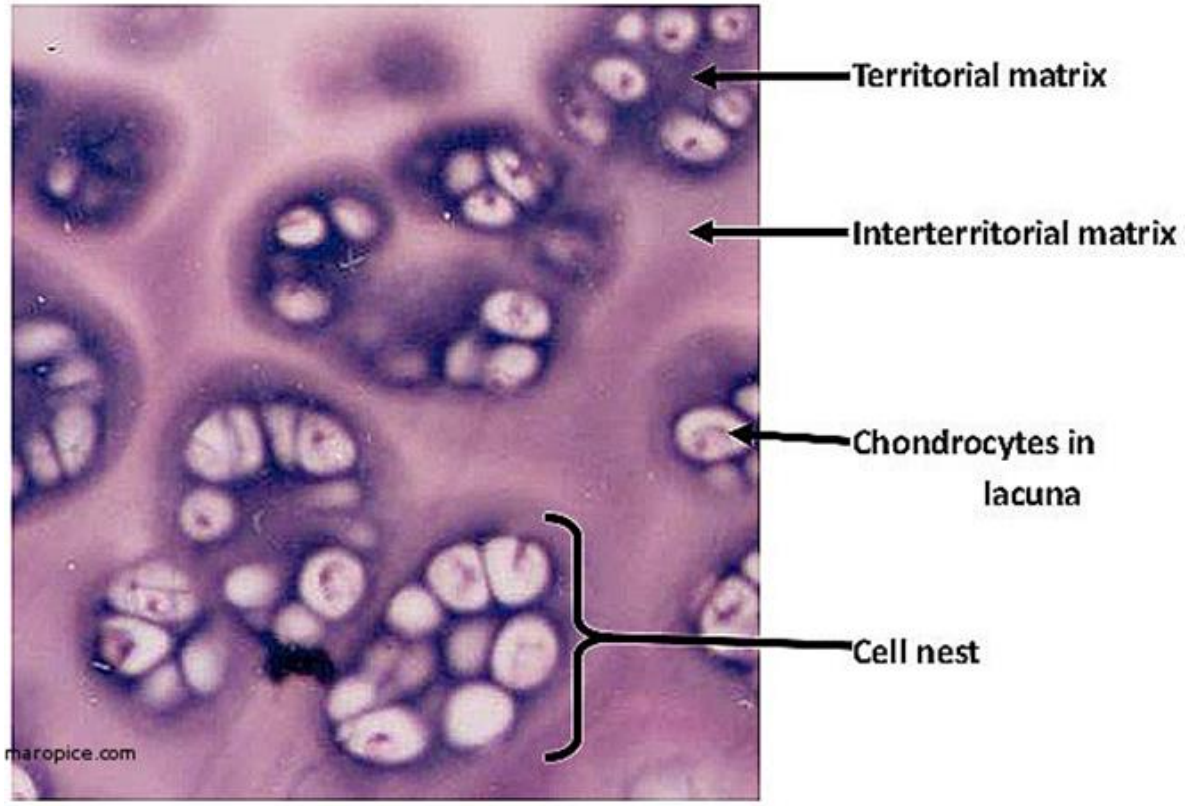

Hyaline cartilage

2. Elastic (yellow) cartilage

- It contains elastic fiber networks and collagen fibers type II.
- The principal protein is elastin.
- Elastic cartilage is histologically similar to Hyaline cartilage but contains many yellow elastic fibers lying in a solid matrix.
- These fibers give elastic cartilage great flexibility so that it is able to withstand repeated bending.
- The chondrocytes lie between the fibres.
- Present in the outer ear, Eustachian tube and epiglottis.

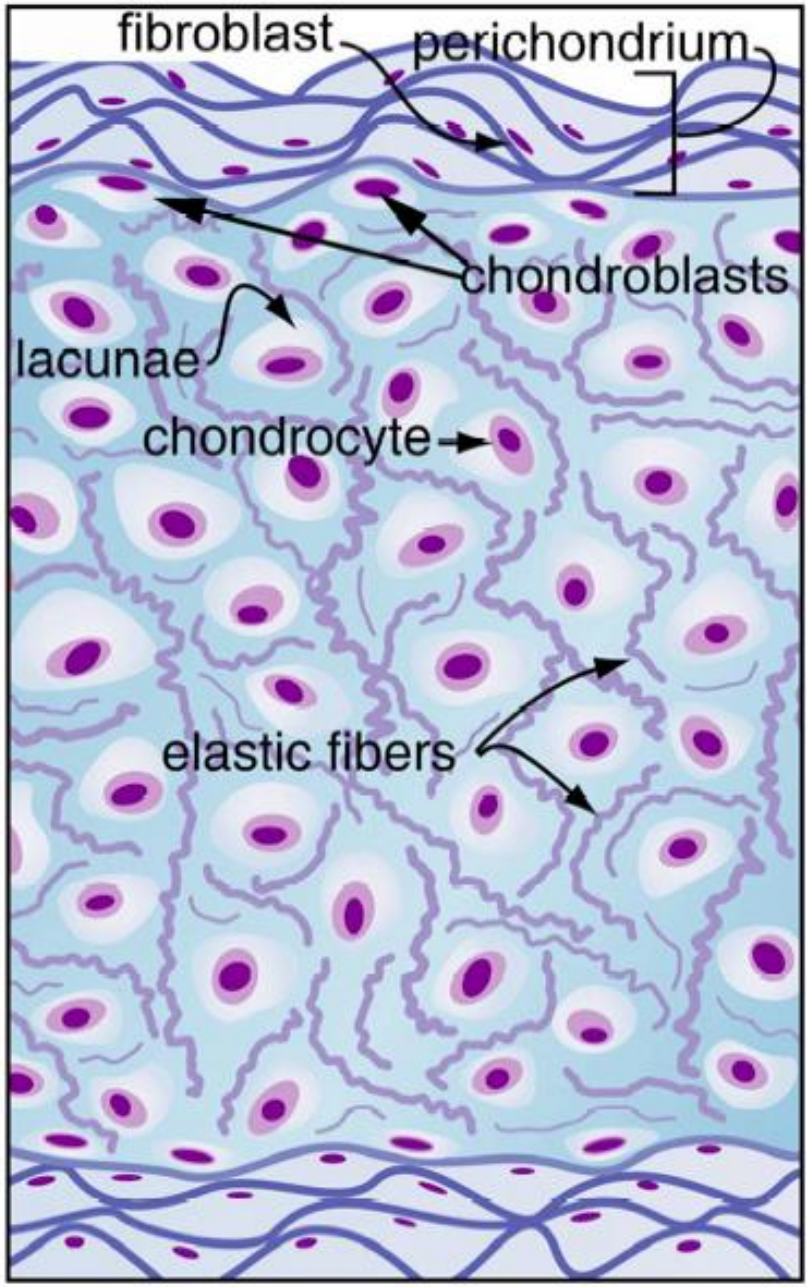

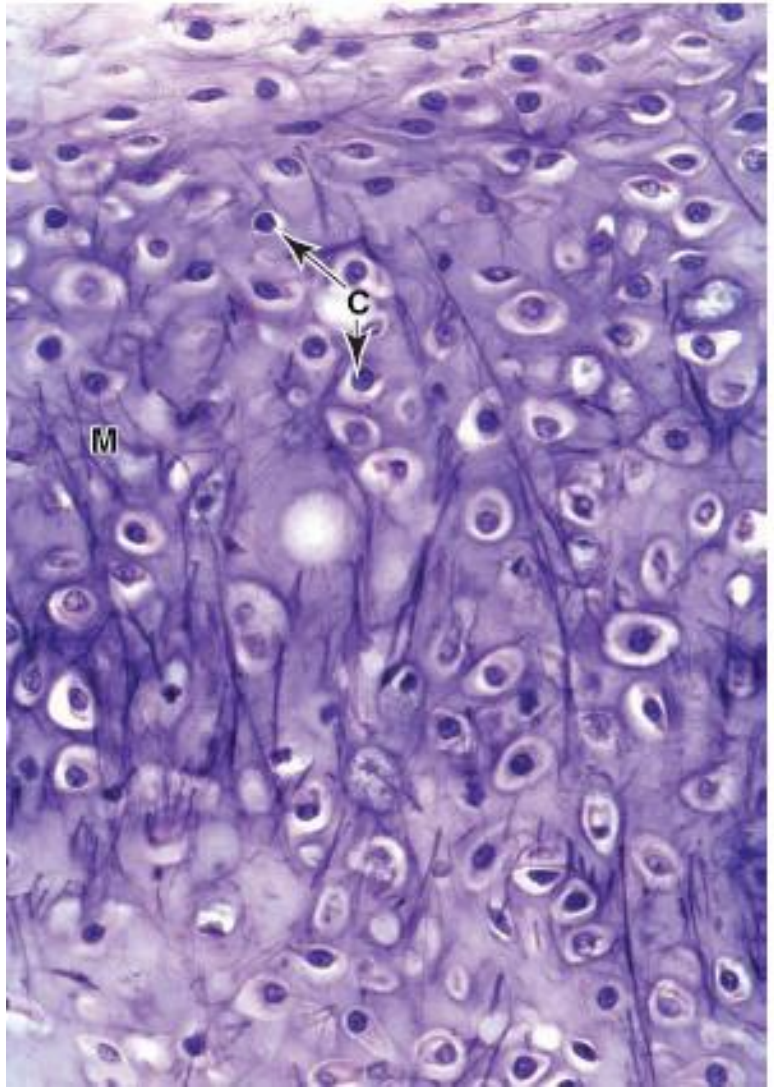

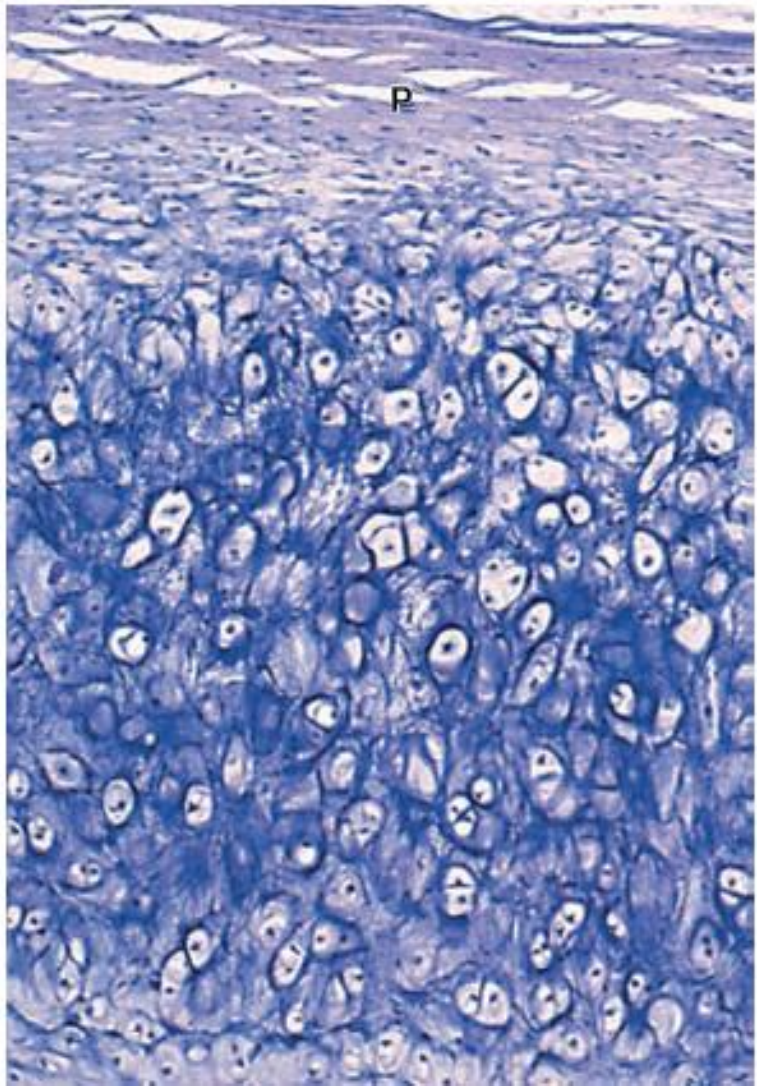

Elastic cartilage

3. Fibrocartilage

- Lacks an identifiable perichondrium.
- It is characterized by alternating rows of fibroblast.
- Has a matrix with large amounts of collagen.
- It is the only type of cartilage that contains type I collagen.
- Chondrocytes surrounded by scant matrix and thick parallel bundles of type I collagen fibers.
- Fibrocartilage is located in areas where support and tensile strength are required.
- Fibrocartilage is found in the symphysis pubis, intervertebral discs, articular discs, and menisci of knee.

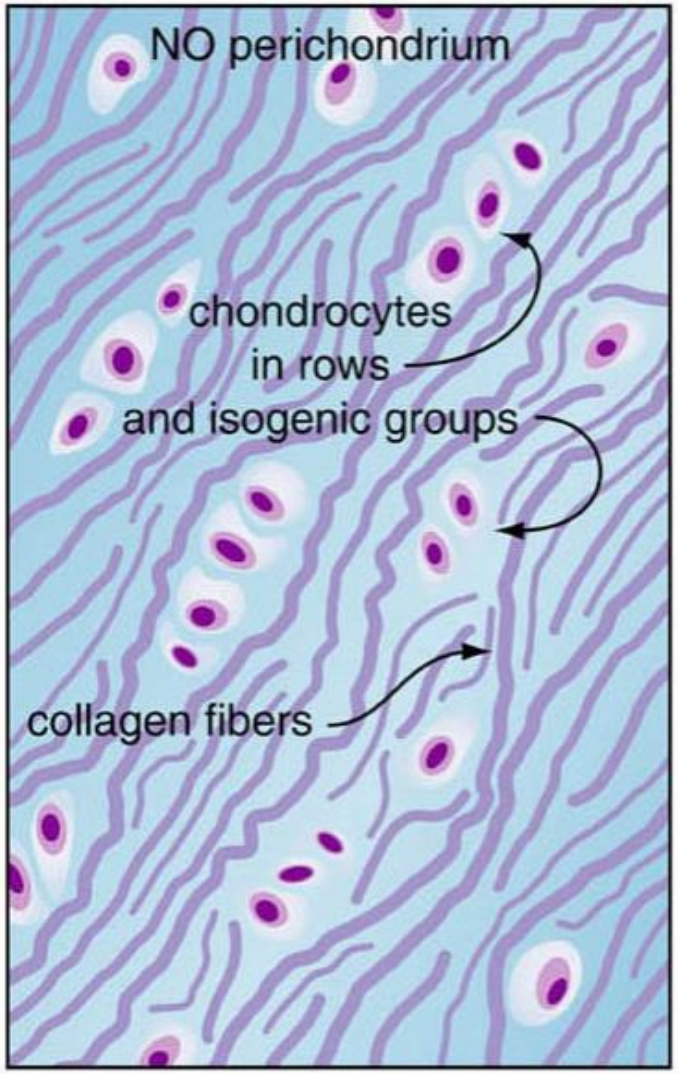

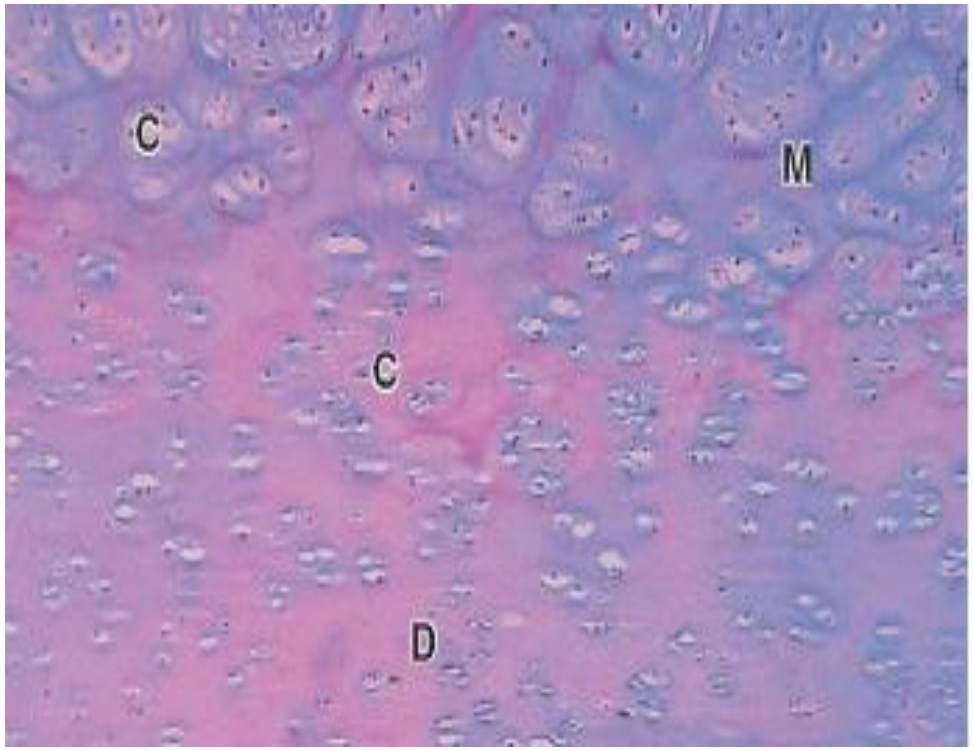

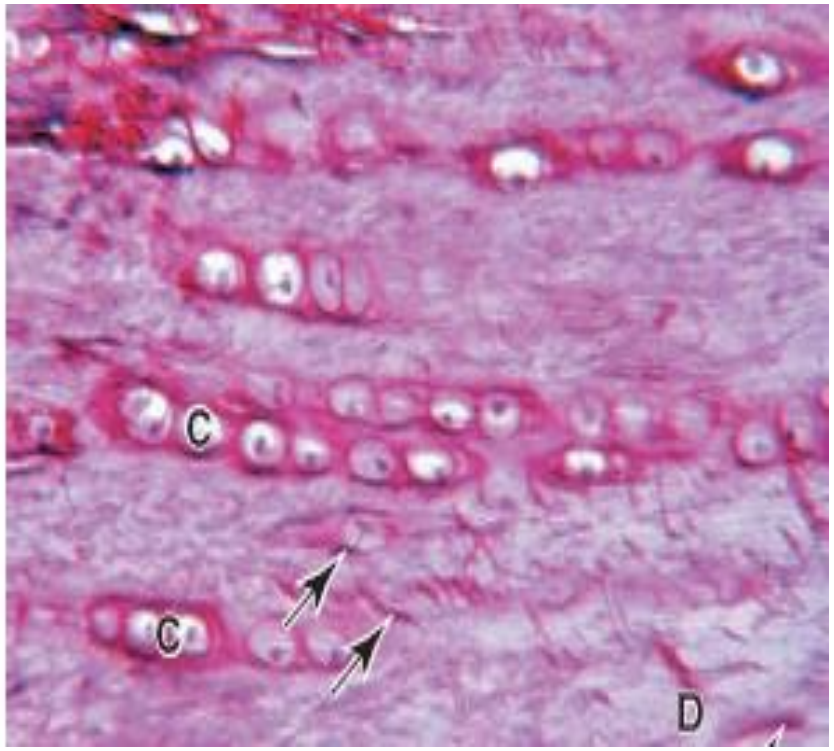

Fibrocartilage

	Hyaline Cartilage	Elastic Cartilage	Fibrocartilage
Main features of the extracellular matrix	Homogeneous, with type II collagen and aggrecan	Type II collagen, aggrecan, and darker elastic fibers	Type II collagen and large areas of dense connective tissue with type I collagen
Major cells	Chondrocytes, chondroblasts	Chondrocytes, chondroblasts	Chondrocytes, fibroblasts
Typical arrangement of chondrocytes	Isolated or in small isogenous groups	Usually in small isogenous groups	Isolated or in isogenous groups arranged axially
Presence of perichondrium	Yes (except at epiphyses and articular cartilage)	Yes	No
Main locations or examples	Many components of upper respiratory tract; articular ends and epiphyseal plates of long bones; fetal skeleton	External ear, external acoustic meatus, auditory tube; epiglottis and certain other laryngeal cartilages	Intervertebral discs, pubic symphysis, meniscus, and certain other joints; insertions of tendons
Main functions	Provides smooth, low-friction surfaces in joints; structural support for respiratory tract	Provides flexible shape and support of soft tissues	Provides cushioning, tensile strength, and resistance to tearing and compression

MEDICAL APPLICATION

Osteoarthritis (OA):

- Degenerative joint disease with loss of articular cartilage (hyaline cartilage). Proteoglycan & type II collagen levels decrease in matrix and chondrocytes die.

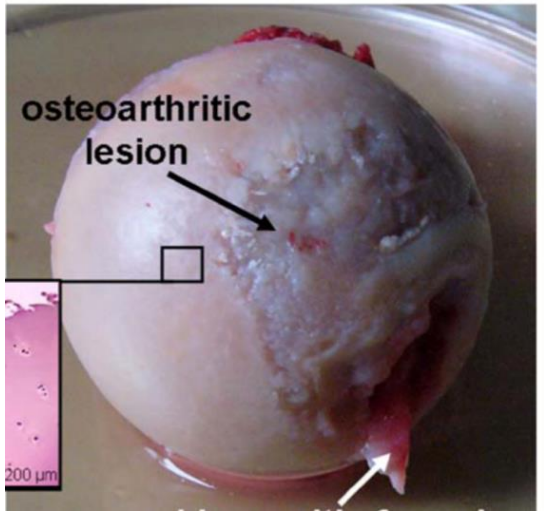

Achondroplasia:

Reduced proliferation of chondrocytes in the epiphyseal plate of long bones during infancy and childhood, resulting in dwarfism.



Bone vs. Cartilage

#	Bone	Cartilage
1	It is a solid inflexible tissue.	1. It is a rigid flexible tissue.
2	There are 2 types of bone: compact and spongy (cancellous).	There are 3 types of cartilage: Hyaline, elastic and white fibrocartilage.
3	It has a solid matrix rich in calcium. type 1 collagen and osteocalcin.	It has a rigid matrix rich in chondroitin sulphate and hyaluronic acid.
4	Bone cells (osteocytes) are present singly inside lacunae	Cartilage cells (chondrocytes) are present singly or in groups (cell nests).
5	Osteocytes intercommunicate by the canaliculi arising from their lacunae.	Chondrocytes do not communicate because there are no canaliculi
6	Bone is a vascular tissue, its haversian canals, Volkmann's canals and the canaliculi carry blood to all parts of bone	Cartilage is a none - vascular tissue its chondrocytes receive nourishment from B.V of the perichondrium.
7	Osteocytes cannot divide.	Chondrocytes can divide

Thank You