Histology of Nerve

Introduction

- Nervous tissue is one of the four basic tissues of the body .
- It consists of excitable cells specialized for *generation*, *conduction* and *transmission* of impulses
- Nervous tissue is distributed throughout the body as an integrated communications network.

- The nervous system is subdivided:

  - ❖CNS which includes the brain and spinal cord
  - ❖PNS which is composed of nerves and ganglia.

Nervous tissue cells are of two type:

1. Nerve cells (Neurons)
2. Glial cells

NEURONS

- The structural and functional unit of the nervous system

- Consist of three main parts:

1. The cell body or perikaryon
2. The dendrites
3. The axon

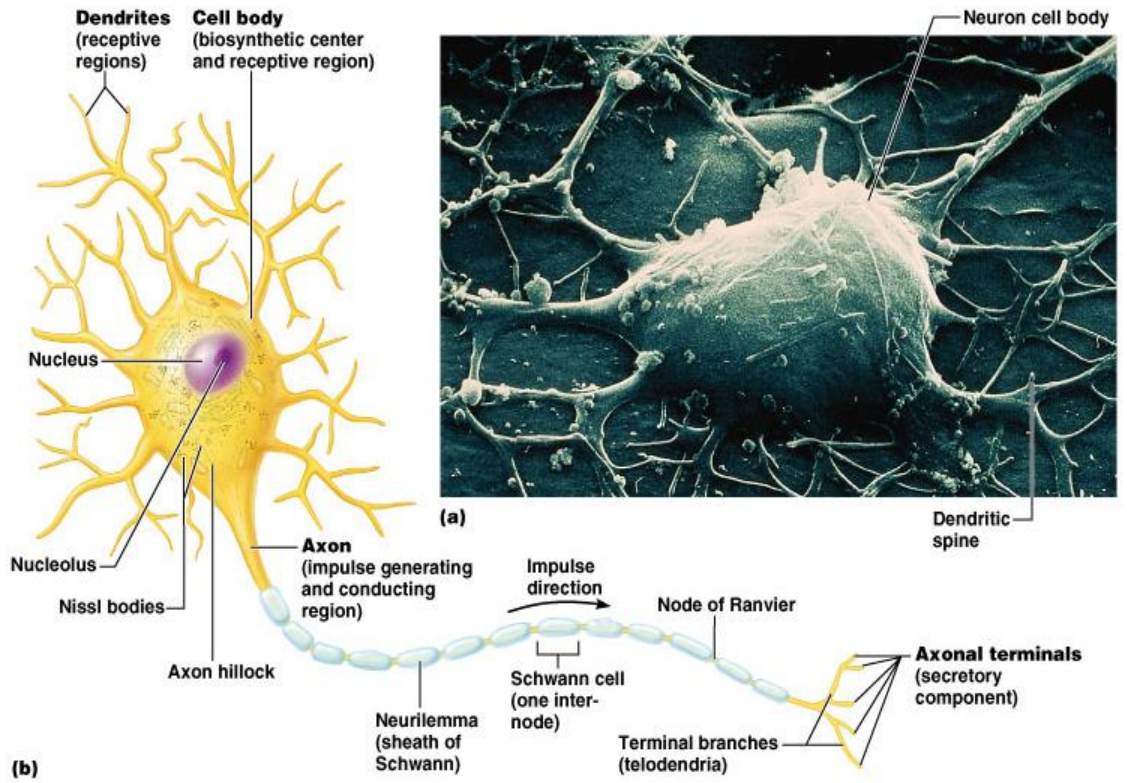

Cell body

- It contains the nucleus and surrounding cytoplasm
- Nucleus is usually large spherical and central euchromatic with a prominent nucleolus.
- The cytoplasm is basophilic because contain polyribosomes and group of many parallel cisternae with abundant RER called ***Nissl substance***

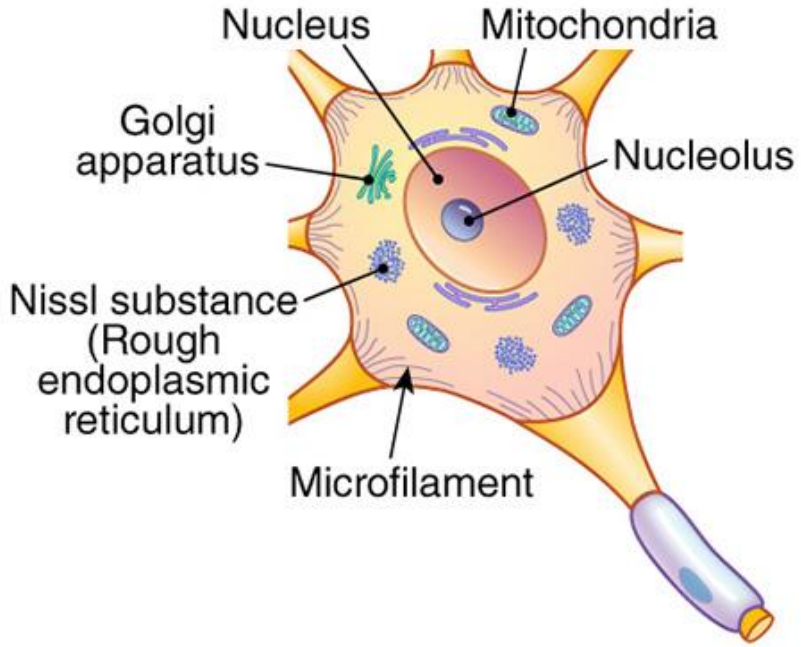

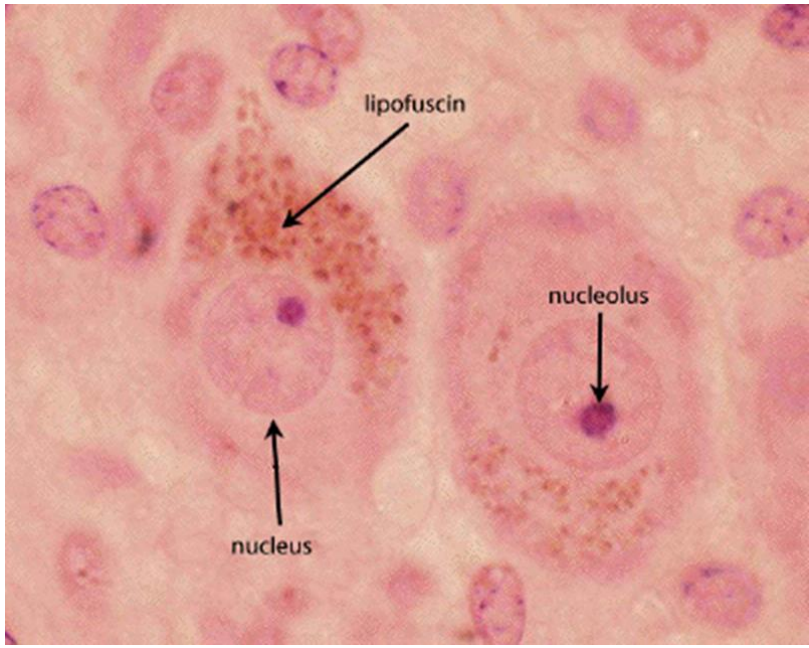

- The Golgi apparatus is located only in the cell body
- Also contain microtubules which are transport secretory vesicles .
- Nerve cells occasionally contain inclusions of pigmented material, such as lipofuscin, consisting of residual bodies left from lysosomal digestion.

Dendrites

- Are usually short and divided like tree branches
- The cytoplasm of the dendrite base is similar to that of the perikaryon, with cytoskeletal elements predominating in the branched regions.
- Most synapses impinging on neurons occur on dendritic spines which are short blunt structures projecting at points along dendrites visible with silver staining methods.

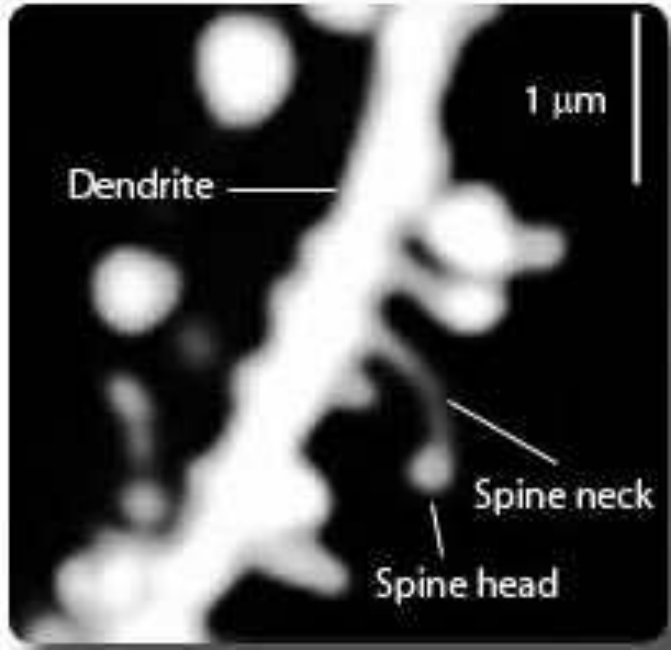

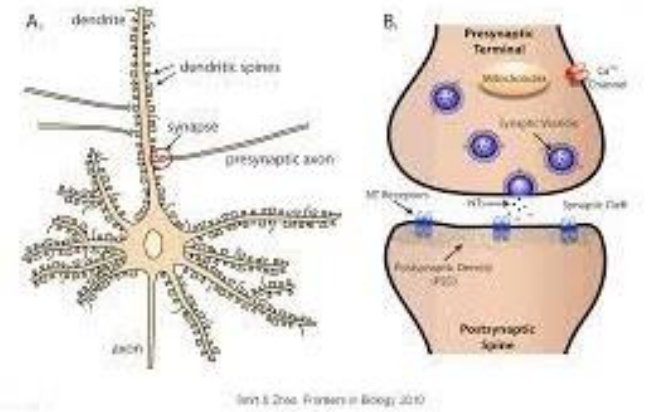

Axon

- Most neurons have only one axon
- A fine cylindrical process that varies in length and diameter according to the type of neuron
- The cytoplasm of the axon is continuous with the cytoplasm of the cell body but does not contain Nissl bodies or Golgi apparatus.

- Axons originate from region of the perikaryon called the axon hillock .
- The axon hillock is the site for summation of impulses coming from the dendrites and the cell body for generation of action potential .
- The action potential will be conducted by axon away from the cell body to other neurons, muscles or glands .

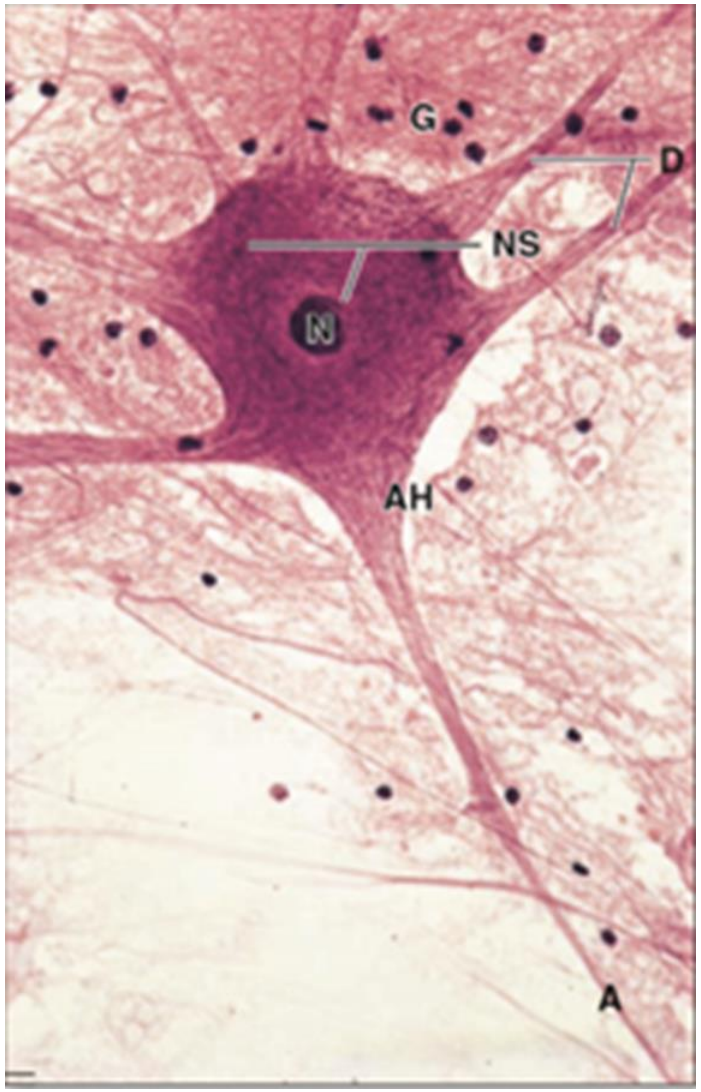

Classification of the neurons

A. According to the number of processes extending from the cell body.

B. According to their covering sheathes.

C. Functionally.

A- According to the functions

1. **Sensory** nerves are further subdivided into **Voluntary** and **Involuntary** or visceral components.

2. **Motor** nerves are subdivided into **Voluntary** and **Involuntary** (autonomic) component.

B- According to the number of processes extending from the cell body

1. ***Unipolar or pseudounipolar neurons:*** which have a single process that bifurcates close to the perikaryon and divided into a central branch which conduct impulses to CNS and a peripheral branch conducts impulses from other parts of the body.
2. ***Bipolar neurons:*** Single dendrite arise from one pole of the body and a single axon from the opposite pole. Found in the Olfactory epithelium in the nasal cavity and the retina of the eye .
3. ***Multipolar neurons:*** Most common type. Which have one axon and two or more dendrites. Present throughout the CNS and in autonomic ganglia outside the CNS.

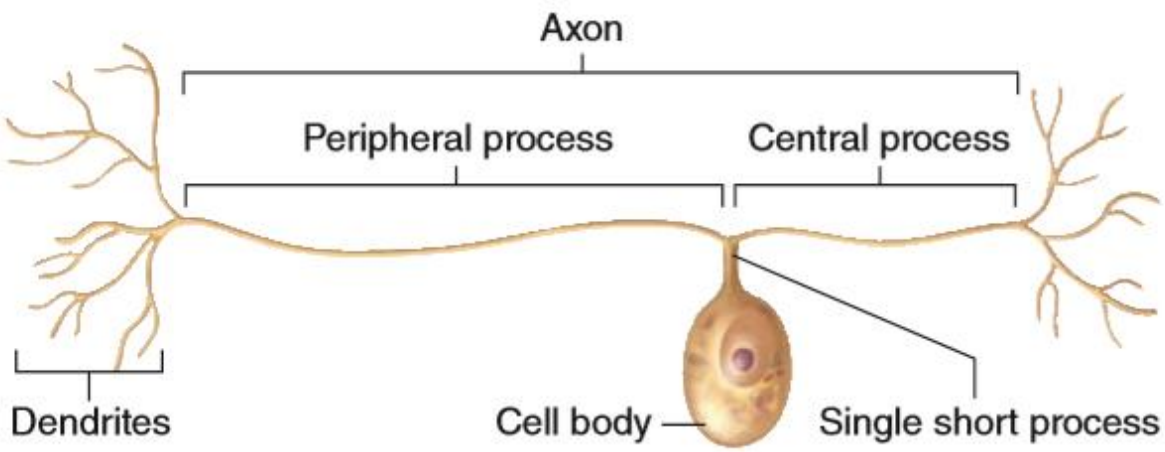

Unipolar neuron

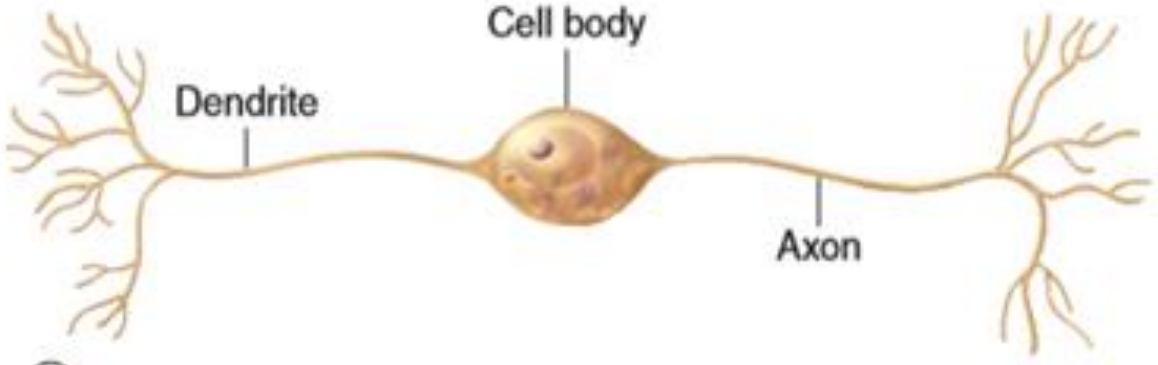

Bipolar neuron

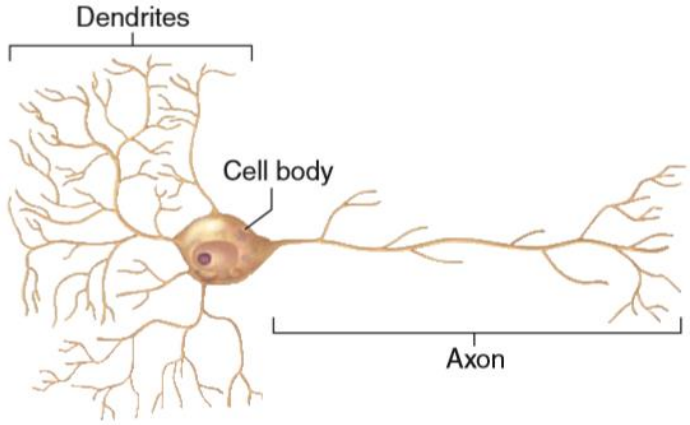

(a) Multipolar neuron

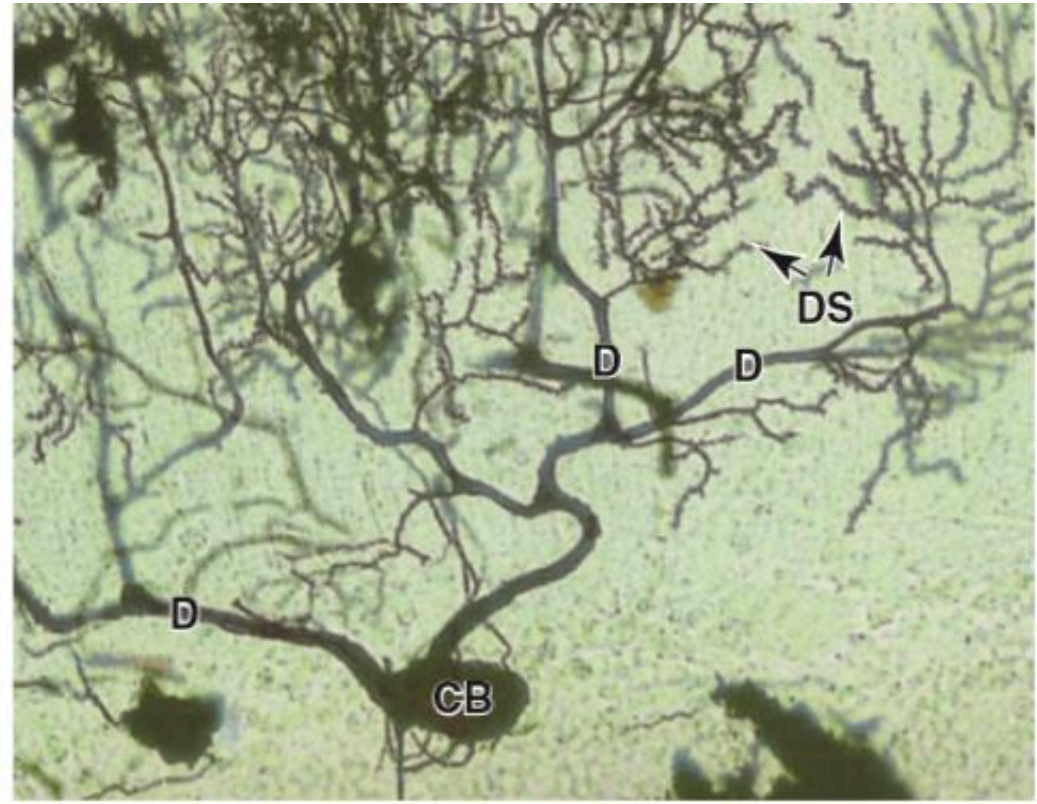

The large Purkinje neuron in this silver-impregnated section of cerebellum has many dendrites (**D**) emerging from its cell body (**CB**) and forming branches. The small dendritic branches have many short projecting dendritic spines (**DS**) spaced closely along their length, each of which is a site of a synapse with another neuron. X650. Silver stain.

C- According to their covering sheathes

1. Myelinated Nerves.
2. Unmyelinated Nerves

Myelinated axon nerves

- In the PNS myelin sheath around the axon in the spinal and cranial nerves is formed by **Schwann cells**
- Myelin sheath consist of the lipids and proteins of concentric layers of Schwann cell membrane
- In H and E sections the myelin sheath appears as a clear unstained space around a central axon limited by thin Schwann cell cytoplasm and it nucleus.
- myelin sheath is segmented each segment is formed by one Schwann cell called *internode*
- Gap between one internode and the next is called ***node of Ranvier.***

- In the CNS the myelin sheath around the axon is formed by neuroglial cells called ***oligodendrocytes.***
- Small dark staining cells with few cytoplasmic and small rounded nucleus
- Found in grey and white matter of the CNS
- In the CNS the myelinated axon not surrounded by basal lamina

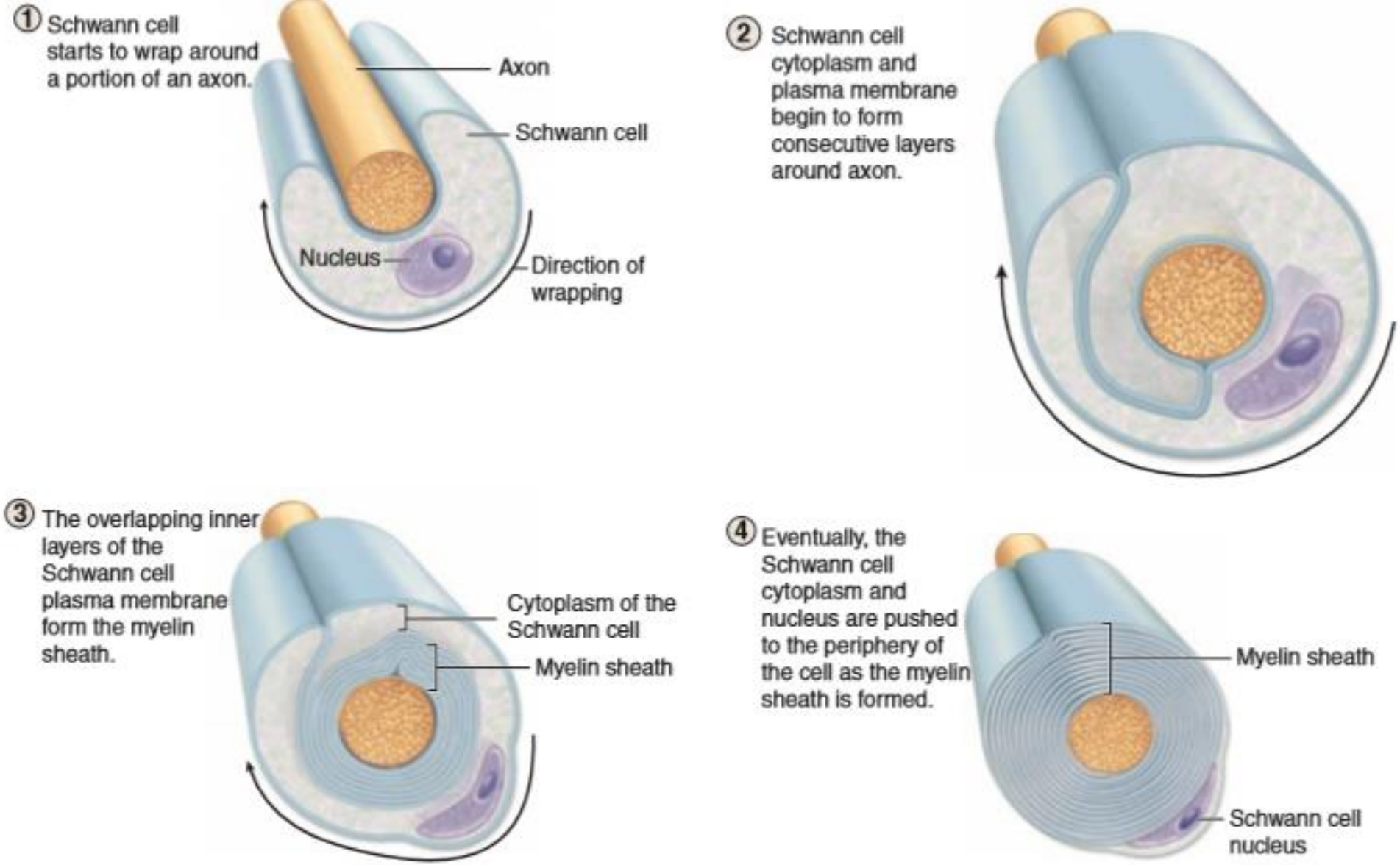

A Schwann cell (neurolemmocyte) engulfs one portion along the length of a large-diameter axon. The Schwann cell membrane fuses around the axon and elongates as it becomes wrapped around the axon while the cell body moves around the axon many times. The Schwann cell membrane wrappings constitute the myelin sheath, with the Schwann cell body always on its outer surface. The myelin layers are very rich in lipid, and provide insulation and facilitate formation of action potentials along the axolemma.

Unmyelinated axon

- In unmyelinated fibers each Schwann cell can enclose portions of many axons with small diameters.
- Without the thick myelin sheath nodes of Ranvier are not seen along unmyelinated nerve fibers.
- small-diameter axons have evenly distributed voltage-gated ion channels; their impulse conduction is much slower than that of myelinated axons.

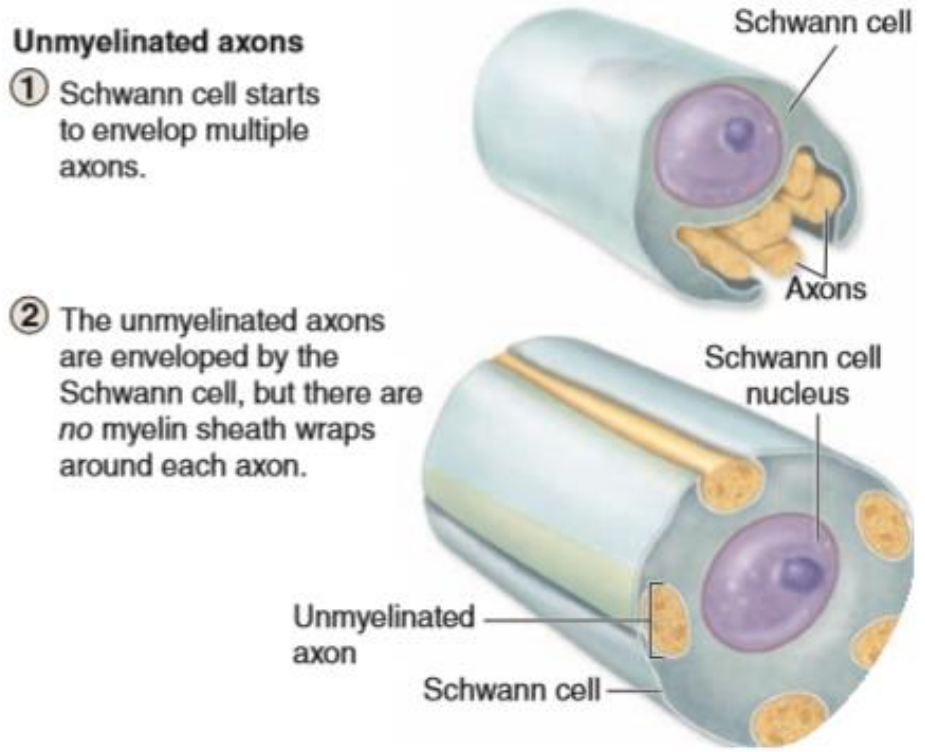

Synapse

- Synapses are sites where nerve impulses are transmitted from one neuron to another or from neurons and other effector cells
- Most synapses act by releasing neurotransmitters.
- **Presynaptic** axon terminal (terminal bouton) from which neurotransmitter is released by exocytosis from synaptic vesicles.
- **Postsynaptic** cell membrane with receptors for the transmitter and ion channels or other mechanisms to initiate a new impulse.
- **Synaptic cleft** separating the presynaptic and postsynaptic membranes.

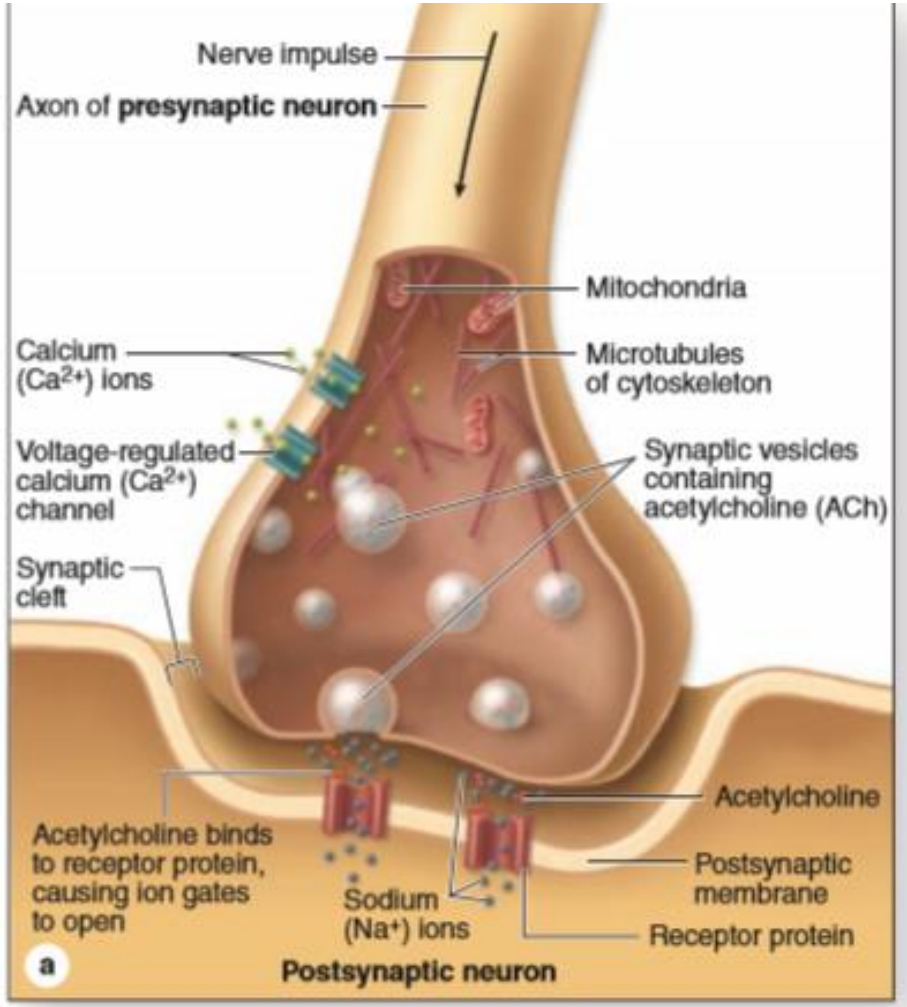

Types of synapses

1. **Axo-dendritic** synapse: in which there is a contact between an axon of one neuron and the dendrites of another neuron.
2. **Axo-somatic** synapse: in which there is a contact between an axon of one neuron and a cell body of another neuron.
3. **Axo-axonic** synapse: contact between the axon of two neurons.

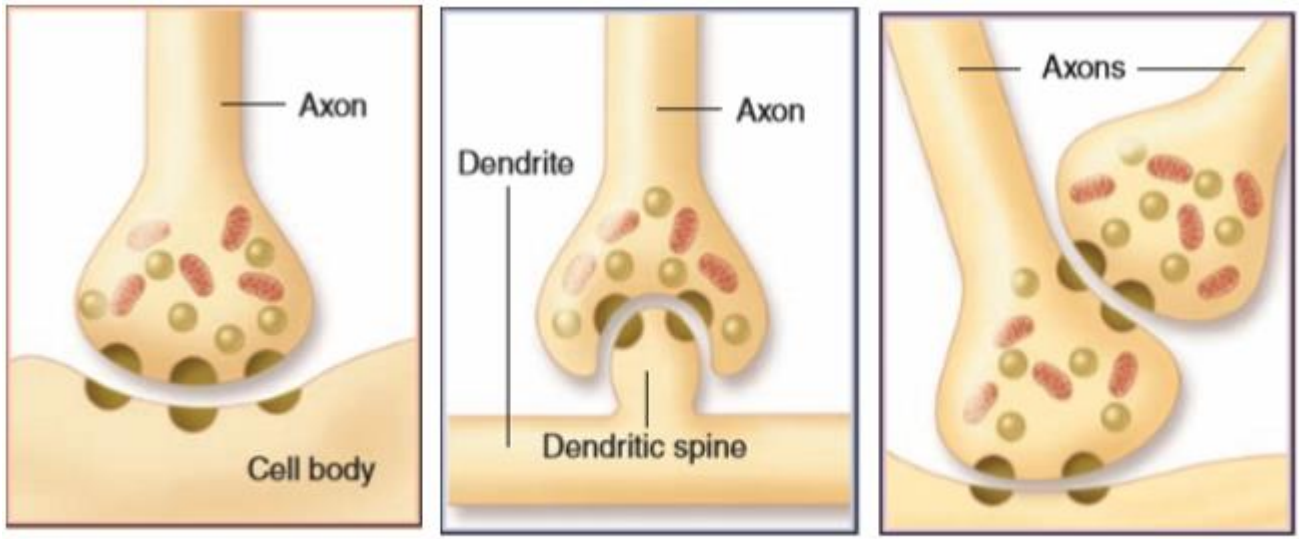

Axo-somatic Axo-dendritic Axo-axonic

GLIAL CELLS

- Support neuronal survival and activities
- They do not conduct impulses or form synapses with other cells
- Appear to provide some regulation of neurons in the process of neural transmissions.
- Neuroglial cells possess the capacity to undergo cell division.

Types of neuroglial cells according to location

CNS	PNS
Astrocytes	Schwann cells
Oligodendrocytes	Satellite cells
Microglia	
Ependymal cells	

Astrocytes

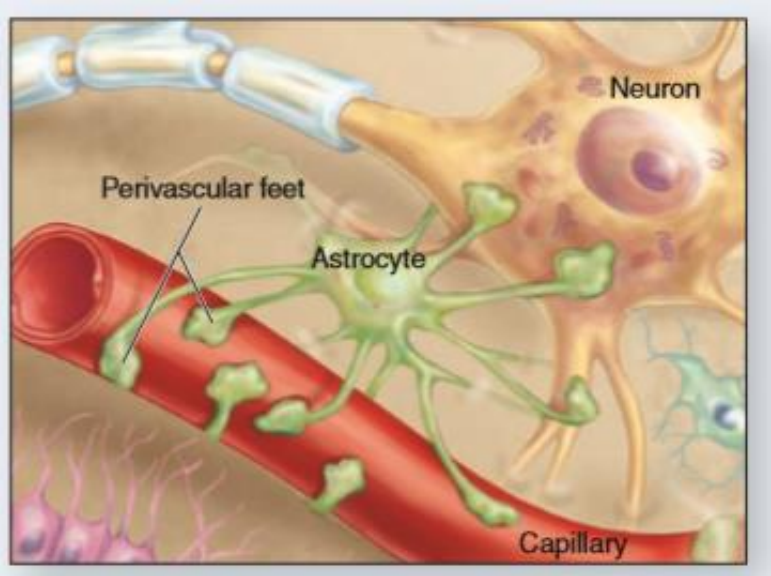

- The largest of the neuroglial cells in the CNS.
- Scavenge ions and debris from neuron metabolism and supply energy for metabolism.
- They proliferate to form scar tissue (glial scar) after injury to the CNS.

Types of astrocytes:

1. Protoplasmic astrocytes: reside mostly in gray matter.
2. Fibrous astrocytes: reside mostly in white matter.

Oligodendrocytes

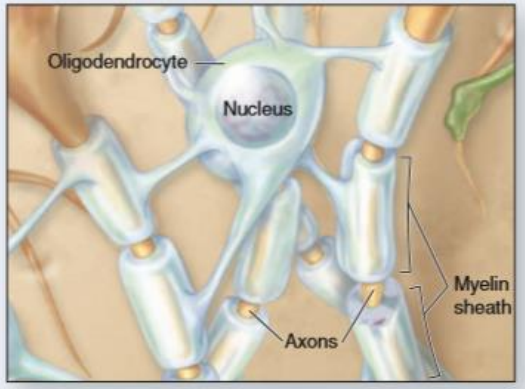

a Oligodendrocyte

They are necessary for survival of neurons in the CNS.

- They are located in both gray matter and white matter.
- They possess a small, round, condensed nucleus and only a few short processes.
- Their electron-dense cytoplasm contains ribosomes, numerous microtubules, many mitochondria, RER, and a large Golgi complex.
- Oligodendrocytes produce myelin, a lipoprotein material organized into a sheath that insulates and protects axons in the CNS.

Microglia

- They are the only phagocytic cells that defend the CNS against infection.
- They arise from monocyte that originate in the bone marrow as apart of mononuclear phagocytic system .
- They are found in the gray and white matter.

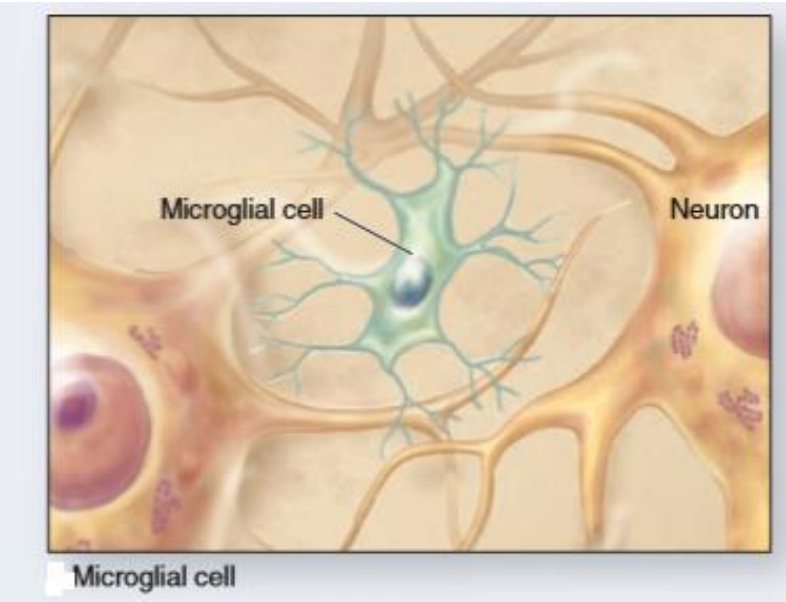

Microglial cell

Schwann cells

- Schwann cells located in the PNS are flat cells with only a few mitochondria and a small Golgi region
- These cells perform the same function in the PNS as oligodendrocytes in the CNS: they protect and insulate neurons.
- Schwann cells form either unmyelinated or myelinated coverings over neurons.

TABLE

Origin, location and principal functions of neuroglial cells.

Glial Cell Type	Origin	Location	Main Functions
Oligodendrocyte	Neural tube	CNS	Myelin production, electrical insulation
Schwann cell (Neurolemmocyte)	Neural crest	Peripheral nerves	Myelin production, electrical insulation
Astrocyte	Neural tube	CNS	Structural and metabolic support of neurons; BBB; repair processes
Satellite cells (of ganglia)	Neural crest	Peripheral ganglia	Structural and metabolic support for neuronal cell bodies
Ependymal cell	Neural tube	Line ventricles and central canal of CNS	Aid production and movement of CSF
Microglia	Bone marrow (monocytes)	CNS	Defense and immune-related activities

Nerves are bundles of nerve fibers (axons) surrounded by Schwann cells and layers of connective tissue.

Each nerve is surrounded by connective tissue sheaths:

1. **Epineurium (fascia):** forms the external coat of the nerve.

2. **Perineurium (fascicle):** surroumds a group of nerve fibers. Its inner surface consists of layers of flattened cells joined by tight junctions.

3. **Endoneurium:** surrounds each nerve fiber and difficult to observe without specialized stains.

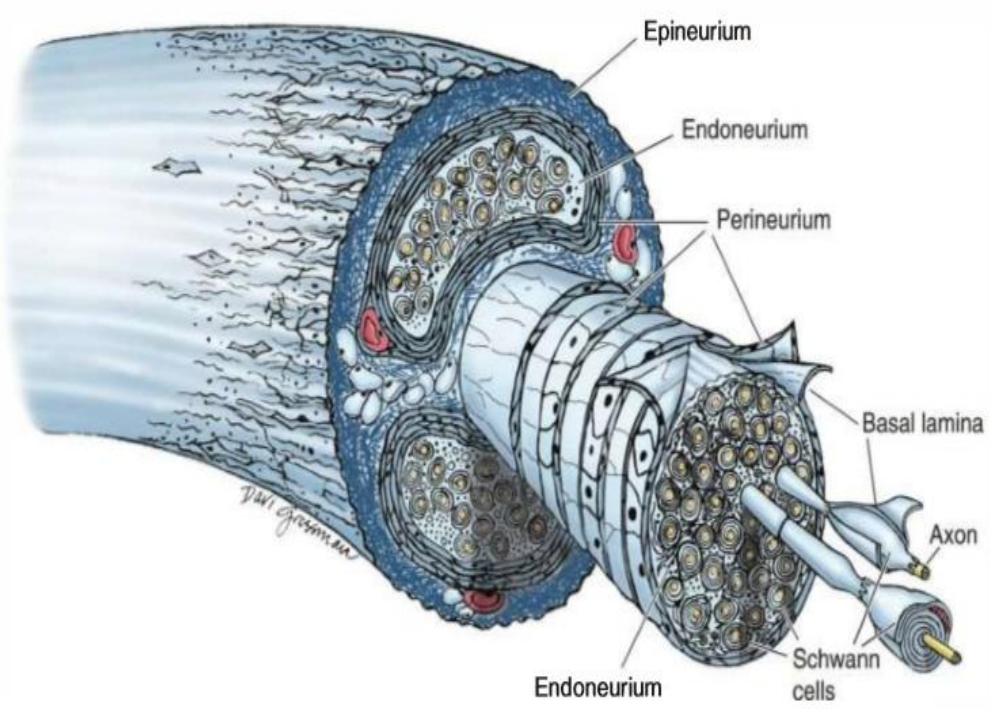

Ganglia

Group of neuron cell bodies situated outside the CNS

1. **Sensory ganglion** (craniospinal ganglia): located on the dorsal root of all spinal nerves and in some of the cranial nerves.
2. **Autonomic ganglia :**

- Sympathetic ganglia are located in the sympathetic chain near the vertebral column in the thorax and abdomen.
- Parasympathetic ganglia are located near or in the organs they supply except those of the head region.

Sensory ganglion

- The spinal ganglion covered by thick connective tissue capsule which is continuous with the epineurium of the peripheral nerve .
- Contain group of unipolar sensory neuron.
- The large neuronal cell bodies of ganglia are associated with thin, sheet like extensions of small glial satellite cells

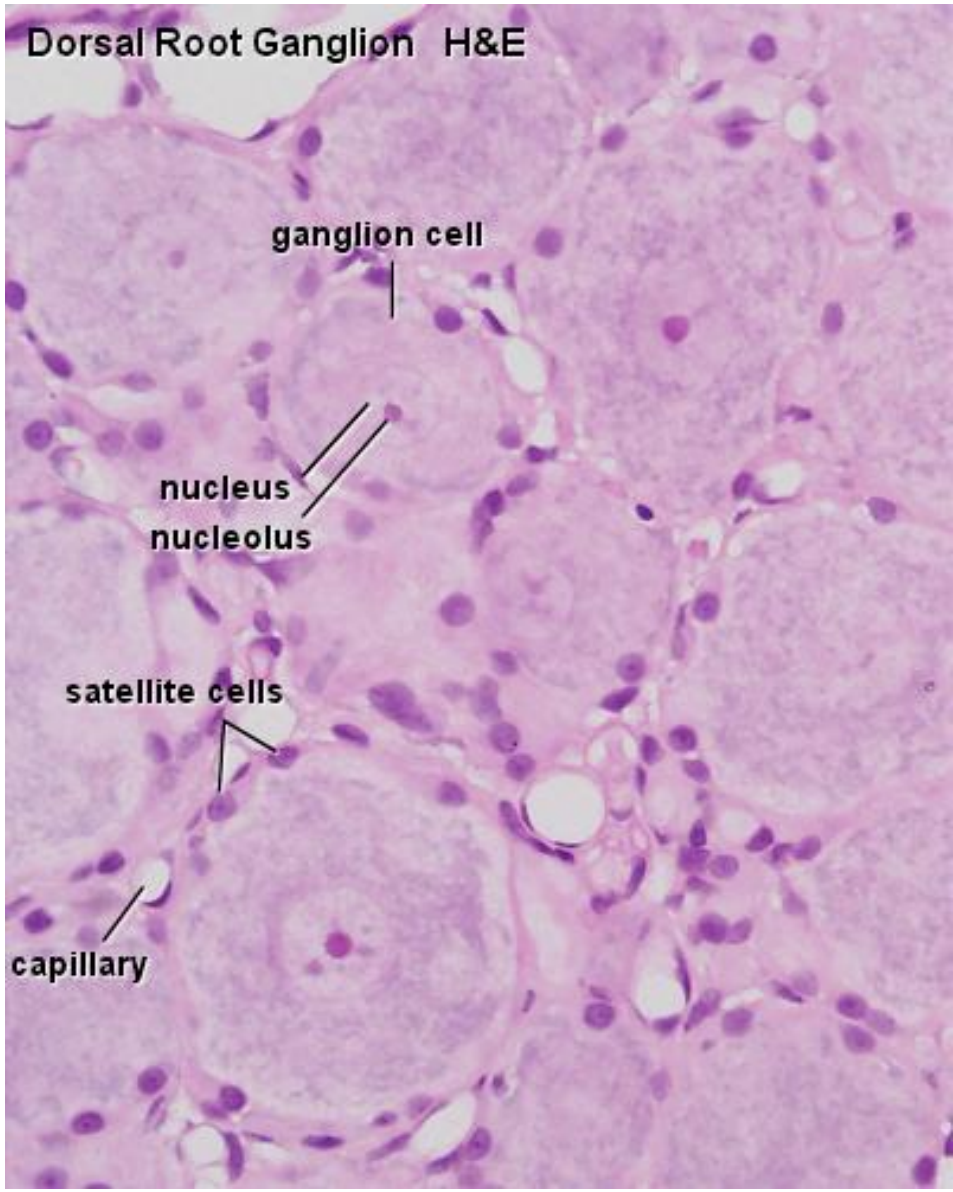

Autonomic ganglion

- Autonomic ganglia are small bulbous dilations in autonomic nerves, usually with multipolar neurons.
- Some are located within certain organs, especially in the walls of the digestive tract, where they constitute the intramural ganglia.
- Autonomic nerves use two-neuron circuits
- . The first neuron of the chain with the preganglionic fiber is located in the CNS.
- Its axon forms a synapse with postganglionic fibers of the second multipolar neuron in the chain located in a peripheral ganglion system.

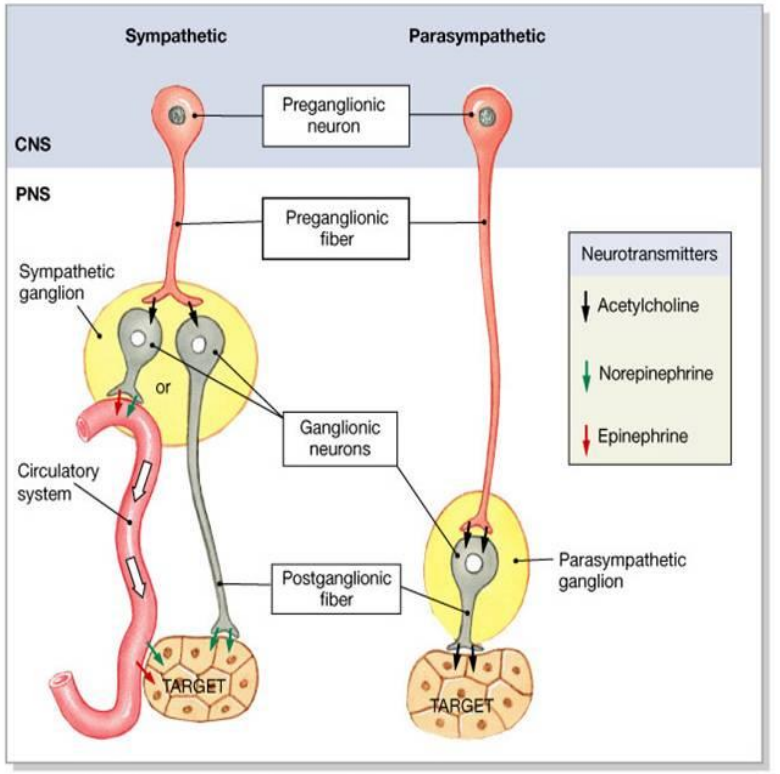

Blood brain barrier (BBB)

- This is a barrier, formed by astrocytes, between the blood in the capillaries and neurons in the brain.
- The BBB prevents the passage of toxic substance and some chemicals from the blood into the nervous tissue of the brain.
- It allows the transfer of ions and nutrients from the blood to the neurons.
- The blood brain barrier consists of:

  1- The endothelial cell of continuous blood capillaries joined together by tight junction.

  2- The basal lamina of the endothelium

  3- The perivascular feet process of astrocytes covering the endothelial cells.

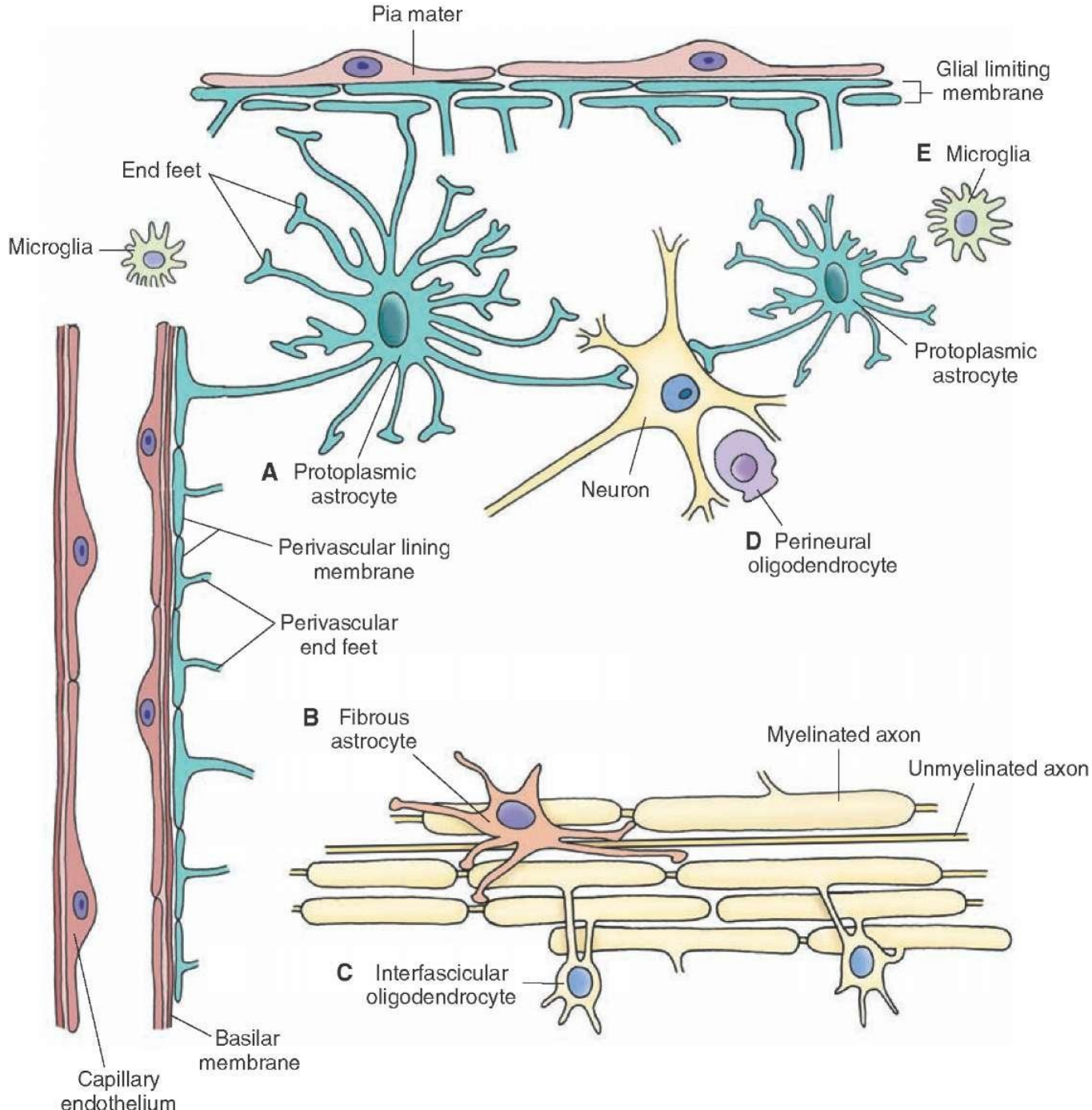
Pia mater
Glial limiting membrane
End feet
E Microglia
Microglia
Protoplasmic astrocyte
A Protoplasmic astrocyte
Neuron
D Perineural oligodendrocyte
Perivascular lining membrane
Perivascular end feet
B Fibrous astrocyte
Myelinated axon
Unmyelinated axon
C Interfascicular oligodendrocyte
Basilar membrane
Capillary endothelium

Thank You