ANATOMY TUTORIALS 1 -4 PRESENTATIONS

Tutorial 1 – QN 1
Midshaft Clavicle Fracture

A 20-year-old cyclist falls onto his shoulder and presents with pain, swelling, and an obvious deformity over the clavicle. Examination shows drooping of the shoulder and difficulty in lifting the arm. X-ray confirms a midshaft clavicle fracture. What are the expected complications?



Primary impact: Direct shoulder trauma and outstretched hand.

Midshaft fractures account for ~80% of all clavicular fractures

SSEMPEBWA TARIF (MBCHB EQ26/MBCHB/AUG/0025D)

The clavicle acts as a vital ‘strut’ that holds the arm away from the trunk and transmits physical forces from the upper limb to the axial skeleton.

The clavicle bone shape creates a natural structural weak point

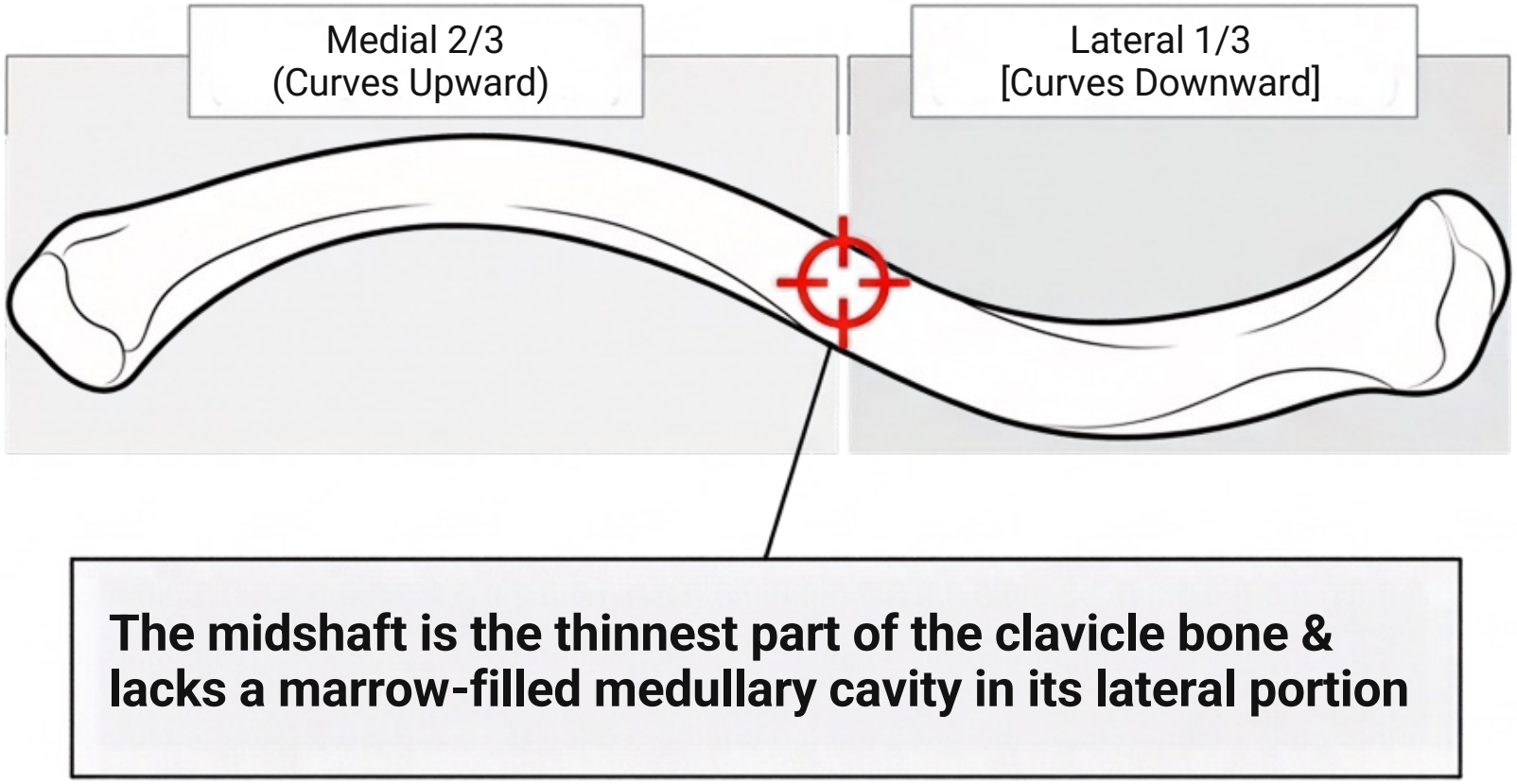

Sternocleidomastoid Muscle Pull

Displaces the medial fragment upward

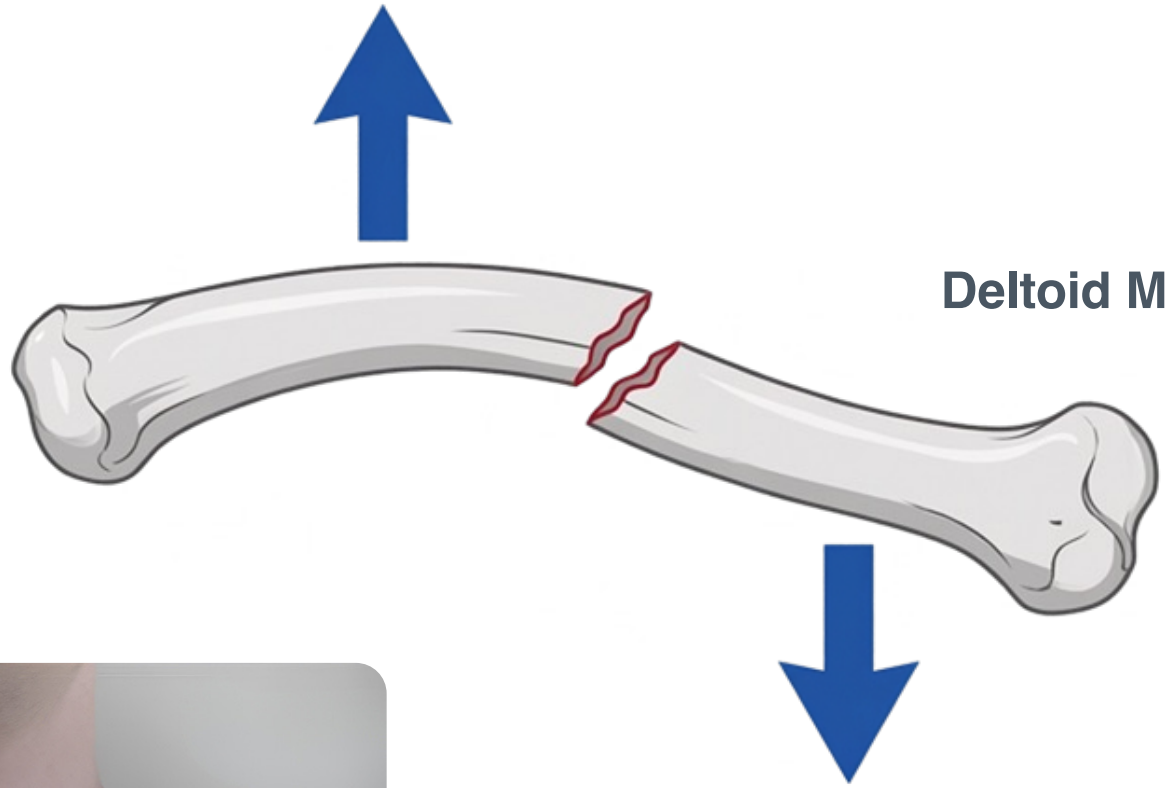

Deltoid Muscle & Arm Gravity

Displaces the lateral fragment downward



The opposing vectors create a overlapping step-off deformity visible beneath the skin.

EXPECTED COMPLICATIONS



Lung Apex Puncture

The top part of the lung sits just behind and above the inner third of the collarbone - [Pneumothorax]



Malunion / Non-union

complications that happen when a broken bone does not heal the right way

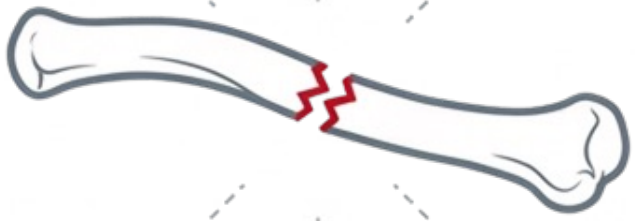



Subclavian Artery & Vein

run directly behind the middle third of the clavicle - [massive bleeding]

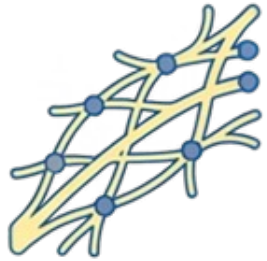

Brachial Plexus

causes significant sensory & motor deficits
The upper trunk, lateral cord & the suprascapular nerve

PRESENTED BY

NAGAWA IMMACULATE

EQ26/MBChB/AUG/0027D

CASE 2: BASKETBALL PLAYER WITH ANTERIOR DISSLOCATION AND FLATTENED CONTOUR

Shoulder dislocation: Is the dislocation of the head of humerus from glenoid which is part of the scapular.

Primary diagnosis: Acute anterior glenohumeral (Shoulder) Dislocation.

Joint type: multiaxial ball and socket synovial joint.

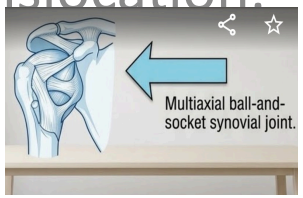

Articular surfaces: Large round head of humerus articulates shallow glenoid cavity of the scapula

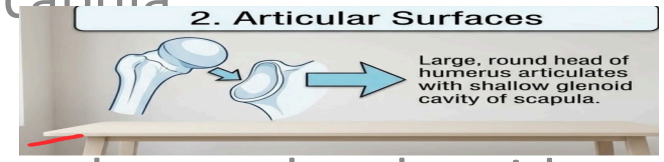

Glenoid labrum; Ring of fibrocartilage that attaches to the glenoid margin to slightly deepen the socket.

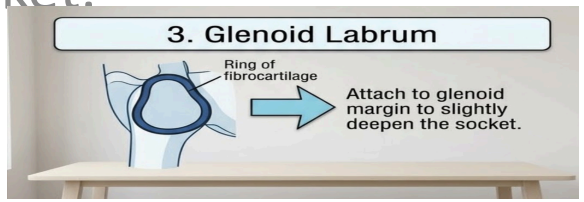

Inherent instability; The shallow glenoid accepts less than one-third of the humeral head, giving stability for maximum mobility.

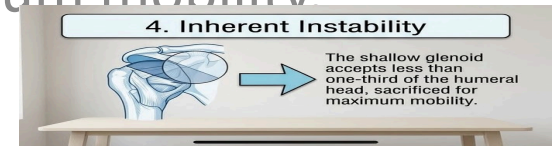

JOINT ANATOMY,HUMERUS STRUCTURE, CAPSULE AND LIGAMENTS

Joint capsule: Attaches medially to the glenoid margin and laterally to the anatomical neck of the humerus.

Weakest point: The inferior part of the joint capsule is remarkably lax and unsupported by reinforcing tendons.

Glenohumeral joint: formed by the head of the humerus articulating with shallow glenoid cavity of the scapular

Coracohumeral ligament: Strong band extending from the coracoid process to the greater tubercle, reinforcing the capsule superiorly.

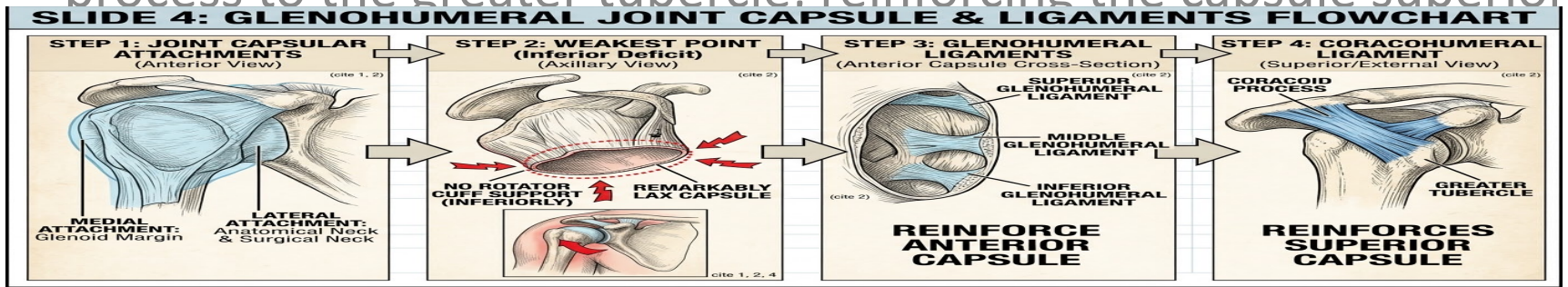

PROXIMAL HUMERUS LANDMARKS

GREATER AND LESSER TUBERCLES: Attachment sites for the rotator cuff muscles that compress and stabiles the joint

INTERTUBERCULAR GROOVE: Holds the tendon of the long head of biceps brachii which acts as a dynamic head depressor and stabilizer

SURGICAL NECK: Vulnerable site for fractures associated with shoulder dislocations and neurovascular (axillary nerve) injury

ROTATOR CUFF ROLES

- **SUBSCAPULARIS:** Inserts on the lesser tubercle; provides internal rotation and acts as the primary dynamic shield that prevents anterior dislocation.
- **Supraspinatus:** Inserts on the greater tubercle; initiates abduction and depresses the humeral head into glenoid cavity which prevents downward drift.
- **Teres minor:** inserts on the greater tubercle; provides external rotation and adduction. It depresses the humeral head during hyperabduction and elevation.
- **Infraspinatus:** inserts on the greater tubercle; provides external rotation and stabilization of the humerus. It acts as a rear tension pulling the backwards to resist the forward translation.

CORACO-ACROMIAL ARCH AND BURSAE

- **Coraco-acromial arch:** Formed by the acromion, coracoid process and coraco-acromial ligament to prevent superior displacement.
- **Subacromial bursa:** Located between the arch and supraspinatus tendon to reduce friction.
- **Sub tendinous bursa of subscapularis:** Positioned between subscapularis tendon and scapular neck and communicates directly with joint cavity.

MECHANISM OF INJURY

- **Primary traumatic position:** Forced abduction, external rotation and extension, for example throwing a ball or landing on an outstretched arm
- **Patho mechanics:** the indirect lever force pushes the head of the humerus anteriorly and inferiorly against anterior joint capsule. This overwhelms the anterior dynamic stabilizers e.g. the subscapularis and static stabilizers e.g. the glenohumeral ligaments and the labrum
- **Results after displacement:** Humeral head pops out of the shallow glenoid cavity and protrudes anteriorly beneath the coracoid process (subcoracoid position).

CLINICAL PRESENTATION

PHYSICAL EXAM

- **Inspection:** loss of normal rounded shoulder contour eg flattened deltoid appearance
- Prominent acromial with a subacromial emptiness or gap
- **Arm position:** the patient holds the injured arm in slight abduction and external rotation supporting it with the uninjured hand
- **Palpation:** humeral head is palped (felt) anteriorly beneath the coracoid process

CONTI..

Neurovascular examination

Circulation (vascular assessment);

- **Radial and brachial pulses:** palpate to rule out compression or injury to the axillary nerve

Motor and sensor (neurological assessment);

- **Axillary nerve (most injured nerve)**

1. **Sensory test:** test touch sensation around regimental badge (lateral badge patch on the upper deltoid)
2. **Motor test:** deltoid contraction (avoid force during acute dislocation)

Radial and median nerve: asses thumb extension and finger flexion to rule out branchial plexus traction

CLINICAL CORRELATES

- **Dugas sign:** a patient is instructed to place the injured hand onto the opposite shoulder down to touch their chest
- **Positive result:** in acute anterior dislocation, the patient cannot touch their elbow to their chest while keeping their hand on opposite shoulder
- **Clinical correlate;** bringing the elbow to the chest requires simultaneous internal rotation and horizontal abduction of the humerus. Because the humeral head is pushed anteriorly beneath the coracoid process combined with severe protective muscles there is mechanical shock preventing this motion
- **Hamilton's ruler test (occurs in bone tissue):** a straight ruler is placed against the lateral aspect of the arm touching the lateral epicondyle of the humerus
- **Positive test:** the ruler touches both the lateral epicondyle and acromion simultaneously

Conti…

- **Clinical correlate:** the normal rounded contour of the shoulder created by humeral head resting in glenoid cavity is lost allowing the straight edge to bridge directly across the empty lateral space to contact the acromion
- **Bankart lesion (occurs in soft tissues):** this involves tearing or detachment of the anterior –inferior glenoid labrum away from the glenoid cavity
- **Clinical correlate:** occurs when the dislocating humeral head is forced anteriorly tearing the main static stabilizer joint and hence this structural disruption is the primary cause of recurrent anterior shoulder instability and persistent joint apprehension

conclusion

- **Summary:** Shoulder joint mobility comes at the direct cost of structural stability.
- **Key outcome:** Anterior dislocation occurs through the unsupported inferior capsule resulting in empty glenoid cavity, deltoid flattening and high risk to the axillary nerve.

REFERENCE

- *Moore,K. L., Dalley, A. F., & Agur, A. M. R. (2018). Clinically Oriented Anatomy (8th ed.).*

THANKS FOR LISTENING

MEDICAL CASE PRESENTATION • TUTORIAL 1

Supraspinatus Tendon Injury

Etiology, Clinical Presentation, Diagnostics & Therapeutic Interventions

BWEBALE RAYMOND

REG: EQ/MBChB/AUG/0018D

MBChB Program

ROTATOR CUFF PATHOLOGY

Supraspinatus Tendon Injury

CLINICAL VIGNETTE

62-year-old painter presents with shoulder pain when raising his arm overhead. Examination reveals **weakness in the first 15° of abduction** and a painful arc. MRI confirms a **Supraspinatus tendon tear**.

Mechanisms of Damage

1. Wear & Degeneration

Age-related changes naturally weaken tendon structure, increasing tear susceptibility in patients over 40.

2. Repetitive Overhead Activity

Constant strain from occupations (painting, construction) or sports (baseball, tennis, swimming).

3. Subacromial Impingement

Tendon rubs against the acromion bone during movements, driving inflammation and ultimate tearing.

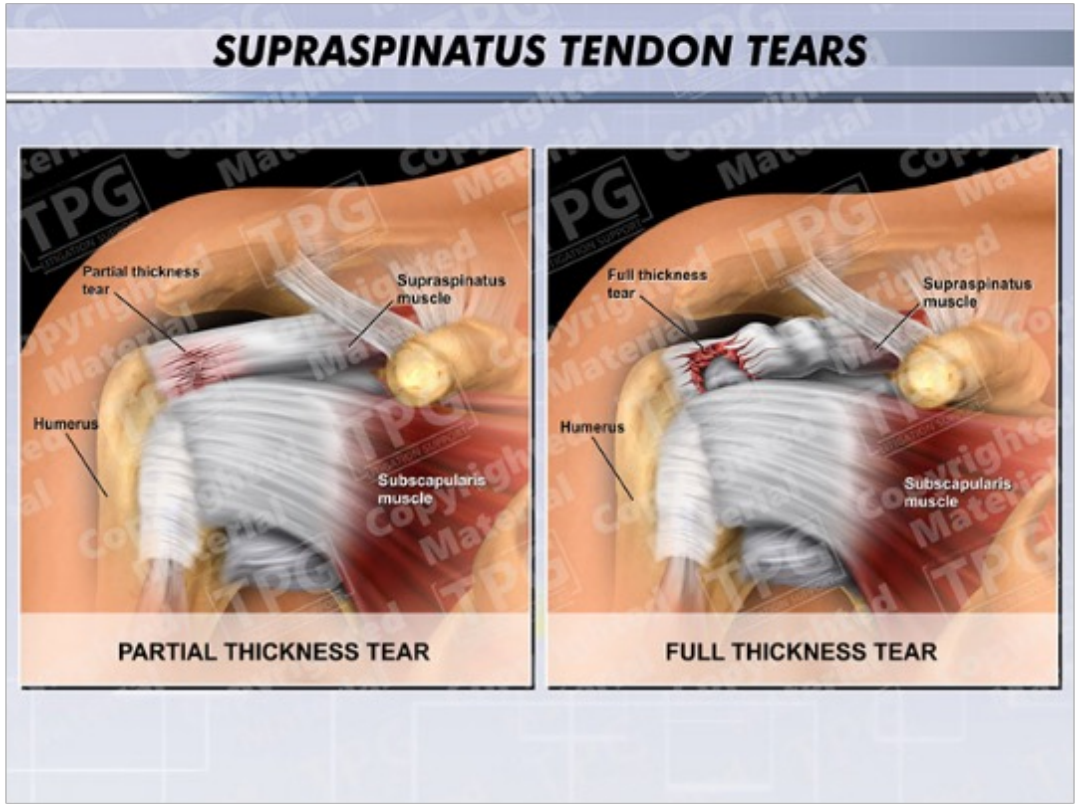

CLINICAL PRESENTATION & MANAGEMENT

Signs & Treatment Options

Clinical Signs & Symptoms

Shoulder & Nocturnal Pain Persistent shoulder ache, frequently worsening at night.

Arm Weakness & Power Loss Significant loss of power when lifting or rotating the arm.

Painful First 15° Abduction Deficit in initiating arm abduction away from the body.

Limited Range of Motion Stiffness and restricted mobility during overhead reaching.

Management & Interventions

- Rest & Ice
- Physical Therapy
- Medication
- Steroid Injections
- Surgery

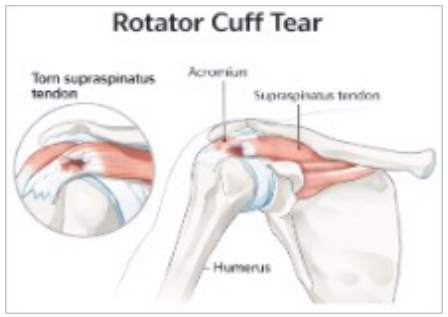

MUTEBI KENNETH SIMON EQ26/MBChB/AUG/0004D

Clinical Case Presentation

Winged Scapula Following Breast Cancer Surgery

Anatomical evaluation and pathophysiological correlation of long thoracic nerve injury and serratus anterior muscle paralysis post-ALND.

Patient Demographic: 35-Year-Old Female | Post-Axillary Lymph Node Dissection

CLINICAL PRESENTATION & DIAGNOSIS

Physical Examination

- **Patient Profile:** 35-year-old female presenting after recent axillary lymph node dissection (ALND) for breast cancer.
- **Chief Complaint:** Protrusion and deformity of the right shoulder blade during upper limb resistance pushing.
- **Wall Push-Up Test:** Pushing against resistance reveals striking protrusion of the medial border and inferior angle of the scapula.
- **Diagnosis:** Classic **Winged Scapula** secondary to surgical trauma to the local motor innervation.

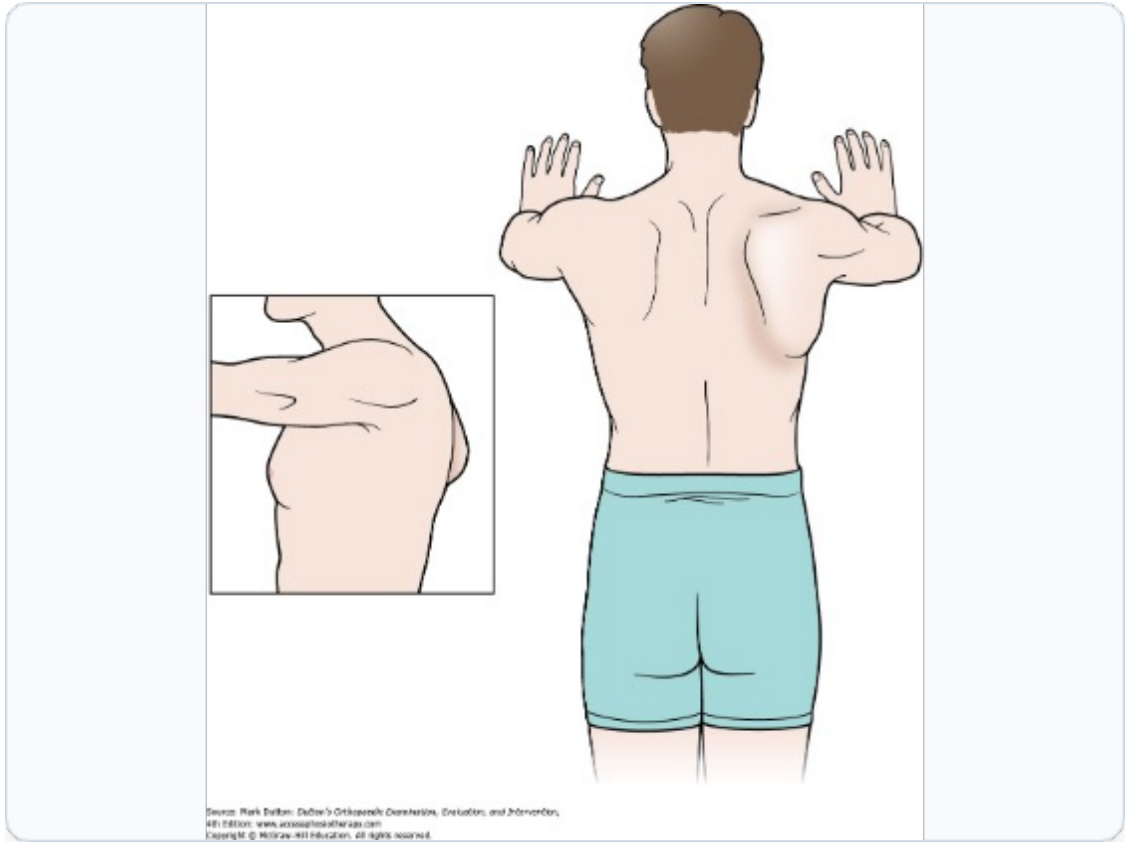

ANATOMICAL & NERVE CORRELATION

Anatomical Analysis

- **Injured Nerve: Long Thoracic Nerve** (Arises from nerve roots C5, C6, C7).
- **Paralyzed Muscle: Serratus Anterior Muscle**.
- **Mechanism of Injury:** Nerve traverses superficial to serratus anterior on the lateral chest wall, making it vulnerable during ALND.
- **Functional Deficit:** Loss of scapular protraction and stabilization against the posterior thoracic cage wall.

Clinical Takeaway: Without serratus anterior traction, pushing forces cause the medial border of the scapula to lift outward.

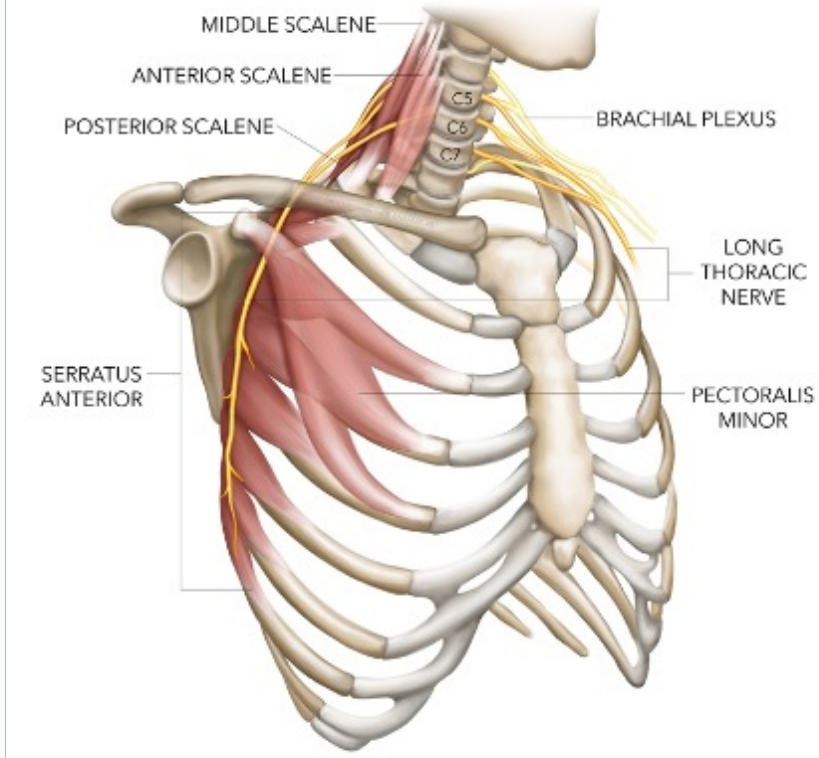

Staging of breast lump with enlarged axillary lymph nodes

By

Hadijjah Ibrahim Nampeera
EQ26/BDS/AUG/0014D

TUTORAIL 1 QN.5

A 48-year-old woman with a breast lump undergoes clinical staging. Examination shows firm, enlarged lymph nodes in the axilla. What is the diagnosis

What is a breast lump ?

- A breast lump is localized mass of abnormal tissue within the breast.
- It may be benign e.g fibroadenoma or malignant(breast cancer).
- If cancer is suspected or confirmed, assessment includes the primary tumour , regional lymph nodes and distant spread.
- Enlarged axillary nodes are clinically important because the breast drains mainly to the axillary nodes.

BREAST ANATOMY

Breast

- Located on the anterior thoracic wall ,mainly over pectoralis major .
- Contains glandular tissues , ducts , fat , and connective tissue .
- Lymphatics form superficial and deeper networks.

Lymphatic drainage

- Most breast lymph drains to ipsilateral axillary lymph nodes .
- Pectoral (anterior) axillary nodes receive much of breast lymph.
- Other routes include internal mammary glands , interpectoral and supraclavicular nodes .

Axillary lymph nodes - anatomy

- Anterior : along the lateral thoracic vessels ;major drainage from the breast .
- Posterior :along the posterior axillary wall .

Clinically , axillary nodes are also described as levels I ,II and III according to their relationship to pectoralis minor.

Axillary node levels

Level I

- Lateral to pectoralis minor.
- Includes pectoral ,subscapular and humeral groups .
- Common first station for breast lymphatic drainage .

Level II and III

- Level II : posterior to pectoralis minor .
- Level III :superior to pectoralis minor.

Lymphatic Drainage of the Breast

- Most lymph from the breast nodes to the axillary lymph nodes .
- About 75% drains to the axillary nodes ,especially the anterior group.
- Medial breast lymph may drain to the internal thoracic nodes.
- Lymphatic spread is important in breast cancer staging .

Axillary Nodes Involved in Breast Cancer

- Anterior nodes receive much of the lymph from the breast .
- Central nodes receive lymph from the pectoral ,subscapular and humeral groups .
- Apical nodes receive lymph from the central nodes and drain toward the subclavian trunk .
- Enlargement of these nodes may indicate lymphatic spread .

Clinical staging: TNM

- T-describes the size and local extent of the primary breast tumour.
- N-describes the regional lymph-node involvement.
- M-indicates distant metastasis .
- An enlarged axillary node raises concern for the regional spread ,but confirmation requires clinical assessment.

Anatomical Basis of Enlarged Axillary Nodes

- Breast lymphatics communicate with the axillary lymph-nodes.
- Tumour cells can travel lymphatic vessels to regional nodes.
- Nodes may become enlarged because of tumour deposits or other causes such as infection.
- Sentinel lymph-node can help determine regional spread.

Key points

- Breast cancer commonly spreads first through lymphatic pathways.
- Axillary nodes are clinically important because they are major regional drainage site.
- Node involvement contributes to breast cancer staging and prognosis.

REFERENCES

- **Moore**
- **Clinically Oriented Anatomy**

FIBROSIS AND THICKENING OF THE SHOULDER JOINT CAPSULE

BY NAKABUGO ELIZABETH EQ26/AUG/BDS/0001D

TUTORAIL 1 – QN 6

DIAGNOSIS

- This is known as adhesive capsulitis also known as frozen shoulder
- It is common in people with diabetics
- Frozen shoulder is caused by thickening ,tightening, scaring, of connective tissue capsule surrounding the shoulder joint and thickening of the coracohumeral ligament.
- Some of the signs and symptoms include ; stiffness, external rotation is limited, abduction beyond 90 degrees is limited , constant pain ,loss of both active and passive range of motion etc.
- Some of the treatments include ; physiotherapy(gentle stretching, ROM exercises)
- Starts with external rotation failing

IMAGE SHOWING FIBROSIS AND THICKENING OF SHOULDER JOINT CAPSULE

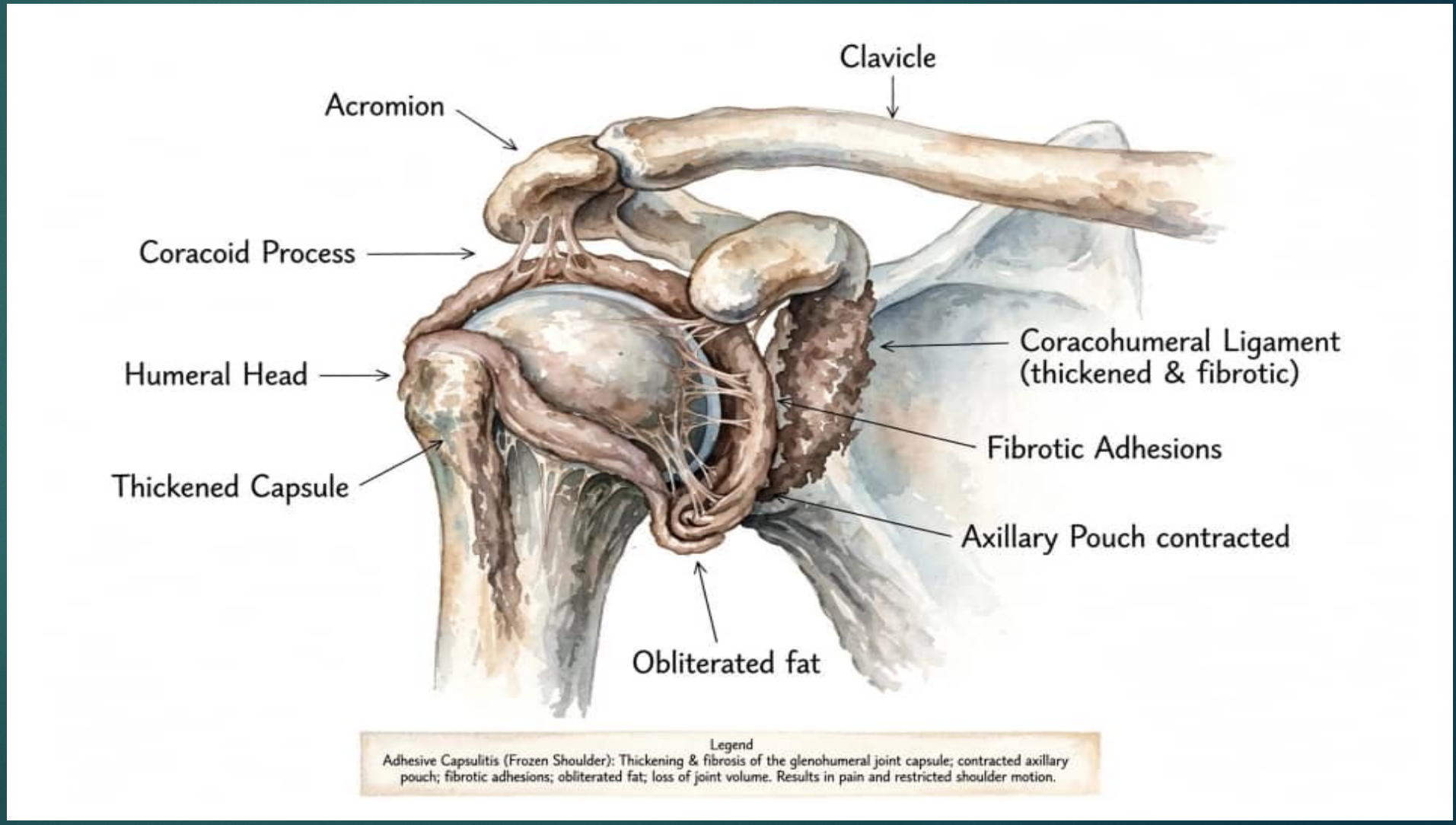

QUADRANGULAR SPACE

Qn7- A 38-year oldweightlifter complains of shoulder pain and weakness in abduction. Examination shows atrophy of the deltiod and sensory loss over the lateral upper arm. MRI demostrates compression of the nerve and an artery in the quadrangular space, what are these structures

Anatomical boundaries of the quadrangular space

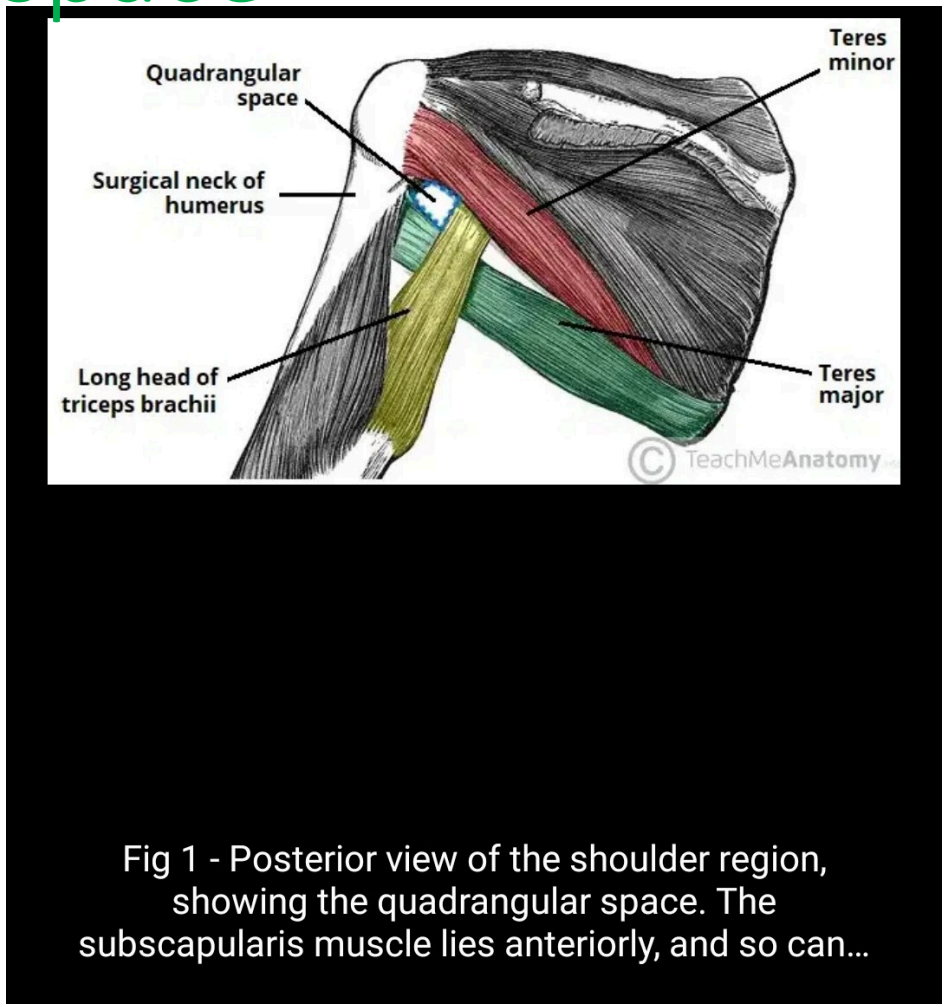

Fig 1 - Posterior view of the shoulder region, showing the quadrangular space. The subscapularis muscle lies anteriorly, and so can...

- superior border;inferior border of the teres minor muscle
- inferior border;superior border of the teres majormuscles
- medial border;long head of the triceps branchii
- lateral border;surgical neck of the humerus

structures of the quadrangular space

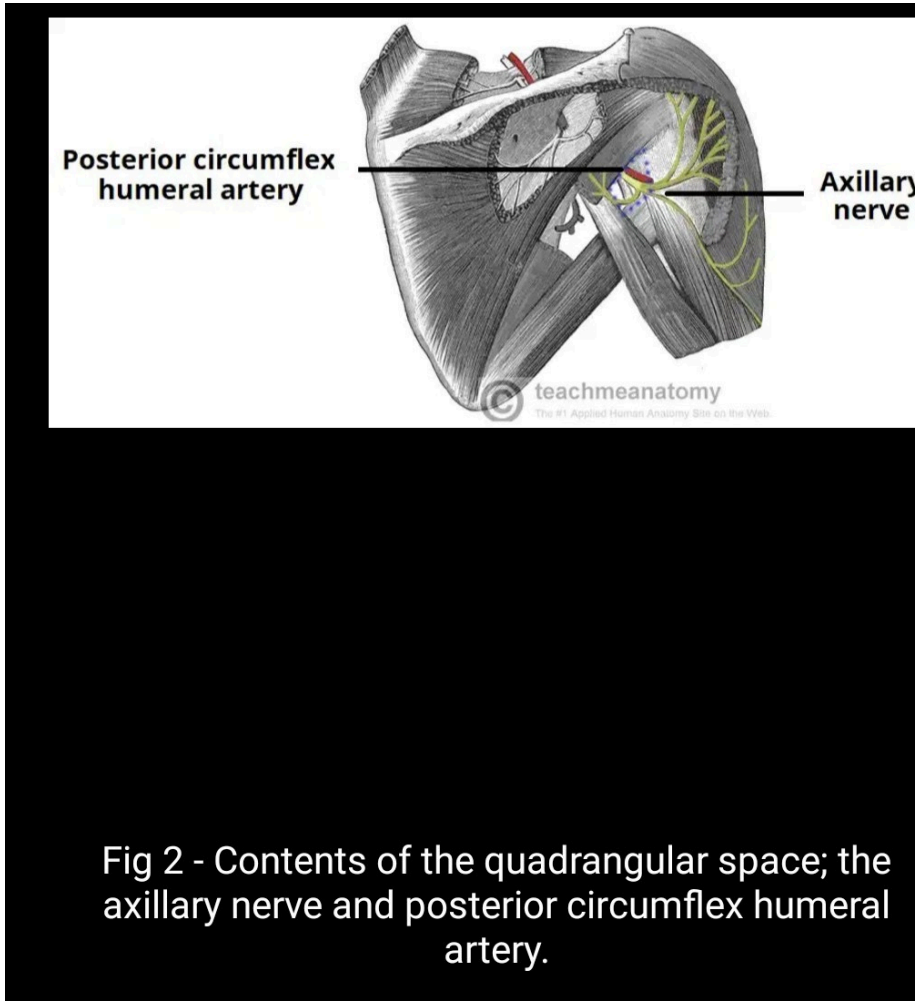

Fig 2 - Contents of the quadrangular space; the axillary nerve and posterior circumflex humeral artery.

- Axillary nerve;innervets thedeltoid and the teres minor muscles and provides cuteneous sensation over the lateral shoulder compression or injury lead to atrophy of the deltoid and loss of sensation over the lateral upper arm
- Posterior circumflex humeral artery;Travels alongside the axillary nerve through the space to supply the shoulder joint and sorrounding muscles

Quadrangular space syndrome

- Frequently seen in overhead athletes or weightlifters due to repetitive arm movements or muscular hypertrophy causing entrapment 0f the axillary nerve and posterior circumflex humeral artery

WELCOME TO TUTORIAL 2

Qn. 1: A 3-day-old newborn delivered with shoulder dystocia presents with the left arm adducted, medially rotated and extended at the elbow ("waiter tip deformity). The grasp reflex is intact. Diagnosis?

Presentation by: NAMULINDWA ASMART

Reg. No: EQ26/BDS/AUG/0018D

Diagnosis:

- ✓ *Erb's Paralysis /Palsy (*lesion of the upper trunk of the brachial plexus i.e. C5 & C6 roots).
- ✓ Affects all nerves from the C5 & C6 roots together with the muscles they innervate.

❖In infants, it is commonly caused by traction of the upper trunk in a way of managing shoulder dystocia during child delivery.

Cause- Shoulder Dystocia

Is an emergency during child delivery where the baby's head comes out, but one or both of the shoulders gets stuck behind the mother's pubic bone.

Signs of Shoulder Dystocia.

- ✓ Turtle sign; Delayed delivery of baby's body;

Common Risk Factors.

- ✓ Fetal macrosomia ; Maternal diabetes
- ✓ Previous history ; Labor induction

Complications.

- ❖ ***For Baby:***
- ✓ **Temporary or permanent brachial plexus injury/palsy.**
- ✓ Fractured clavicle or arm.
- ❖ ***For Mother:***
- ✓ Postpartum hemorrhage and deep tears.

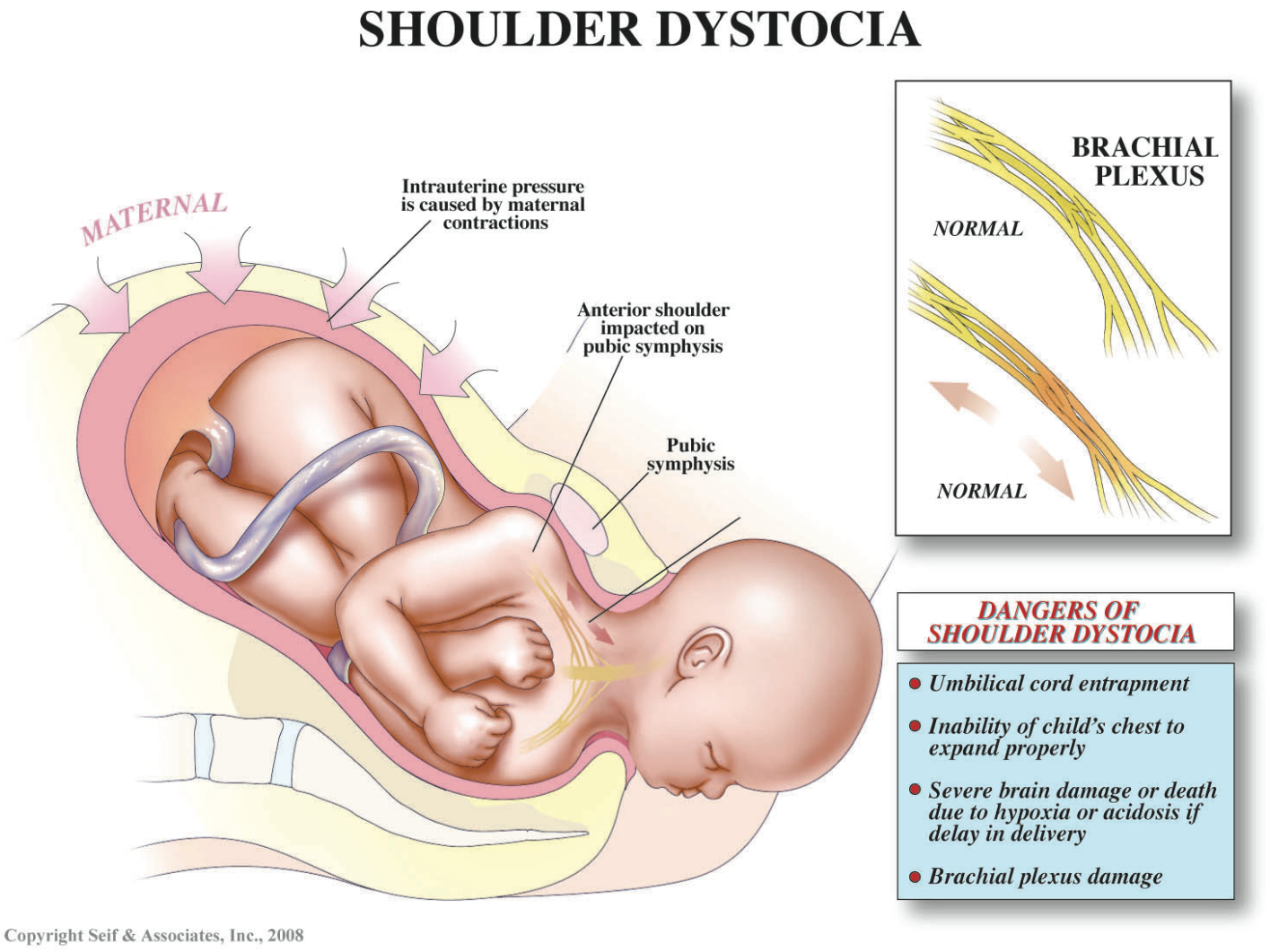

Deformity- Erb’s Paralysis/ Palsy

Refers to lesion of the upper trunk of the brachial plexus (C5 & C6).

Caused by:

- ✓ Violent traction of the head of the fetus during delivery.

Causes:

- ✓ Adduction of the arm.
- ✓ Extension at the elbow.
- ✓ Medial rotation of the arm.

Deformity:

- ✓ Policeman’s tip position / waiter’s tip posture



Qn.2: A 28-year-old woman sustains a fall while hanging from a tree branch. She presents with weakness of the intrinsic hand muscles and clawing of the fingers. She also has sensory loss along the medial fore arm and hand. Diagnosis?

Presentation By: AMITO VIOLA

Reg No: EQ26/MBChB/ AUG/ 0030D

Diagnosis: Klumpke's paralysis (Lower trunk lesion i.e. C8 & T1)

Cause: Traction- hanging from tree branch pulls lower trunk of brachial plexus.

Results to: Paralysis of the intrinsic muscles of the hand i.e.

- interossei
- lumbricals 3 & 4
- thenar
- hypothenar

Also, wrist flexors weaken i.e. flexor carpi ulnaris and medial half of flexor digitorum profundus.

Sensory examination of medial forearm and hand: C8-T1 dermatome, medial cutaneous nerve of forearm and ulnar nerve are injured.

Deformity: Claw hand.

Ulnar nerve injury alone; causes ulnar claw i.e. ring and little fingers only.

C8-T1 lesion causes total claw i.e. all fingers.

CAUSE OF KLUMPKE'S PARALYSIS



DEFORMITY



Related comment:

- ✓ Fall from a tree while catching branch causes forced hyper abduction of the arm which results to traction on lower trunk.
- ✓ C8-T1 lesion results to total clawing of fingers.

Management:

- ✓ Physiotherapy; Prevents contractures and splint hand in functional position.

NOTE:

Don’t just look at the hand, look at the eye and the pulse because T1 nerve is pressure

Associated signs

- ✓ Horner’s syndrome
- ✓ Vascular injury i.e. check radial pulse.

Wrist Drop

Presented by

WATERA EVELYN FAITH

EQ26/MBChB/AUG/0036D

TUTORIAL 2 - QN3

A 42-year-old man falls asleep drunk with his arm draped over a chair. On waking, he cannot extend his wrist or fingers and has numbness over the dorsum of the hand. diagnosis

Wrist drop occurs when the muscles that extend the wrist and fingers become weak or paralyzed, most commonly because of radial nerve injury and sensory involvement of the radial nerve.

Site; Compression in the radial groove of the humerus.

Signs

Inability to extend the wrist

Difficulty in extending the fingers and thumb

Weak grip, because effective wrist stabilization is lost

Weakness of supination

Reduced sensation over the dorsolateral hand, especially the first dorsal web space.

Treatment



Use wrist splint to keep the wrist in a functional position and prevents stiffness



Do gentle exercise to keep the wrist and fingers moving



Rest the arm and avoid pressure on the radial nerve



Surgery maybe considered when there is a severe injury, nerve entrapment, or failure to recover appropriately.y

EQ26/BDS /AUG/0007D

Musoke Claudia

Tutorial 2;
Number 4.

A 27 year old motorcyclist sustains a humeral shaft fracture. He presents with wrist drop and loss of sensation over the dorsal web space between the thumb and index finger. Diagnosis?

Humeral shaft fracture can injure the radial nerve as it winds around the posterior humerus in the radial groove.
The radial nerve travels closely against the bone in the spiral groove of the mid to distal humerus.
This nerve is highly vulnerable to stretching when the humeral shaft breaks.

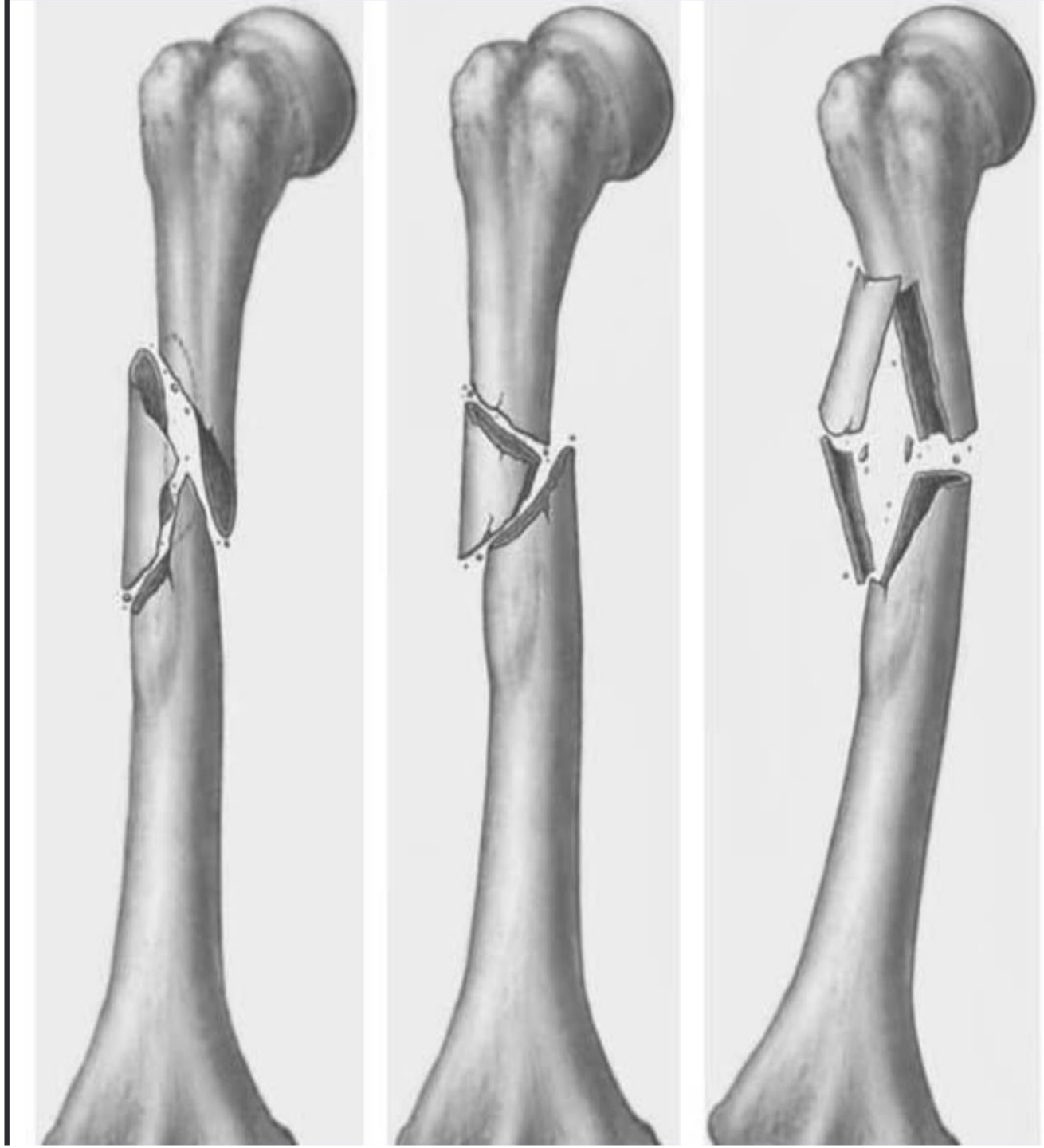

Diagnosis;
Radial nerve palsy associated with mid shaft humeral fracture (holstein-lewis) type injury if the fracture is in the distasl third of the humerus.

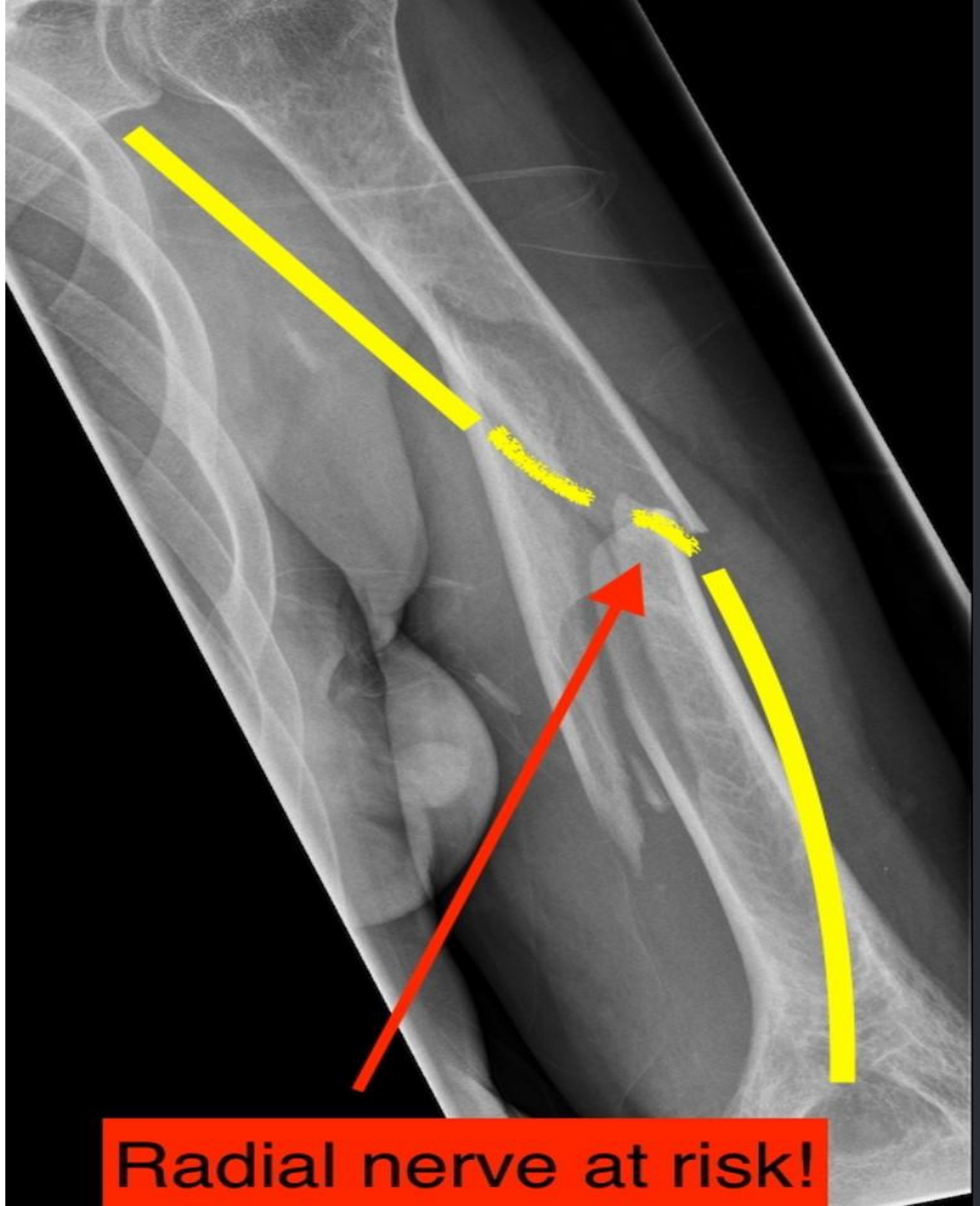

Wrist drop; caused by the inability to extend the wrist and fingers due to radial nerve dysfunction.

Sensory loss; affects the dorsal web space between the thumb and index finger, corresponding to the cutaneous distribution of the superficial branch of the radial nerve.

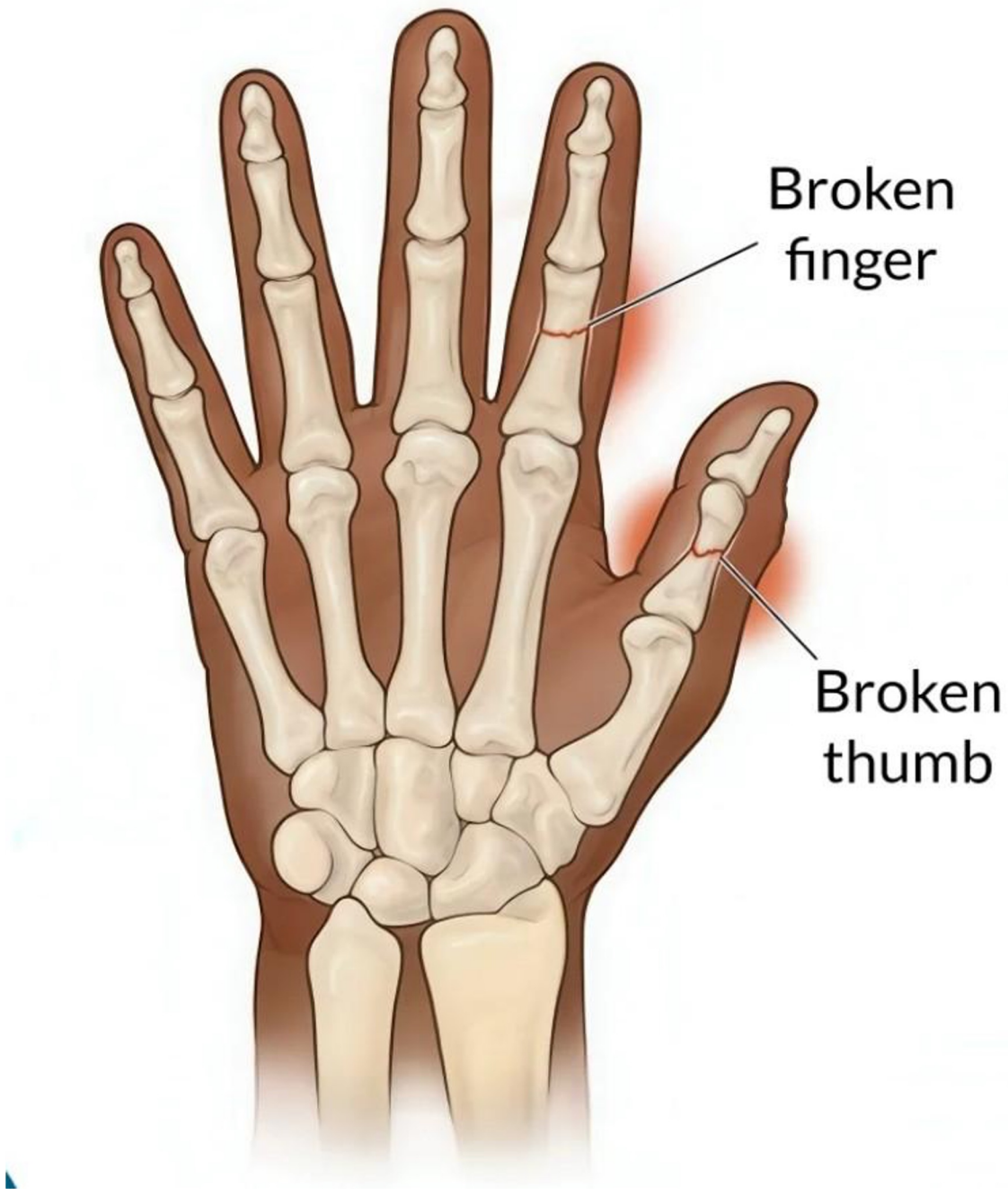

TUTORIAL 2 QN 5

Voltmans ischemia
Fore arm ischemia
Radial artery injury

POPEYE'S DEFORMITY

Presented by;
NINSIIMA LINDA
EQ26/AUG/BDS/0002D

Question 6 : A 55 year old man lifting a heavy object hears a sudden ‘pop’ in his arm. Examination reveals a bulge in the anterior arm (Popeye deformity) and weakness of fore arm supination. Diagnosis?

- Popeye sign or deformity, characterised by a bulge on the anterior copartment of the brachium as in the cartoon character popeye.
- The sudden pop sound is due to rapture of the tendon of the long head of biceps brachii muscle that attaches on the supraglenoid tubercle.

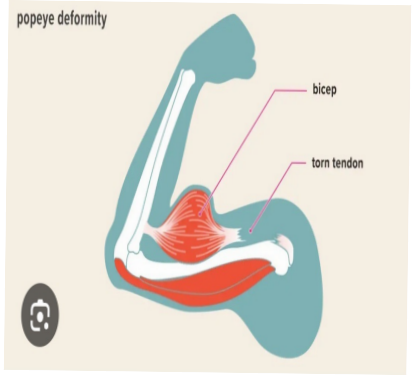

Biceps brachii in supination

- The biceps brachii is a powerful supinator of the fore arm since it inserts at the radial tubercle.
- Rapture of the biceps brachii tendon therefore results in weak and painful supination of the upper arm.

.....END.....

TUTORIAL 2 QUESTION 7

EZARU JULIET EQ26/MBCHB/AUG/0046D

QN. A 32-year-old man is stabbed in the upper arm. He has weakness of the elbow flexion and supination, and sensory loss over the lateral forearm. Diagnosis?

DIAGNOSIS: **INJURY TO THE MUSCULOCUTANEOUS NERVE**

- ✓The musculocutaneous nerve is a terminal branch of the lateral cord of the brachial plexus (C5-C7).The clinical findings in the patient strongly indicates injury to this nerve.
- ✓The musculocutaneous nerve supplies the 3 muscles of the anterior compartment of the forearm; Bicep brachii, Brachialis, coracobrachialis.
- ✓The Biceps brachii is a powerful supinator of the forearm, particularly when the elbow is flexed. Therefore, damage to this nerve weakens forearm supination

NB.

- supination is not completely lost because the supinator muscle, supplied by the deep branch of the radial nerves(supinator) can still perform the movement.
- flexion is weak but can still be performed by pectoralis major and brachioradialis respectively.

SENSORY LOSS OVER THE LATERAL FOREARM.

- ✓ After supplying the muscles of the anterior arm, the musculocutaneous nerve continues as **the lateral cutaneous nerve of the forearm .**
- ✓ **T**his nerve provides sensation to much of the skin of the lateral aspect of the forearm.
- ✓ Therefore, injury to the musculocutaneous nerve specifically the lateral cutaneous nerve of the forearm produces sensory loss over the lateral forearm.

MANAGEMENT

- Urgent Surgical Exploration
- Nerve Repair
- Physical therapy and follow up
- Wound care and infection management.

IILUSTRATIONS

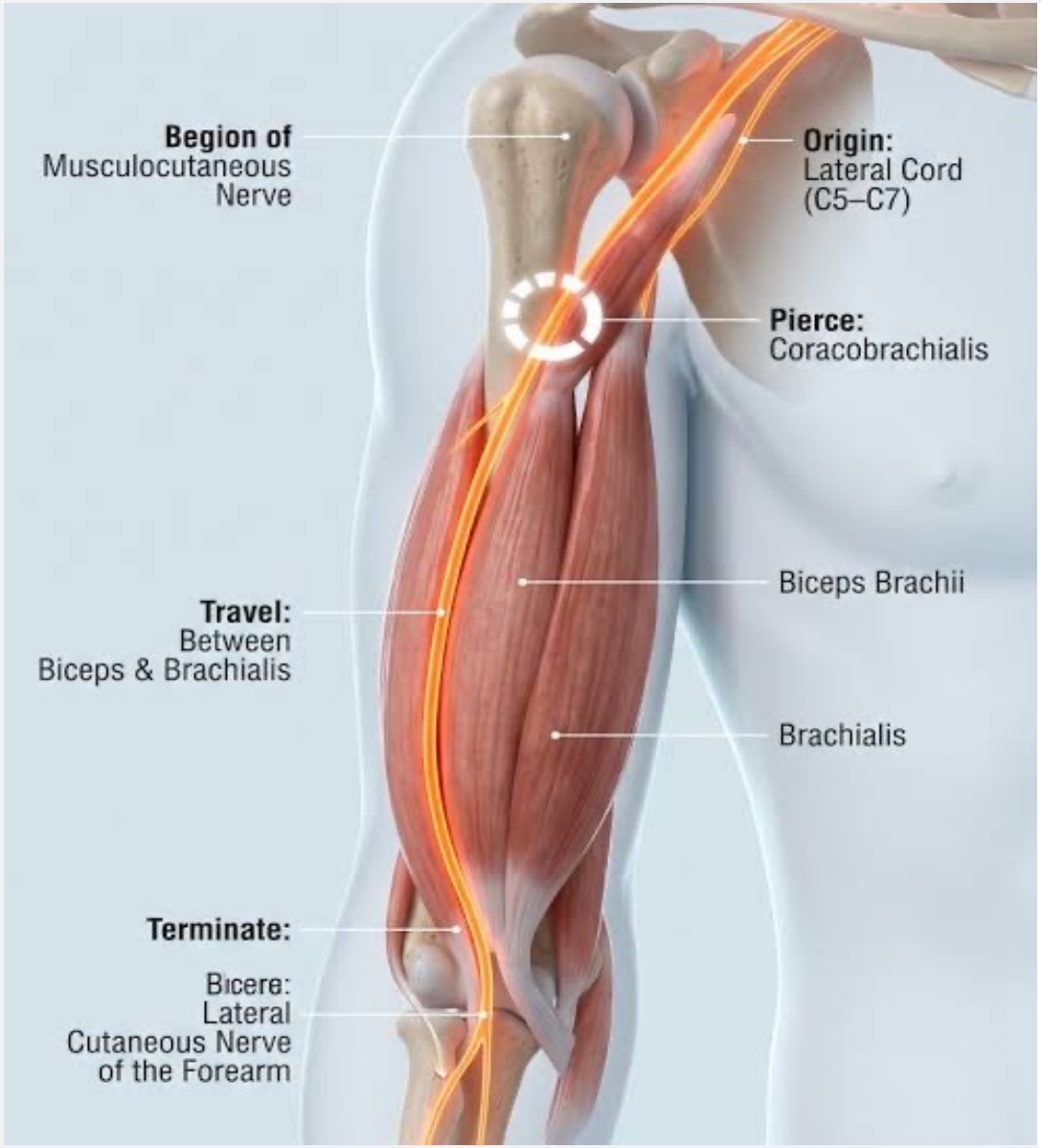

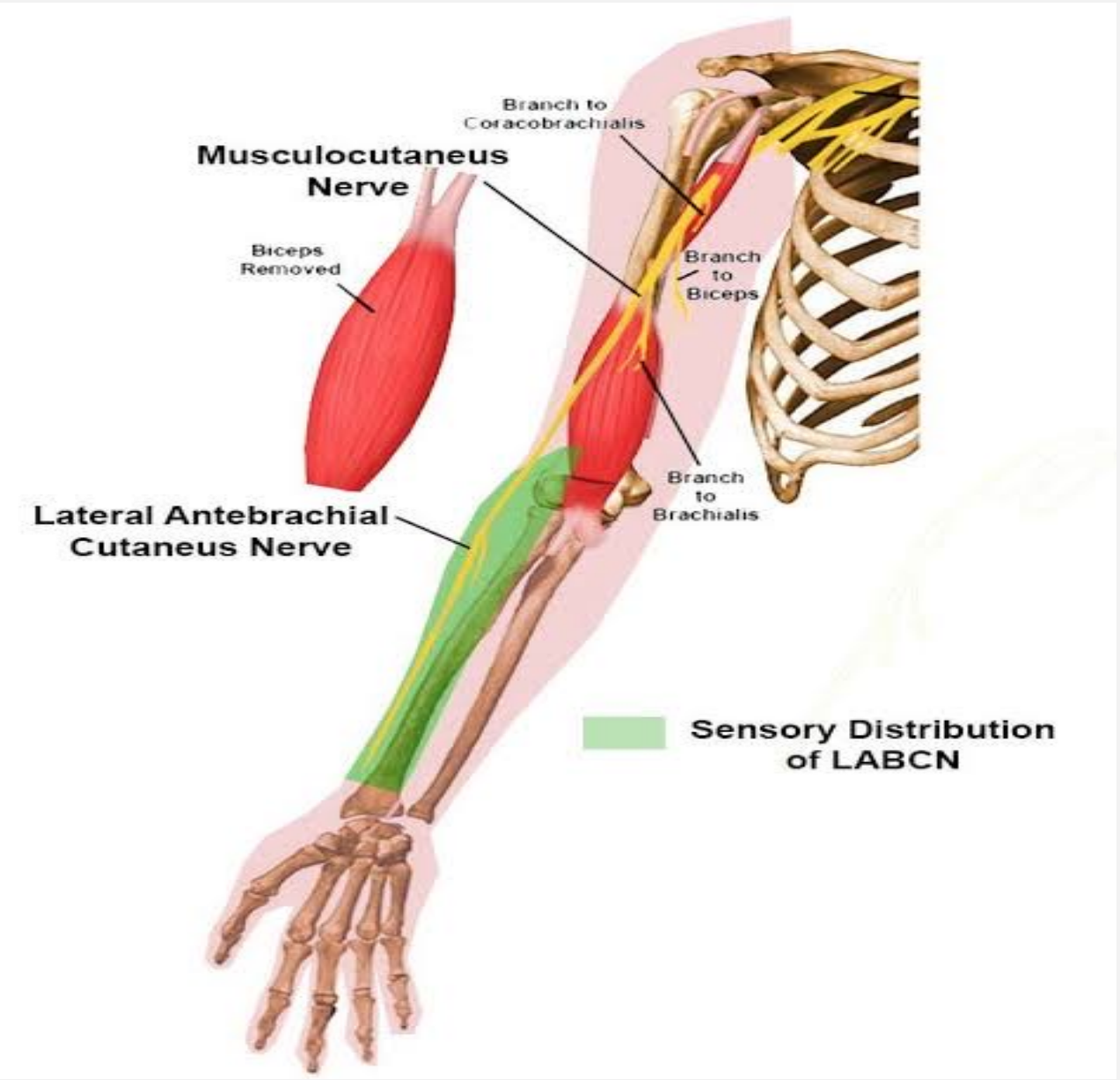

Venipucture pain/Numbness of the median cubital vein

PRESENTER: NAMATOVU MARGARET ROVINCE

EQ26/MBCHB/AUG/0024D

Anatomy of the Median Cubital Vein (Snell's Emphasis

- The median cubital vein (MCV) is a superficial vein in the cubital fossa that connects the cephalic and basilic veins in an oblique, often "N" or "V" shaped pattern.

- It lies 2–3 mm below the skin and is well anchored by the bicipital aponeurosis, making it less likely to roll during needle insertion.

- Snell's notes that the MCV is the vein of choice for venipuncture because it is large, accessible, and has fewer nerve endings in its immediate vicinity, resulting in less pain for the patient.

Location of the median cubital vein

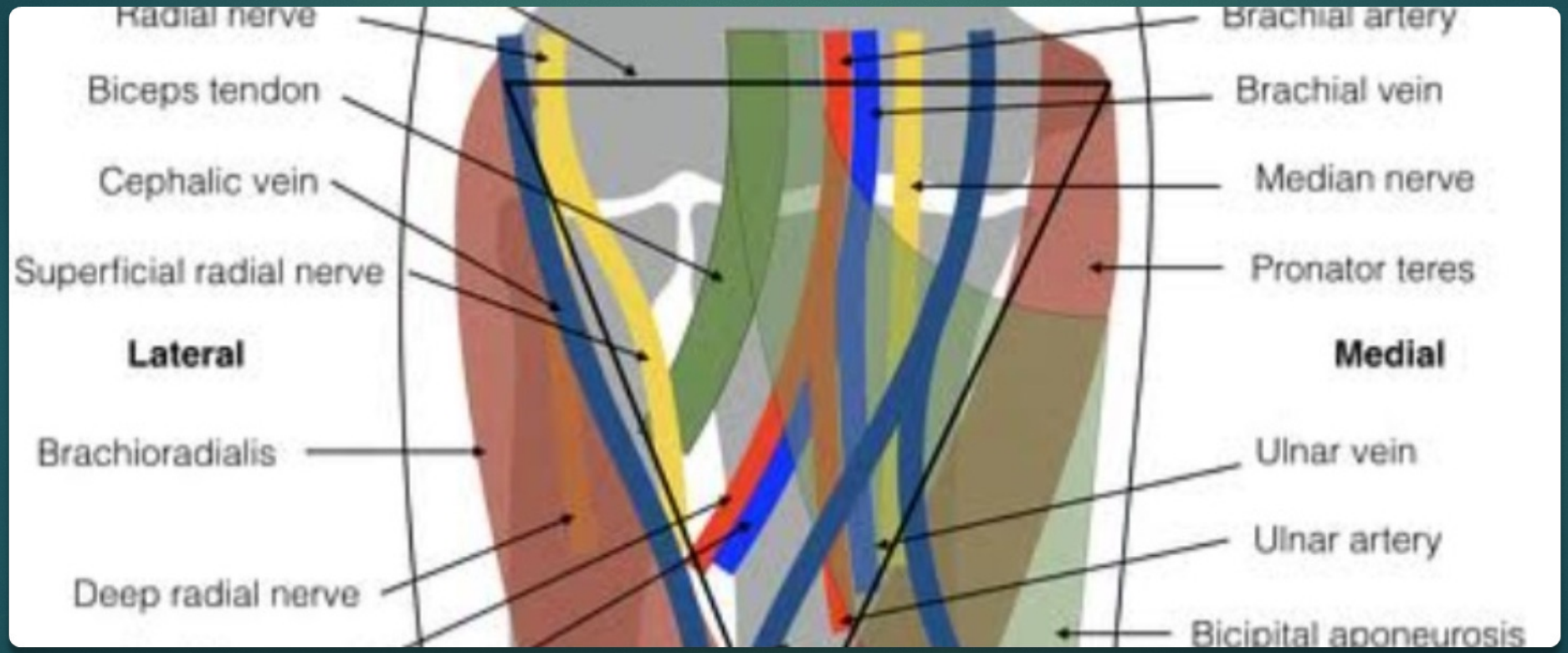

Venipuncture at the MCV

- It is Usually Less Painful because of fewer somatic nerve endings surrounding the median cubital vein compared to other antecubital veins (e.g., cephalic or basilic). · This anatomical feature explains why routine blood draws at the MCV are typically described as minimally painful.

Causes of Numbness / Paresthesia after MCV puncture

- Despite its relative safety, nerve injury can occur if the needle deviates or if anatomical variations exist
- Medial Cutaneous Nerve of the Forearm (MCNF)

- Lateral Antebrachial Cutaneous Nerve (LACN) · This lies immediately lateral to the biceps tendon and just behind the antecubital veins. · Puncture of the cephalic vein or lateral aspect of the MCV can injure the LACN, causing lateral forearm paresthesia

Causes of Numbness / Paresthesia after MCV puncture (Continuation)

- Median Nerve (Deep) · This lies deep to the bicipital aponeurosis and is not normally at risk during routine superficial MCV puncture. · However, excessively deep needle insertion or anatomical variations (e.g., MCV traveling deep to the aponeurosis) could cause the median n injury of the nerve, leading to post-phlebotomy paresthesia

- Symptoms are usually self-limited (resolving in 1 week to 6 months), but permanent injury has been reported

Safe Venipuncture Site (Snell's Clinical Correlation

- Best site: The middle segment of the MCV, near its junction with the cephalic vein, is considered the least likely to cause nerve damage.
- Avoid: The ulnar (medial) portion of the MCV and the basilic vein because the MCNF passes in close proximity there.
- Technique tip: Use a shallow angle (15–30°) and avoid deep probing to minimize nerve contact

Summary Table (Snell's Key Highlights)

Nerve	Structure Relation to MCV	Risk During Venipuncture	Resulting Symptom
Medial cutaneous nerve of forearm	Crosses MCV (superficial or deep)	Moderate–high	Medial forearm numbness, tingling
Lateral antebrachial cutaneous nerve	Lateral to biceps tendon, behind veins	Moderate	Lateral forearm paresthesia
Median nerve	Deep to bicipital aponeurosis	Low (unless deep puncture)	Hand paresthesia (rare)

Conclusion

- The median cubital vein is the preferred venipuncture site because it is large, well-anchored, and has fewer nerve endings, making it less painful.
- However, the medial cutaneous nerve of the forearm and less commonly the lateral antebrachial cutaneous nerve may be injured, leading to numbness or paresthesia. Puncturing the MCV near the cephalic vein reduces this risk.

THE CUBITAL FOSSA

PRESENTATION BY ISABEL ANGELLA NASSUNA

EQ26\MBChB\AUG\0028D

Tutorial 2 - Qn.9

A 19 year old man presents with profuse bleeding after a deep knife wound in the cubital fossa. Distal pulses are absent. Diagnosis.

A quick review of what a cubital fossa is and what makes it up.

- **It's a triangular depression on the anterior aspect of the elbow. Its also a transitional zone between the arm and the fore arm**
- **Boundaries**

- **Superior base** –medial and lateral epicondyle
- **Medial boarder** – lateral border of pronator teres muscle
- **Lateral boarder-** medial border of brachioradialis muscle
- **Apex** – point of intersection of brachioradialis and pronator teres
- **Floor** –brachialis medially and supinator laterally
- **Contents** – radial nerve, median nerve, median cubital vein, cephalic and basilica vein, brachial artery and biceps brachii tendon.

GROSS ANATOMICAL VIEW

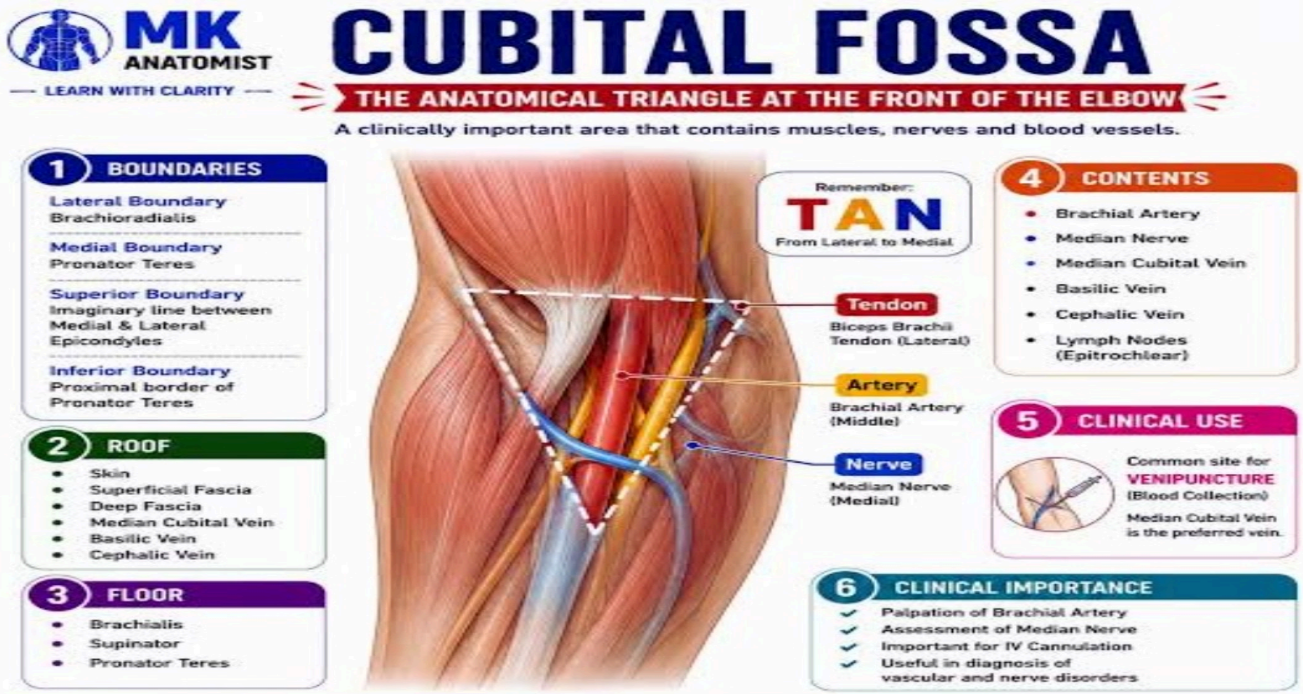

KEY NOTES TO TAKE

- Deep knife wound to the cubital fossa
- Profuse bleeding which suggests injury to a major artery
- Distal pulses absent indicates severely reduced or interrupted blood flow to the forearm and the hand.

- STRUCTURES AT RISK

- Brachial artery it’s a major blood vessel
- Median nerve its an important of forearm and the hand
- Biceps tendon it’s a muscle tendon crossing the fossa

DIAGNOSIS

- Brachial artery ***laceration***(torn or cut nerve but still in one piece) or ***transection***(completely severed or cut way through into two pieces)
- This results into acute ***limb ischemia***(a sudden, rapid decrease in limb perfusion)
- The brachial artery passes through the cubital fossa and normally divides into the radial and ulna artery
- Therefore injury to the brachial artery can cause severe ***hemorrhage(severe or heavy bleeding)*** and loss of distal pulses`

- THANK U FOR LISTENING.

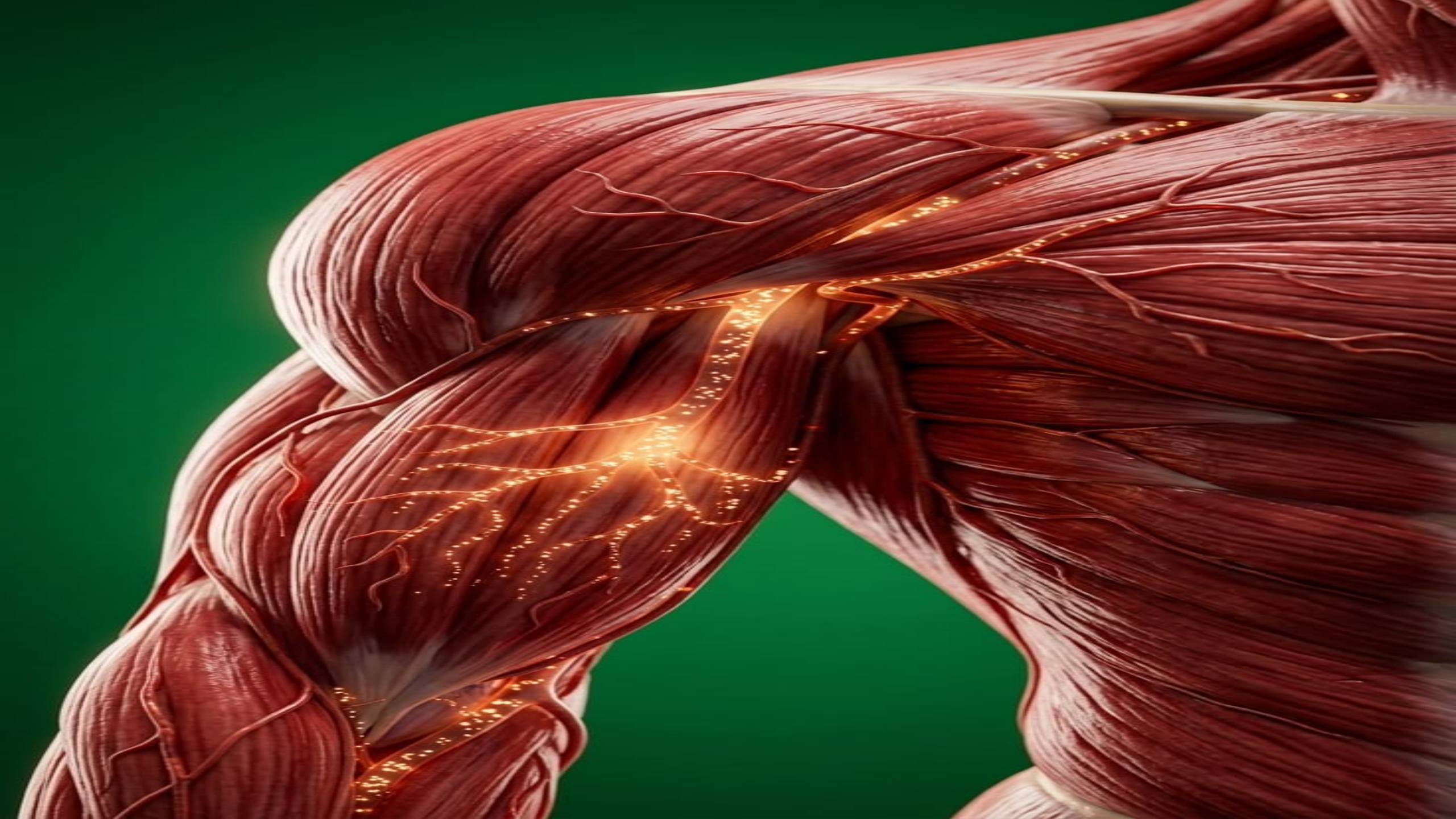

Qns; 10 of Tutorial 2

A 25- year old man suffers a penetrating wound at the cubital fossa, He presents with loss of forearm pronation, thenar muscle wasting and inability to flex the index and middle fingers(Hand of Benediction).Diagnosis?

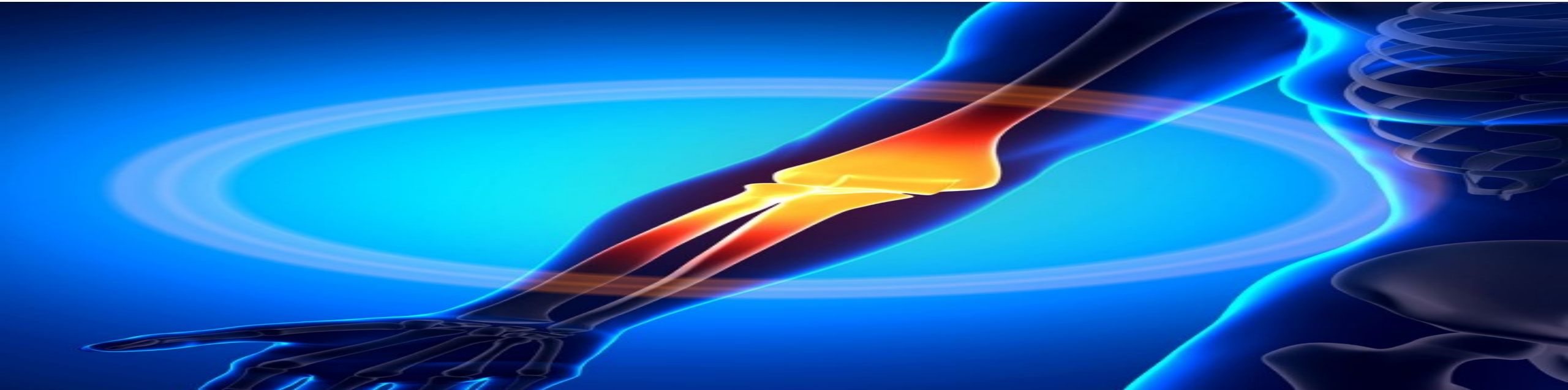

High median nerve injury at the cubital fossa

Contents of the Cubital Fossa

(From medial to lateral side)

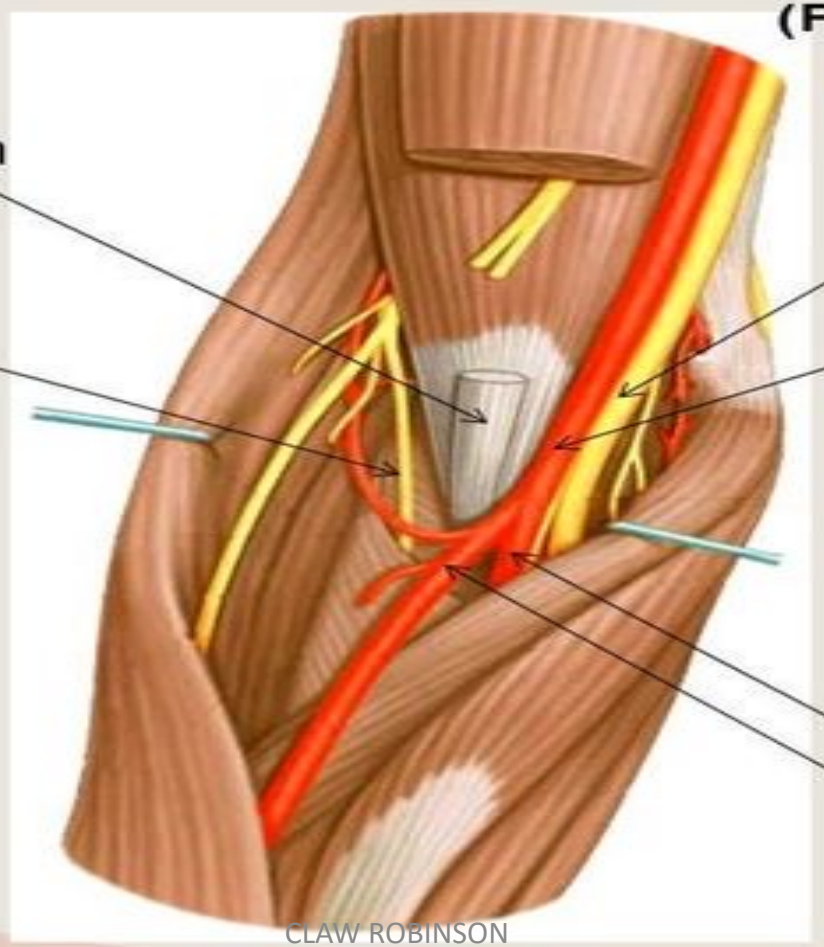

3. Biceps brachii tendon

4. Deep branch of radial nerve.

1. Median nerve.

2. Brachial artery, divides into radial and ulnar a., usually at apex of fossa

Ulnar a.

Radial a.

Loss of forearm pronation

Loss of pronator teres and pronator quadratus which are innervated by the median nerve(C6 & C7)

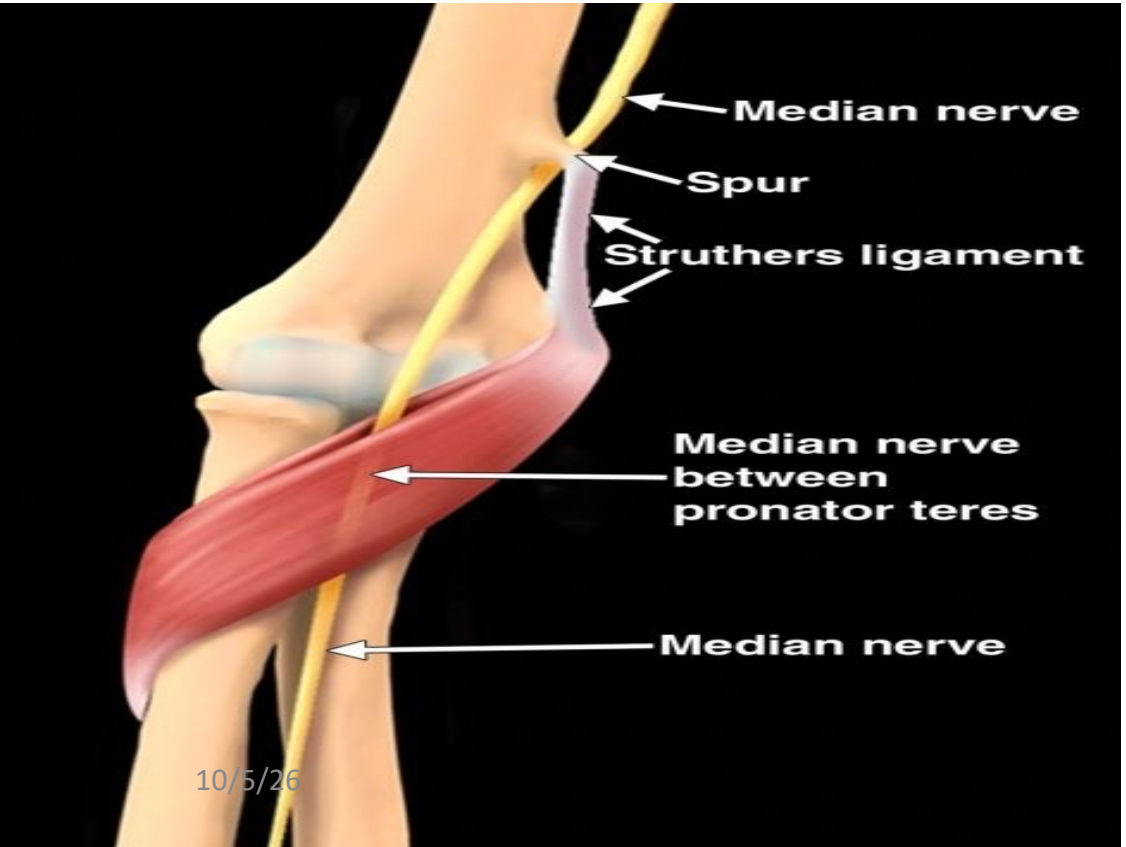

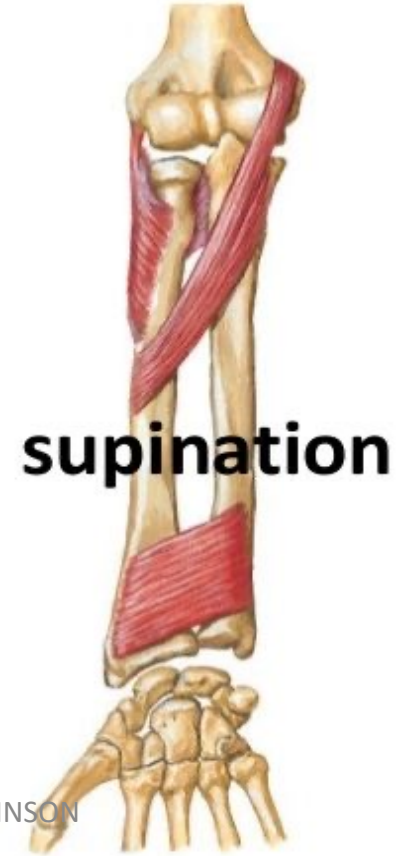

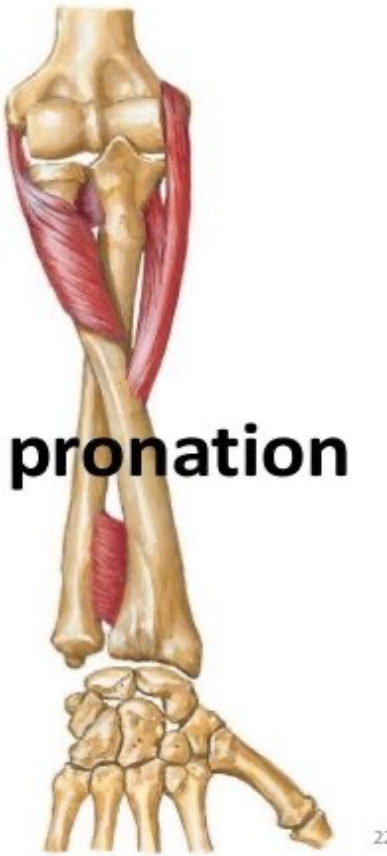

Inability to flex index and middle fingers-(Hand of Benediction)

Lateral half of flexor digtorum profundus and Flexor digitorum superficialis





Thenar muscle wasting.

This muscles are innervated by the recurrent branch of median nerve (Abductor pollicis brevis, opponens pollicis, and superficial head of flexor pollicis brevis)

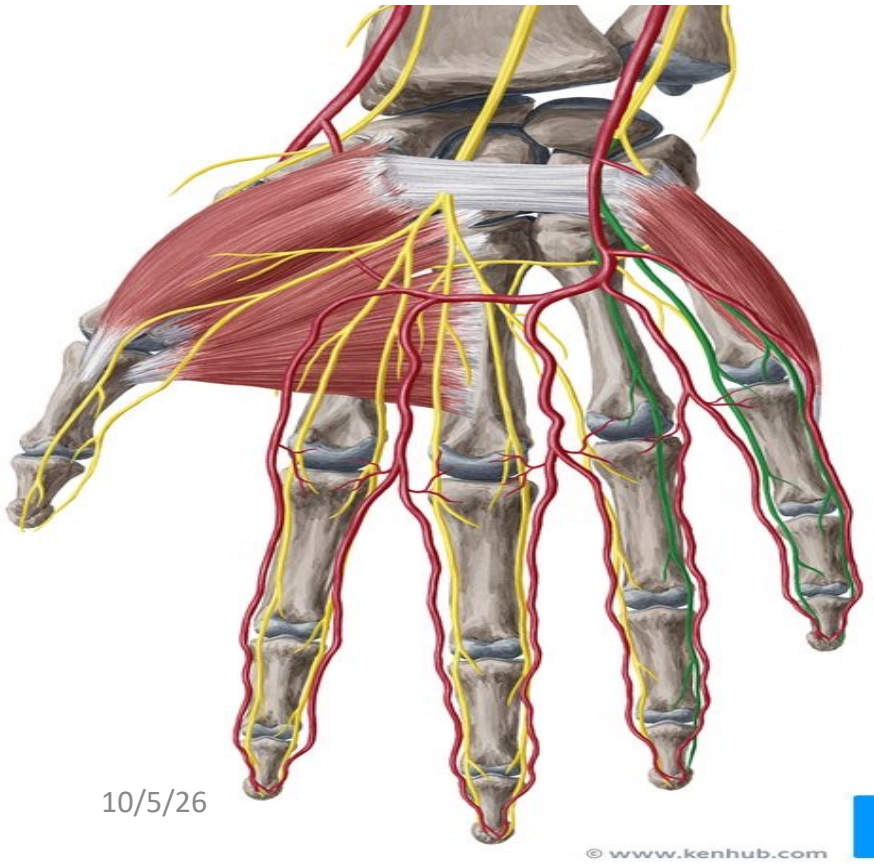

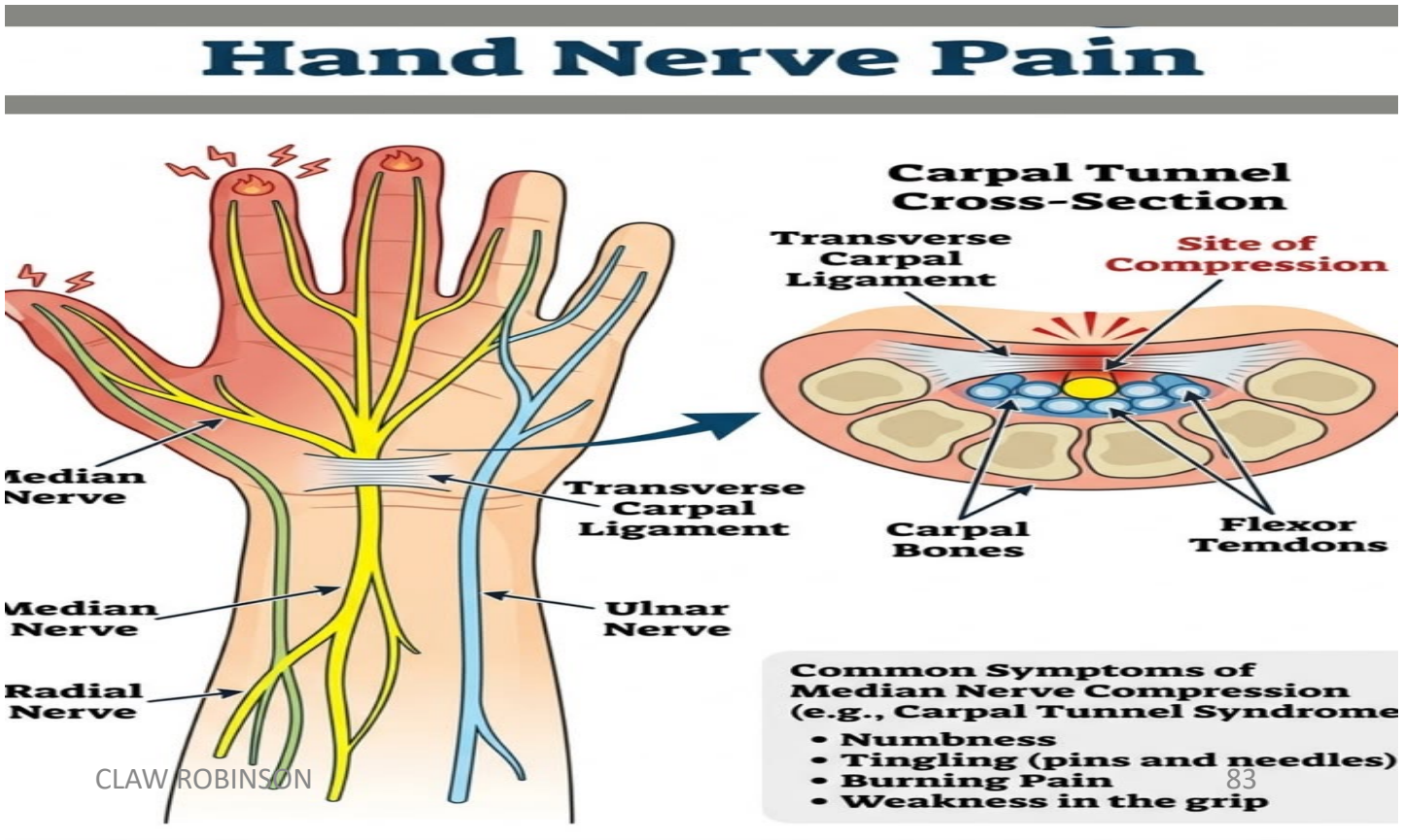

CLINICAL CASE PRESENTATION

Posterior Elbow Dislocation

Diagnosis, Injury Mechanism, and Critical Neurovascular Complications

FOOSH Trauma Pattern

Emergency Orthopedics

CLINICAL EVALUATION

Diagnosis & Mechanism of Injury

Primary Diagnosis

Acute Posterior Elbow Dislocation (Most common major joint dislocation after shoulder).

Mechanism (FOOSH)

Fall on outstretched hand with extended elbow and axial loading.

Key Physical Signs

Prominent posterior olecranon with severe deformity and loss of extension.

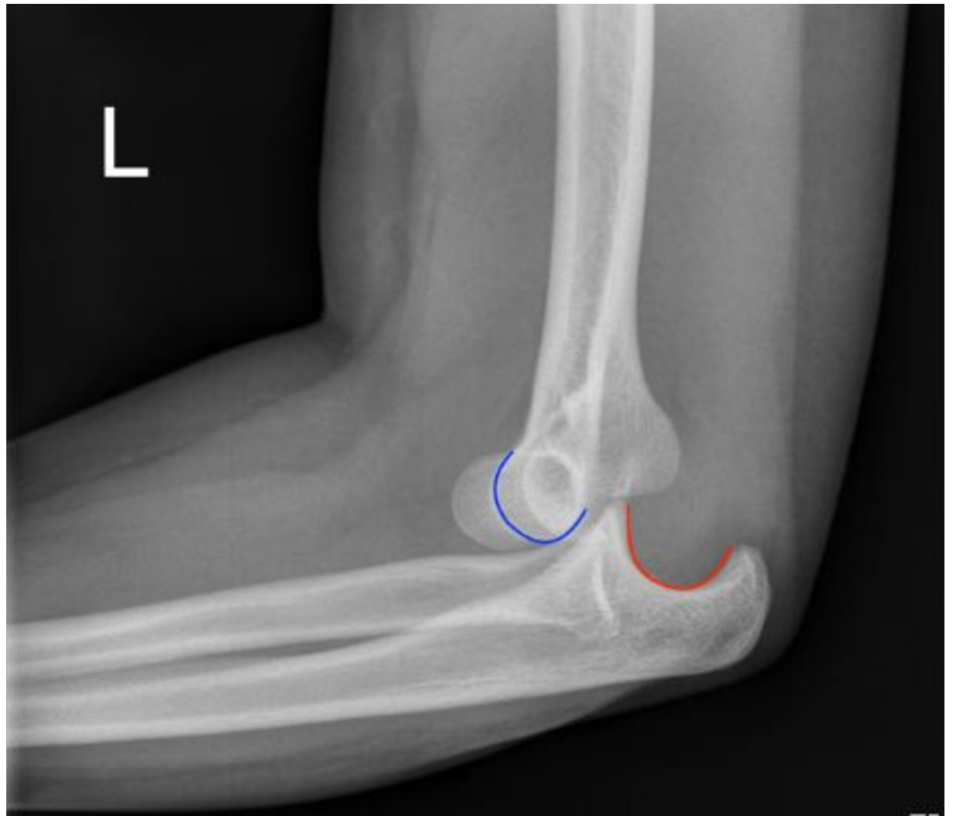

RISK ASSESSMENT

Possible Complications

Neurovascular Injury

Ulnar nerve stretch or traction neuropraxia.

Brachial artery entrapment or transection.

Compartment & Motion

Forearm compartment syndrome risk.

Joint stiffness and heterotopic ossification.

Instability & Fractures

Recurrent instability from LCL disruption.

Associated radial head or coronoid fractures.

TENNIS ELBOW (LATERAL EPICONDYLITIS)



Presented By:

NAMBOOZO PAULINE

EQ26/MBChB/AUG/0039D

TUTORIAL 3 QN2

Qn 2: A 30 year old tennis coach complains of progressive pain over the outer side of his right elbow for 3 months. The pains radiates down the lateral forearm and worsens when he grips his racket or shakes hands firmly. On examination, there tenderness at the lateral epicondyle, and resisted wrist extension reproduces the pain. Diagnosis?

Tennis elbow (Lateral Epicondylitis) is a tendon injury that causes pain and inflammation in the elbow.

It is an overuse tendinopathy involving the common extensor tendon at the lateral epicondyle, particularly the extensor carpi radialis brevis.

CAUSE:

- Repeated stress or overuse of forearm muscles

(continued pronation, supination, flexion and extension)

The repeated loading produces microtrauma and degeneration of the extensor tendons, particularly ECRB.

SIGNS AND SYMPTOMS

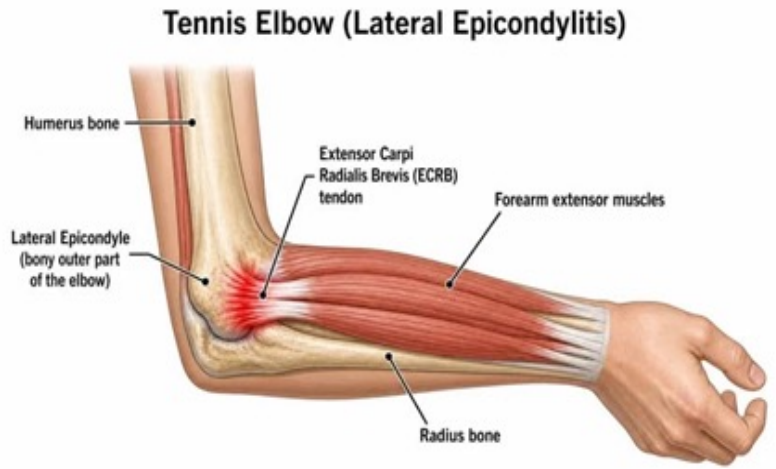

- Pain over the lateral elbow
- Pain radiates down the lateral forearm
- Tenderness over the lateral epicondyle

(Tendinopathy produces localized tenderness at or just distal to the lateral epicondyle.)

- Pain with gripping

(Strong grip – wrist extensors contract – ERCB is loaded – injured tendon is stressed – pain)

- Pain with shaking hands
- Pain increases with resisted wrist extension

(Resisted wrist extension – Contraction of extensor muscles – Tension at the lateral epicondyle – Reproduction of pain)

TREATMENT

- Rest and activity modification
- Physiotherapy
- Wearing a brace
- Ice
- Surgery

THANK YOU

GOLFER'S ELBOW (MEDIAL EPICONDYLITIS)

NANKYA SHAMILLAH

REG NO. EQ26/MBChB/AUG/0037D

TUTORIAL 3 QN.3

TUTORAIL 3 QN 3 . A 42 year old amateur golfer reports pain on the inner side of his right elbow that started after frequent practice swings. The pain radiates along the anterior forearm and is aggravated by throwing and lifting heavy objects, On examination there is tenderness over the medial epicondyle and resisted wrist flexion and forearm pronation reproduce the pain.Diagnosis?

Common overuse strain of common flexor origin at medial epicondyle. Causes medial

Elbow pain radiating to the anterior forearm,worse

On wrist flexion and pronation. Seen in golfers,

Throwers.

This is known as golfers elbow or medial epicondylitis

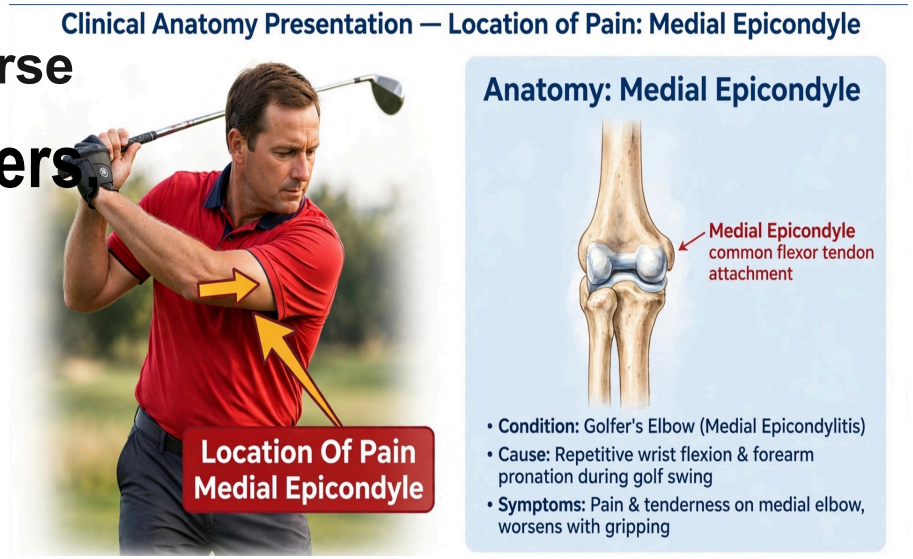

Symptoms and Treatment of Golfer’s Elbow

SYMPTOMS

- **Pain and tenderness on the inner side of the elbow(medial epicondyle)**
- **Pain worsens with wrist**
- **Stiffness and weakness in the affected forearm**
- **Discomfort when shaking hands**

TREATMENT

- **Rest& activity modification – avoid**

Aggravating motions

- **Ice application for 15-20min, several times daily**
- **Physiotherapy**
- **Surgery in severe, refractory cases**

Question 4: Case Breakdown & Diagnosis

CLINICAL SCENARIO

> "A 25-year-old man sustains trauma to the forearm. X-ray shows fracture of the proximal ulna with dislocation of the radial head. Diagnosis?"

DEFINITIVE DIAGNOSIS

Monteggia Fracture-Dislocation

- **Fracture Site: Shaft / proximal third of the ulna.**
- **Dislocation Site: Head of the radius at the radiocapitellar joint.**
- **Mechanism: Usually a Fall On Outstretched Hand (FOOSH) with excessive forearm pronation.**

M - U	G - R
Monteggia = **U**lna FX	**G**aleazzi = **R**adius FX

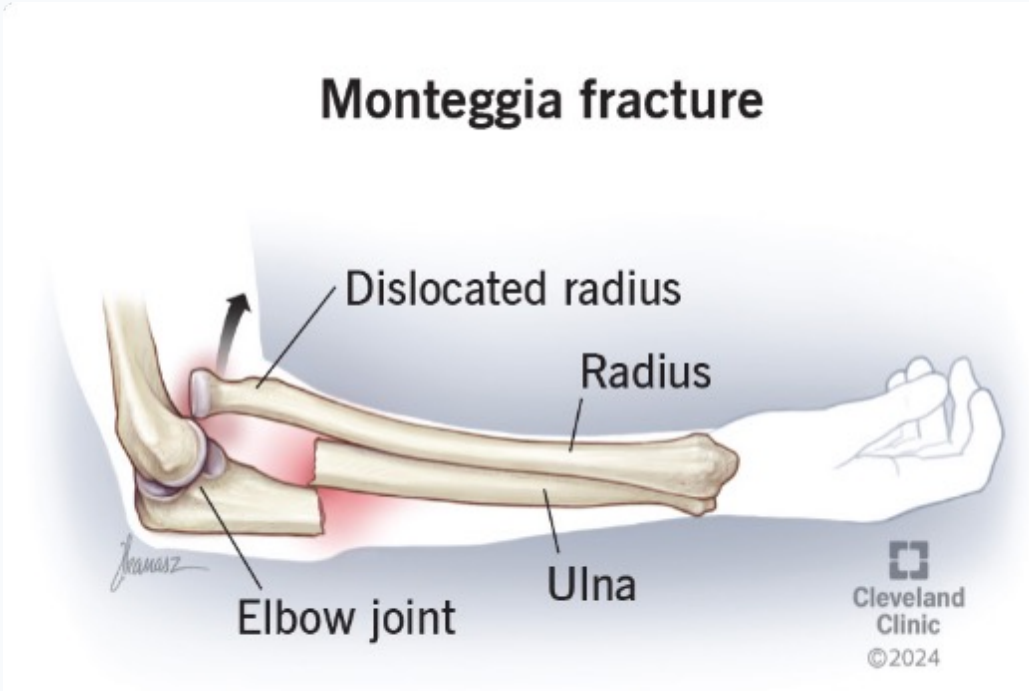

Bado Classification System

Type I (60%)

Anterior Dislocation (Most Common)

Anterior dislocation of radial head with apex-anterior angulation of the proximal ulnar fracture.

Type II (15%)

Posterior Dislocation

Posterior dislocation of radial head with apex-posterior ulnar fracture (common in older adults).

Type III (20%)

Lateral Dislocation

Lateral/anterolateral radial head dislocation with ulnar metaphyseal fracture (common in pediatrics).

Type IV (5%)

Combined Radius & Ulna FX

Anterior dislocation of radial head along with fractures of BOTH the proximal radius and ulna.

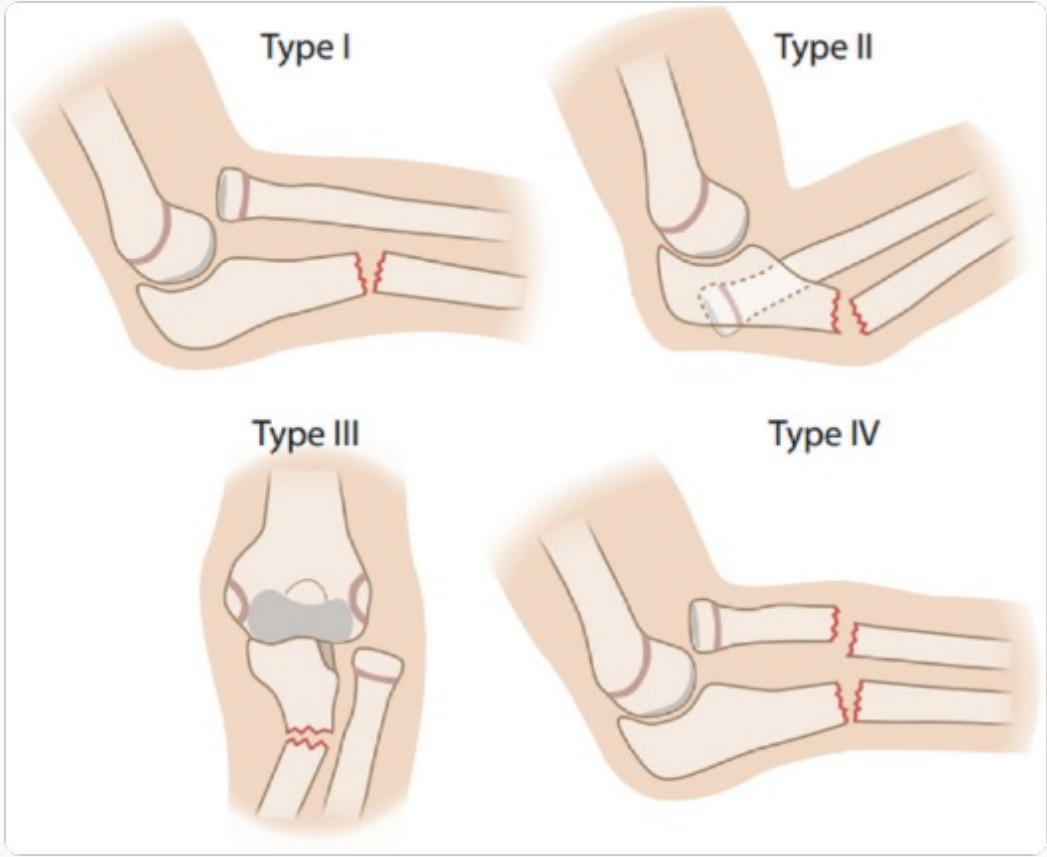

Radiography & Management Guidelines

Radiocapitellar Line Rule

A line drawn through the long axis of the radius must bisect the capitellum in ALL radiographic views. Non-alignment confirms radial head dislocation.

Nerve Injury at Risk

Posterior Interosseous Nerve (PIN) (branch of Radial Nerve). Causes weakness in finger & thumb extension (wrist drop without sensory loss).

Treatment Strategy

Adults: Requires urgent Open Reduction & Internal Fixation (ORIF) of the ulna with rigid plate construct.
Pediatric: Closed reduction + long arm cast.

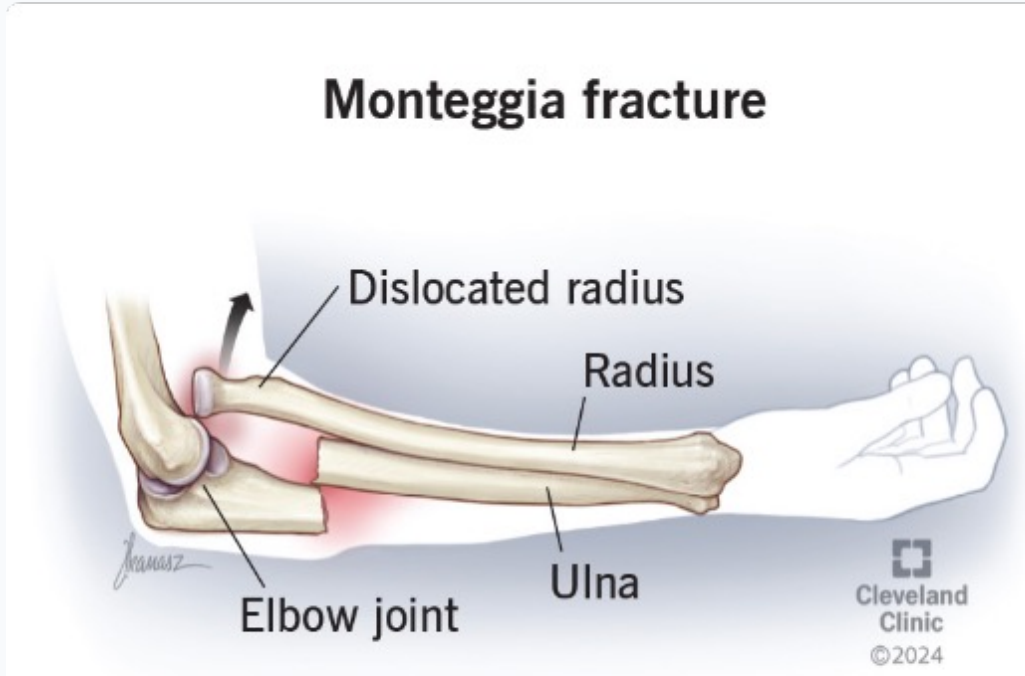

EQUATOR UNIVERSITY OF SCIENCE AND TECHNOLOGY

ANATOMY PRESENTATION

TOPIC: DISTAL RADIUS FRACTURE WITH DISTAL RADIOULNAR JOINT DISLOCATION

SUBMITTED TO: Dr. Musab N. Husein

SUBMITTED BY: Winifred L. Siaker

Eq26|MBChB|AUG|0045D

Tutorial 3 qn 5

Distal Radius Fracture With Distal Radioulnar Joint Dislocation

Distal Radius Fracture :is a forearm fracture in all ages group and 80% of people have this fracture often as the result from a fall on an outstretched hand.

Colle's Fracture: Is a fracture of the distal end of the radius resulting from a fall on the outstretched hand. It commonly occurs in patients older than 50years. The force drives the distal fragment posteriorly and superiorly and the distal articular surface is inclined posteriorly.

It's extension compression fracture of the distal ridus that produces a typical **"DINNER FORK"** deformity because the forearm and wrist resemble the shape of that eating utensil so failure to restore the distal articular surfaces to it's normal position will severly limit the range of flexion of the wrist joint.

SMITH FRACTURE

- ***Smith Fracture :*** Is a fracture of the distal end of the radius and it occurs from a fall on the back hand. It is a reversed colle's fracture because the distal fragment is displaced anteriorly . It also happens in all age group and 80% of have this fracture often as the result from a fall on an outstretched hand.

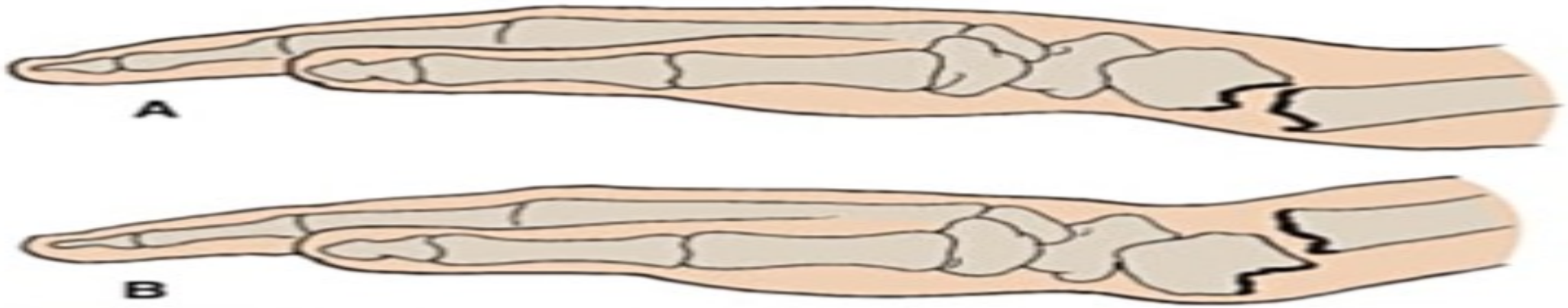

FIGURE 9.50 Fractures of the distal end of the radius. A. Colles' fracture. B. Smith's fracture.

DISTAL RADIOCULNAR JOINT DISLOCATION

- In a Galeazzi fracture (radial shaft fracture pulse distal radioulnar joint dislocation) Radial shortening tears the triangular fibrocartilage complex from its attachment or breaks the base of the ulnar styloid, and the joint dislocates . The joint capsule triangular fibrocartilage complex or extensor tendons like extensor carpiaulnaris can get caught in the joint and block reduction . An axial CT view shows the dislocation best of the distal radioulnar joint dislocation.
- Imaging : Use X-ray first ,then CT or MRI (Magnetic resonance imaging) to see the tendon triangular fibrocartilage complex and joint alignment.

DISTAL RADIOULNAR JOINT DISLOCATION

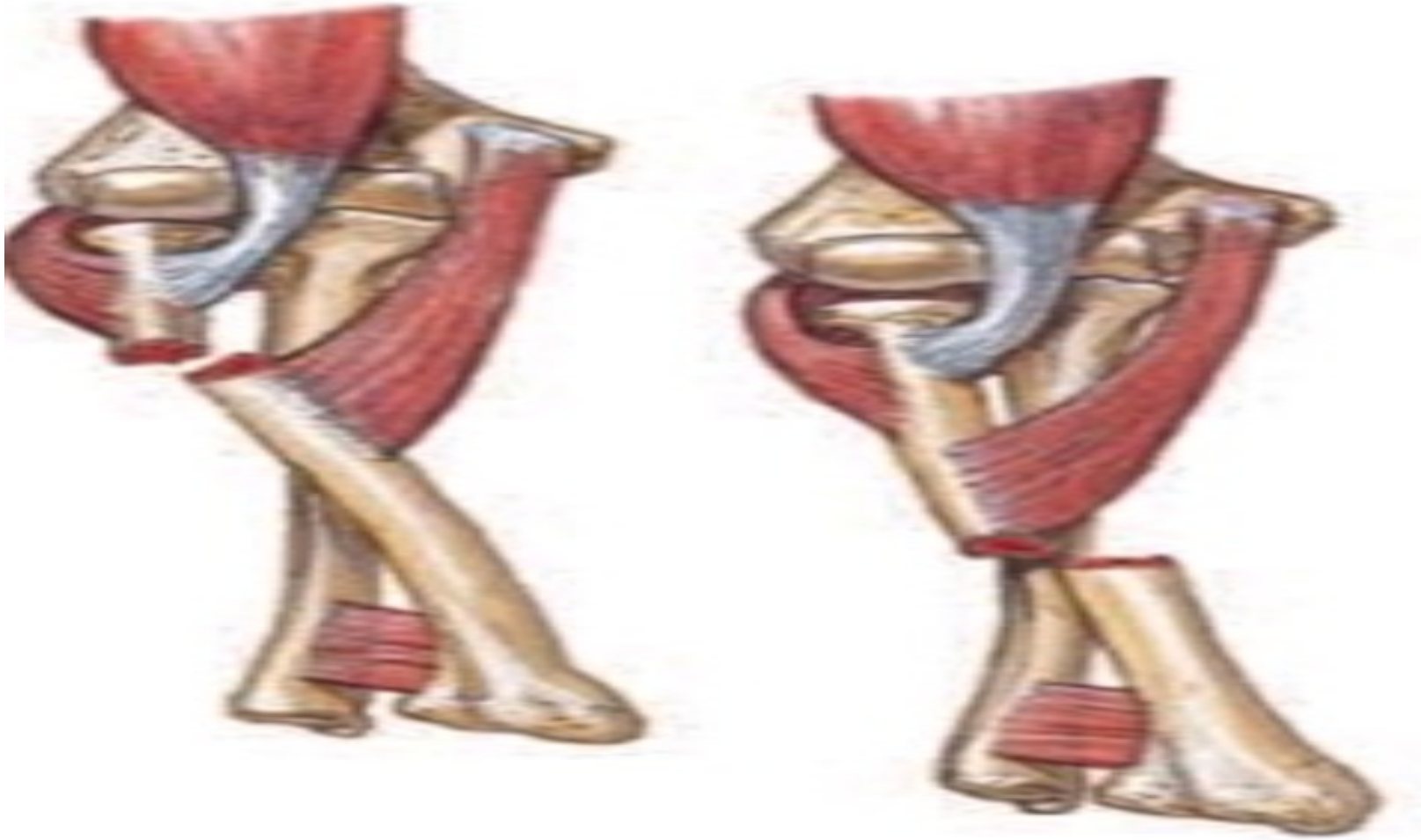

TUTORIAL 3 QUESTION NO. 6

PRESENTED BY

ARINDA LEAN KOMUHANGI

EQ26/MBChB/AUG/0041D

- This is referred to as Acute Compartment Syndrome of the Forearm.
- **Crush injury:** Direct muscle damage and bleeding in the forearm.
- **Severe pain:** Persistent and out of proportion to the injury.
- **Tense swelling:** The forearm feels firm and tight on palpation
- **Numb fingers:** Sensory loss from nerve ischemia

Acute compartment syndrome

- This refers to raised pressure inside a closed osteofascial space compromises the blood supply to the muscles and nerves it contains.

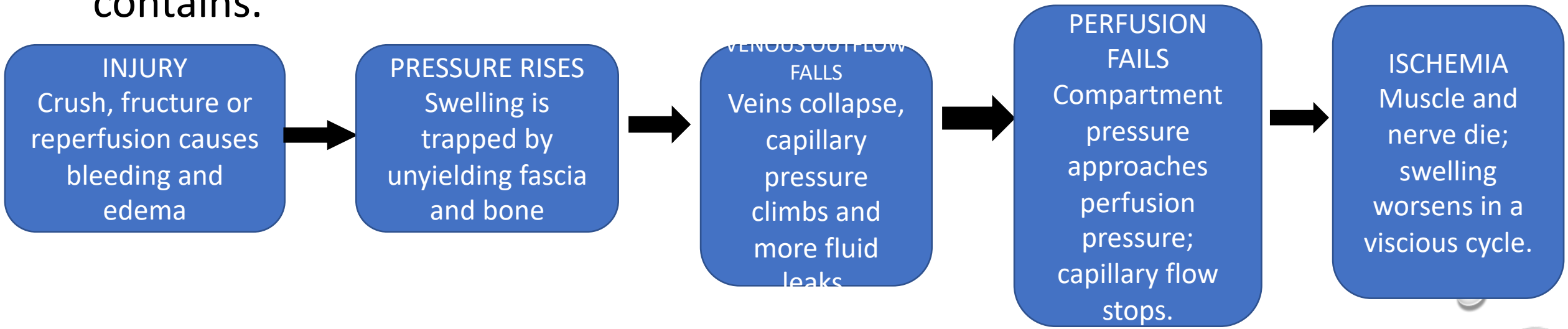

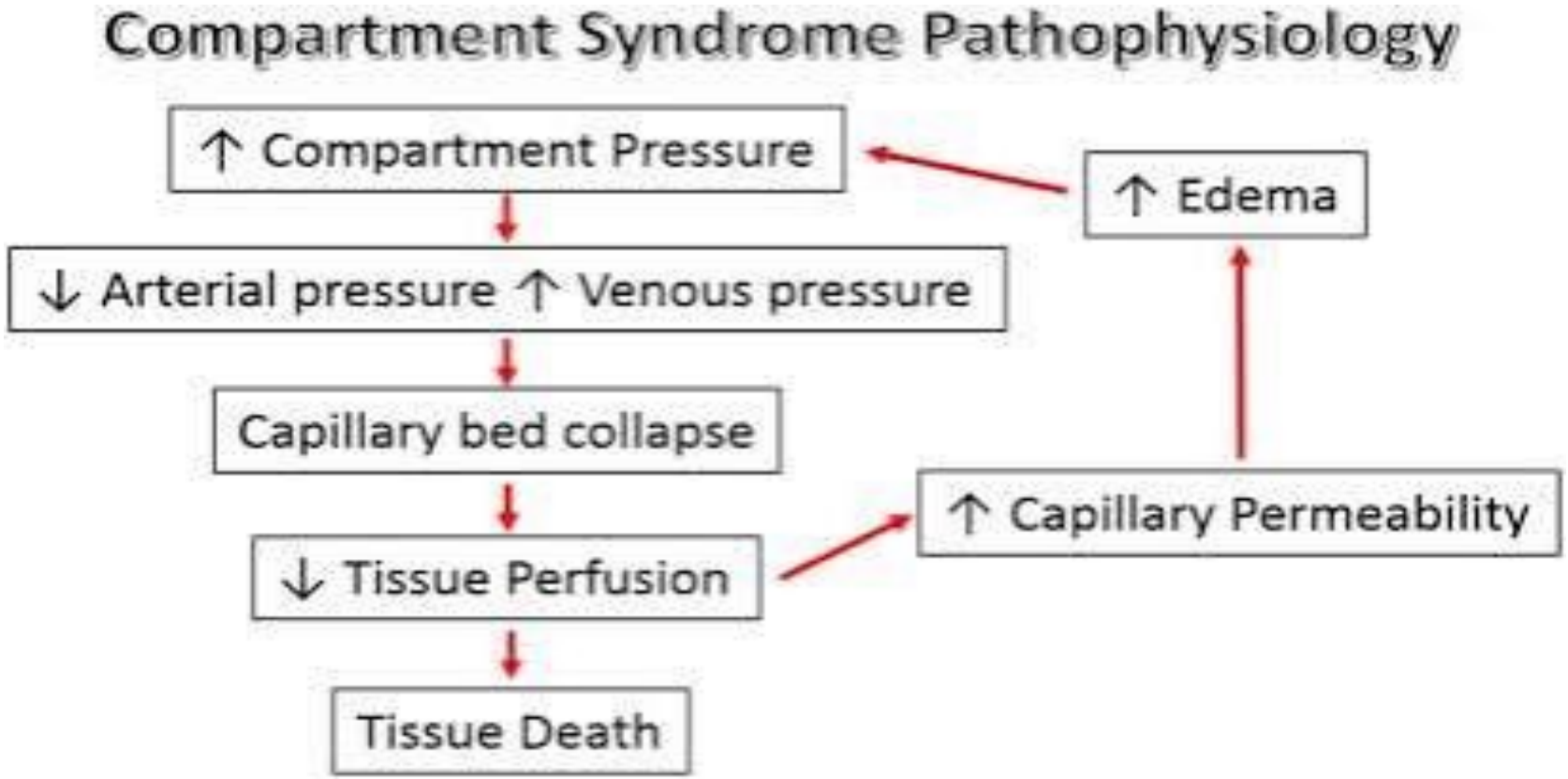
Compartment Syndrome Pathophysiology
↑ Compartment Pressure
↑ Edema
↓ Arterial pressure ↑ Venous pressure
Capillary bed collapse
↑ Capillary Permeability
↓ Tissue Perfusion
Tissue Death

Mechanism of Compartment Syndrome: Pressure Buildup

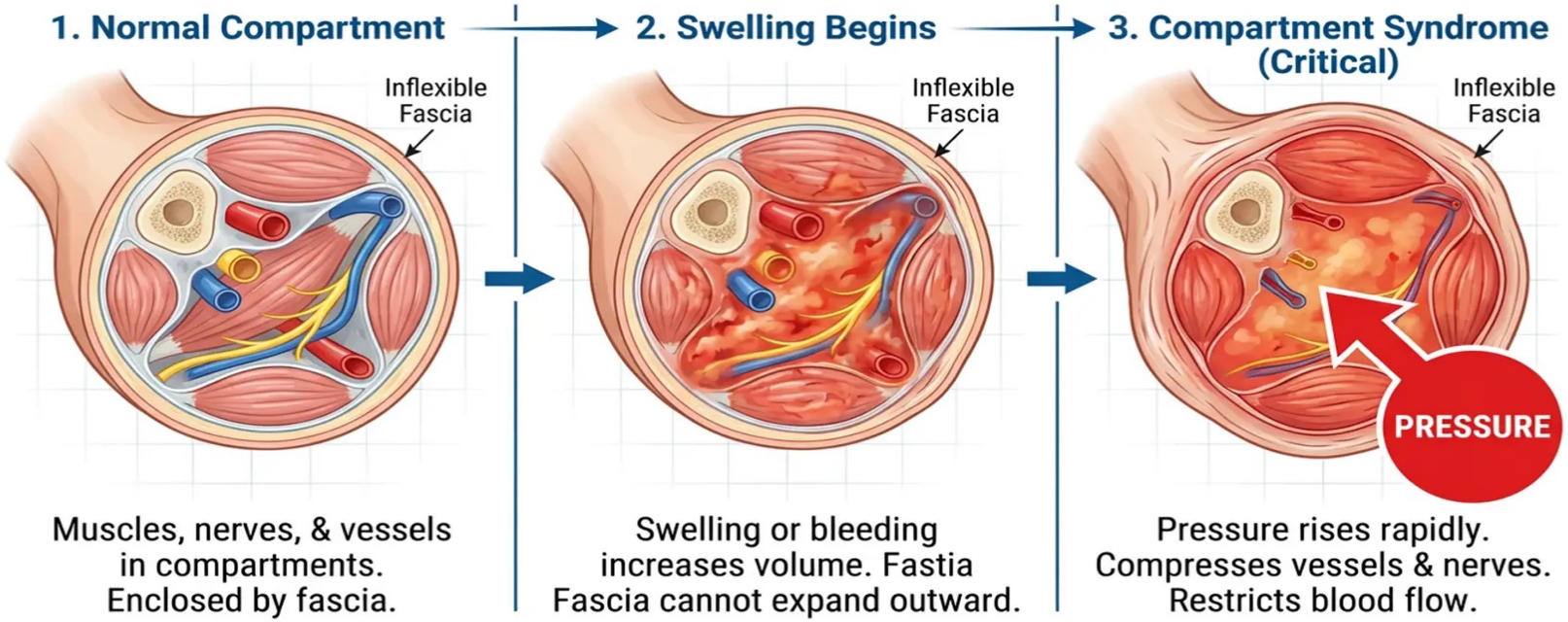

GREATER TEXAS ORTHOPEDIC ASSOCIATES

ISCHEMIC CLOCK

- This is the time from when blood supply stops

30 min to 2hrs

Nerve conduction slows; paresthesia and numbness appear. Still reversible.

About 4hrs

Muscle injury begins and neurapraxia progresses towards axonotmesis

About 6hrs

Irreversible muscle necrosis starts. The traditional deadline for fasciotomy.

8 to 12hrs

Permanent nerve damange and contracture become likely

Neurapraxia : mild type of peripheral nerve injury where nerve is temporarily unable to conduct signals usually because it has been compressed, stretched or midly injured.
Axonotmesis : more severe nerve injury than neurapraxia

Forearm compartments

Superficial volar
Pronator teres, flexor carpi radialis , palmaris longus, flexor digitorum superficialis, flexor carpi ulnaris

Deep volar
Flexor digitorum profundus, flexor pollicis longus. Usually the first and worst affected.

Dorsal (extensor)
Extensor digitorum, extensor digiti minimi, extensor carpi ulnaris, abductor pollicis longus, extensor pollicis longus and brevis, supintor

Mobile wad
Branchioradialis, extensor carpi radiulis longus and brevis.

Mediun and Ulna nerves run through the volar compartments, which is why finger numbness appears early.

CAUSES AND RISK FACTORS

Fractures
Both forearm and distal radius fractures

Crush and high energy trauma
Direct muscle injury, hematoma and prolonged limb compression.

Vascular injury
Arterial injury, ischemia followed by reperfusiin swelling, vascular repair.

External constrictions
Tight casts, splints and dressings; circumferential burns.

DIAGNOSIS

FINDING	MECHANISM	SIGNIFICANCE
Crush injury to the forearm	Muscle damage, bleeding and edema inside closed fascial compartments	Classic precipitating cause
Severe pain	Ischemic muscle and nerve; pain persists despite immobilization [**Ischemic muscle**: Muscle not receiving enough blood and oxygen]	Out of proportion; earliest symptom
Tense swelling	Rising interstitial pressure within the compartment	Firm, tight forearm on palpation
Numbness of the fingers	Median and ulnar nerve ischemia	Early nerve involvement; the limb is at risk

- The radial pulse and capillary refill are probably still normal at this stage. Their presence doesn’t rule out compartment syndrome.

INVESTIGATIONS

0 to 10 mmHg
Normal resting compartment pressure

30 to 40 mmHg
Absolute pressure thresholds quoted by different authors

Below 30mmHg
Delta pressure (diastolic BP minus compartment pressure) supports fasciotomy.

SUPPORTING TESTS

- Creatine kinase, potassium, creatine, urine myoglobin .
- X-ray to look for fracture.
- Doppler or angiography only if arterial injury is suspected.

PITFALLS

- Never delay fasciotomy for tests when signs are clear
- Measure within about 5cm of the injury in every compartments.
- One normal reading does not exclude it; if suspicion persists

Differential diagnosis

CONDITION	DISTINGUISHING FEATURES
Arterial injury	Cool, pale limb with absent pulses; compartments initially soft; confirm with Doppler or angiography
Peripheral nerve injury	Deficit in one nerve territory; no tense swelling; pain not provoked by passive stretch
Crush syndrome	Systemic rhabdomyolysis with hyperkalemia
Fracture or soft-tissue pain	Eases with immobilization and analgesia; compartments remain soft
Infection	Fever, spreading erythema and systemic toxicity (cellulitis, necrotizing fasciitis)

FIRST STEPS IN MANAGEMENT

1. **Release constriction** : Remove casts, splints and circumferential dressings; split padding down to skin.
2. **Position the limb** : Keep it at heart level. Elevation lowers arterial pressure and worsens ischemia.
3. **Support the patient** : Oxygen, IV fluids to protect the kidneys and adequate analgesia. Avoid regional blocks that can mask evolving signs.
4. **Call surgery early** : Urgent orthopaedic, plastic or general surgical review; re-examine regurarly if uncertain.
5. **Decompress** : Proceed to fasciotomy if signs or pressure criteria are met.

Definitive treatment : fasciotomy

Principles

- Decompress every compartment involved.
- Do not wait for pulselessness
- Aim for release within about 6 hours of onset
- Leave the skin open

Volar release (Henry approach)

Curvilinear volar incision from above the elbow to the palm.
Release the lacertus fibrous, superficial and deep volar fascia and the carpal tunnel.

Dorsal release if still tight

Re-check pressure after the volar release. Open the dorsal compartment and mobile wad through a straight dorsal incision if needed.

Wound care

Debride only clearly dead muscle and relook at 24 to 48 hrs.
Use a negative pressure dressing ; close late or skin graft once swelling settles(often 3 to 7 days)

Complications and outcomes

- **Volkmann ischemic contracture (Tsuge classification)**

MILD — Contracture of two or three fingers, usually deep flexors of the index and middle; little or no sensory loss.

MODERATE — Classic type: fingers and wrist flexed, thumb in the palm, with median and ulnar nerve deficit.

SEVERE — Flexors and extensors both involved; profound nerve damage and a useless hand.

Other complications

- Rhabdomyolysis, hyperkalemia and acute kidney injury.
- Permanent nerve palsy and chronic pain
- Infection and wound breakdown
- Fasciotomy scarring and need for grafting.
- Amputation and rarely death.

Late recognition is the main driver of poor outcomes.

Image of vic



KEY TAKEAWAYS

- Crush injury with pain out of proportion, tense swelling and numbness is compartment syndrome until proven otherwise.
- Pain on passive finger stretch is the earliest reliable sign ; pulses stay normal until late.
- Diagnosis is clinical. Use pressure measurement (delta pressure below 3o mmHg) when the exam is unreliable.
- Release constrictive dressings, keep the limb at heart level and proceed to urgent fasciotomy.
- Delay risks Volkmann contracture, rhabdomyolysis ,kidney injury and limb loss

SOURCES

- **Bailey & Loves's Short practice of surgery**

Limb trauma and compartment syndrome

- **Apley& Solomon's System of Orthopaedics and Trauma**

Complications of fractures, Volkmann ischemia

- **Campbell's Operative Orthopaedics**

Compartment and syndromes and fasciotomy techniques

- **Rockwood and Green's Fractures in adults**

Acute compartment syndrome

- **Browner et al.' Skeletal Trauma**

Compartment syndromes

- **Green's Operative Hand Surgery**

Forearm and hand compartment syndrome, Volkmann contracture

- **Schwartz's Principles of Surgery**

Extremity compartment syndrome and rhabdomyolysis

- **Sabiston Textbook of Surgery**

Extremity trauma and vascular injury

- **Rosen's and Tintinalli's Emergency Medicine**

Compartment Syndrome and Crush injury


THANK YOU

TUTORIAL 3 - QN 7

HABIIBAH KATANA SSENKUBUGE
EQ26/MBCHB/AUG 2026

- **Ulnar Nerve Injury at the Medial Epicondyle**
- **Tutorial 3 - Q8**
- **Clinical Case:**
  A 35-year-old construction worker sustains a deep cut just behind the medial epicondyle and develops clawing of the medial two fingers with loss of sensation over the medial hand.

- **Clinical Case**
- 35-year-old construction worker
- Sustains a **deep laceration behind the medial epicondyle**
- Subsequently develops:
  - Clawing of the **4th and 5th fingers**
  - Loss of sensation over the **medial aspect of the hand**
- These findings suggest injury to the **ulnar nerve**
-

- **Anatomy of the Ulnar Nerve**
- The ulnar nerve arises mainly from the **C8–T1 nerve roots**
- It is a terminal branch of the **medial cord of the brachial plexus**
- Travels down the medial side of the arm
- Passes **behind the medial epicondyle**
- Enters the forearm between the heads of **flexor carpi ulnaris**
- Continues into the hand through **Guyon's canal(ulnar tunnel)**

- **Clinical Examination**
- **Motort to abduct and adduct the fingers**
- Test interossei function
- Assess for clawing of the 4th and 5th fingers
- **Sensory**
- Test light touch and pinprick over the ulnar side of the hand
- **Special test**
- **Froment's sign:**
- Patient attempts to hold a piece of paper between thumb and index finger
- Weakness of adductor pollicis causes compensatory flexion of the thumb IP joint
-

- **Level of Injury**
- Because the injury occurs **behind the medial epicondyle**, the lesion is at the **elbow region**.
- Possible consequences include:
- Weakness of forearm muscles supplied by the ulnar nerve distal to the lesion **Interossei.** Medial two **lumbricals**, **Adductor pollicis**

Hypothenar muscles

- **Result:**
- Loss of normal flexion and extension balance at the 4th and 5th fingers produces **ulnar claw hand**.
- Weakness of intrinsic hand muscles
- Sensory loss in the ulnar distribution
- The exact deficits depend on the precise level and extent of the laceration.
-

MANAGEMENT

- Initial management includes:
- Assessment of the wound and neurovascular status
- Careful neurological examination
- Wound exploration when indicated
- Surgical repair may be required for a **complete nerve laceration**
- Rehabilitation and physiotherapy
- Prevention of joint contractures and claw deformity
- Early specialist assessment is important in traumatic nerve injuries.
-

Tutorial 3-Q9:Inability to make ‘ok sign’ due to flexor weakness

AHEBWA YVONNE

EQ26/MBChB/AUG/0038D

The OK sign and Flexor Weakness

- **What is the OK sign?**

The OK sign is made by bringing the thumb and index finger together to form a circle/oval like while other fingers remain extended. It requires active flexion of the thumb(flexor pollicis longus)and the index finger(flexor digitorum profundus). It is a neurological test used to assess the patient's anterior interosseous nerve, a branch of the medial nerve

What is flexor weakness?

Flexor weakness means the muscles that bend the fingers are not properly working. This makes it difficult or impossible to bring the thumb and index finger together

In short: The inability to make an OK sign is a sign of flexor weakness, usually due to a problem with the muscles or the nerve that supplies them

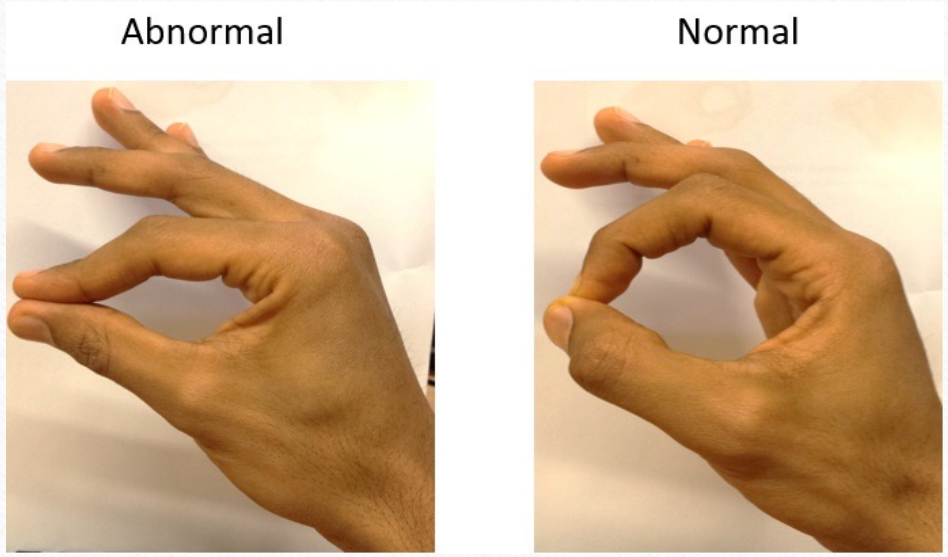

Muscles involved

Flexor pollicis longus(FPL)

- Flexes the thumb(mainly at the interphalangeal joint)
- Supplied by the anterior interosseous nerve

Flexor digitorum profundus (FDP)

- Flexes the index, middle and little fingers (at the distal interphalangeal joints)
- Supplied by the anterior interosseous nerve

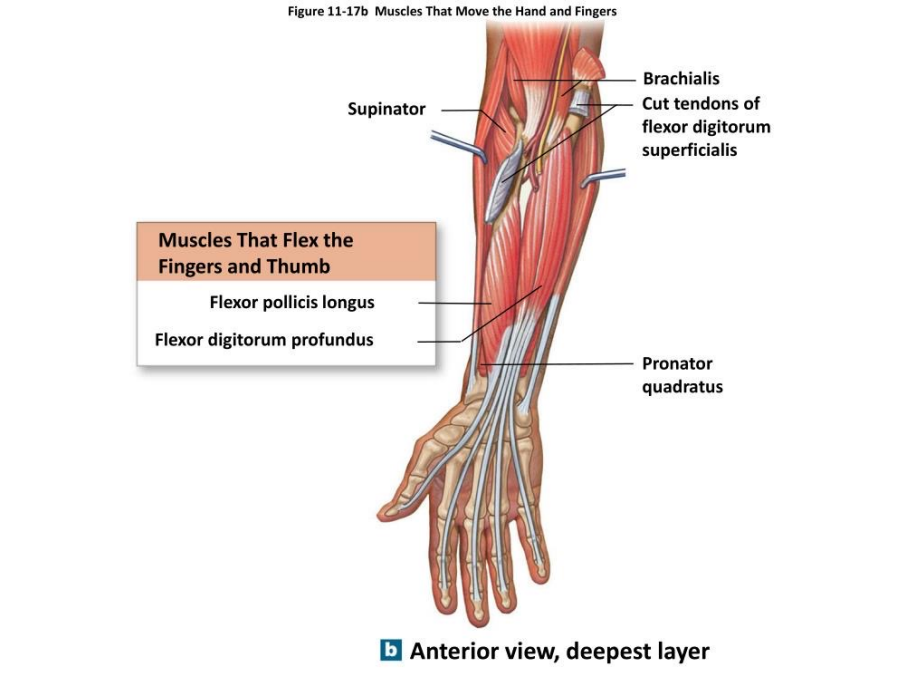

Clinical presentation and examination

Clinical features

- Inability to make the OK sign
- Weak thumb and index flexion
- May have difficulty with fine hand movements (e.g holding a pen, buttoning clothes)
- Other hand movements maybe normal

Examination

- Ask the patient to make the OK sign
- Look for inability to flex the thumb IP joint and the DIP joint
- Test individual muscles if needed

FPL-flex the thumb IP joint

FDP-flex the index finger DIP joint

- Findings: -thumb IP joint cannot flex
  -Index finger DIP joint cannot flex
  -other fingers maybe normal

Causes and treatment

causes

- Anterior interosseous nerve palsy; the most classic cause. It affects the FPL and the index finger FDP
- Median nerve injury i.e. an injury higher up can involve the AIN and cause additional median nerve deficits
- Trauma i.e. fractures, penetrating injuries
- Nerve compression/ irritation; the AIN occasionally become compressed

treatment

- Medical assessment- to determine whether its AIN palsy or another nerve or muscle problem
- Treat the underlying cause e.g treatment of an injury or other condition affecting the nerve
- Physiotherapy

TUTORIAL 3 • QUESTION 10

ANATOMICAL LANDMARKS IN BLOOD SAMPLING

- Cubital fossa and wrist
- Important structures for safe venous and arterial blood sampling
- Year 1 Medicine & Surgery

Allens test carried before radial aterial blood supply

1 | CUBITAL FOSSA

Key structures

- Median cubital vein — common site for venous blood collection
- Biceps brachii tendon
- Brachial artery
- Median nerve
- Lateral → medial: Tendon → Artery → Nerve (TAN)

2 | WRIST & CLINICAL IMPORTANCE

Key landmarks

- Radial artery — important for arterial blood sampling
- Located superficially near the distal radius
- Close to the flexor carpi radialis tendon
- Other structures: ulnar artery, median nerve, ulnar nerve and flexor tendons
- Knowing the anatomy helps prevent injury and ensures safe, accurate sampling.

LUTWAMA IAN PAUL
EQ26/MBChB/AUG/0048D
Tutorial 4 - QN1

SMITH FRACTURE.

TUTORIAL 4 - QN 2

NANNOZI VIVIAN CAROLLINE
EQ26/AUG/MCBhB/0035D

This is a fracture caused when a person falls on a flexed arm breaking the proximal end or lower part of the radius where the broken piece tilts forward toward the palm.

BACKGROUND

* VOLAR (FORWARD) DISPLACEMENT FRACTURE of DISTAL END of RADIUS
  ~ aka REVERSE COLLES' FRACTURE
* USUALLY CAUSED by "FALL ONTO FLEXED WRIST"



TYPES of FRACTURES



TYPE I
TRANSVERSE BREAK OUTSIDE WRIST



TYPE II
INTRA-ARTICULAR FRACTURE

TYPE III
JUXTA-ARTICULAR OBLIQUE FRACTURE

TREATMENT

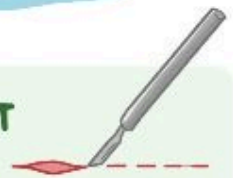

* CLOSED REDUCTION
* OPEN REDUCTION INTERNAL FIXATION (ORIF)
* FOLLOWED by CAST/SPLINT in EXTENDED POSITION & PHYSICAL THERAPY



OSMOSIS from Elsevier

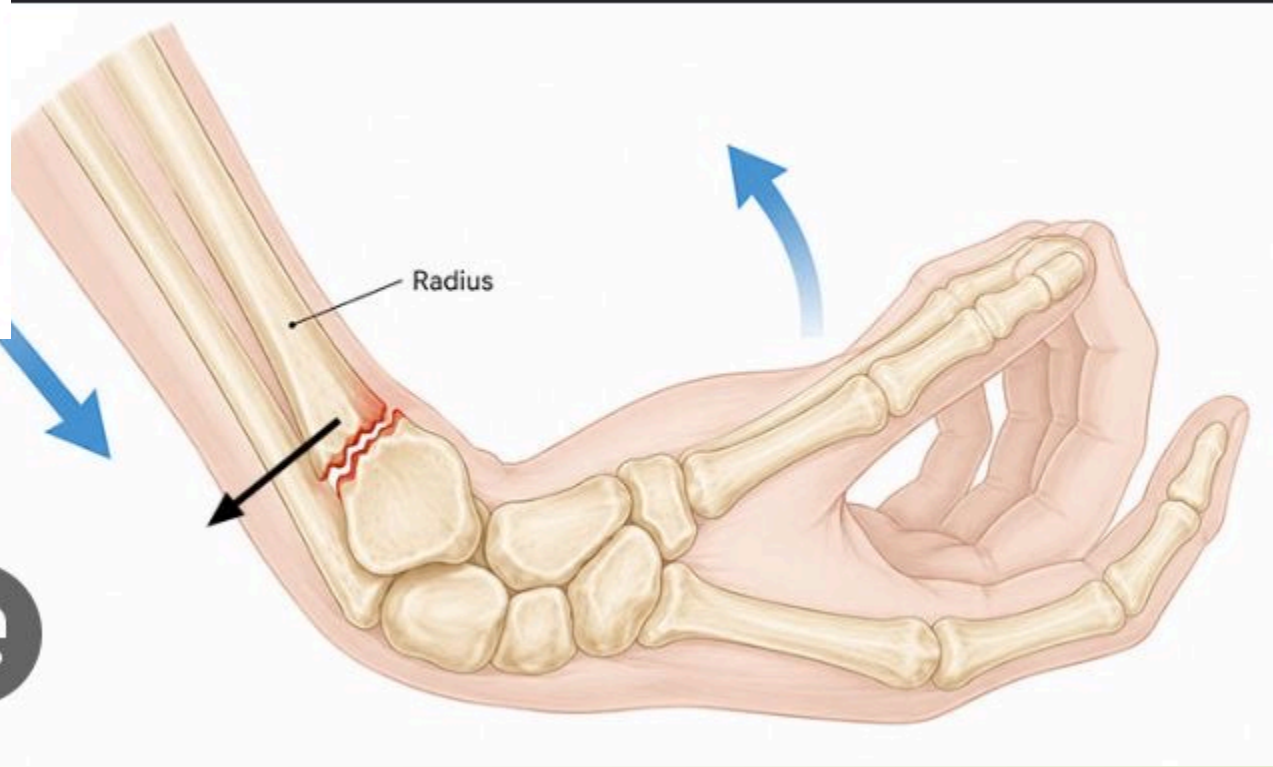

The complications and diagnosis of the smith fracture of the radius.

Complications.

- Carpal tunnel syndrome i.e. pressure on the nerve in then wrist.
- Mal union or healing in an improper position.
- Joint stiffness or long term pain.
- Swelling.
- Bruising
- Tenderness
- Bent shape of wrist or garden spade shape of wrist.

Diagnosis.

- Simple or stable breaks are treated with a closed reduction (realigning the bone by hand)followed by cast for about 6 weeks .
- Surgical; unstable or complex breaks require surgery such as an open reduction and internal fixation.

TUTORIAL 4;CASE 3 TENDERNESS BUT NORMAL X-RAY DIAGNOSIS

BY LATIFAH

EQ26/BDS/AUG/OO24D

CASE 3:A 25 year old man falls on an outstretched hand. He has snuffbox tenderness but normal x-ray .Diagnosis

- Anatomical snuffbox tenderness is a classic clinical sign of a scaphoid fracture.In fracture of scaphoid ,x-ray examination often does not reveal fracture immediately after injury because displacement of fractured fragments does not occur.

- The radial artery supplies blood to the scaphoid bone which enters through the distal part of the bone to supply the proximal part , the fracture occurs at the narrow part of the bone called the waist, this interrupts the arterial blood supply to the proximal part of the bone resulting into avascular necrosis.

NB :The anatomical snuffbox is formed by the tendons of the extensor pollicis brevis accompanying the abductor policies longus and the extensor policies longus . The floor of the snuffbox is formed by the scaphoid bone ,and it is here that one can palpate for a possible fractured scaphoid.(the patient feels pain when you press the snuffbox with your finger)

DIAGRAM SHOWING FRACTURE OF A SCAPHOID BONE

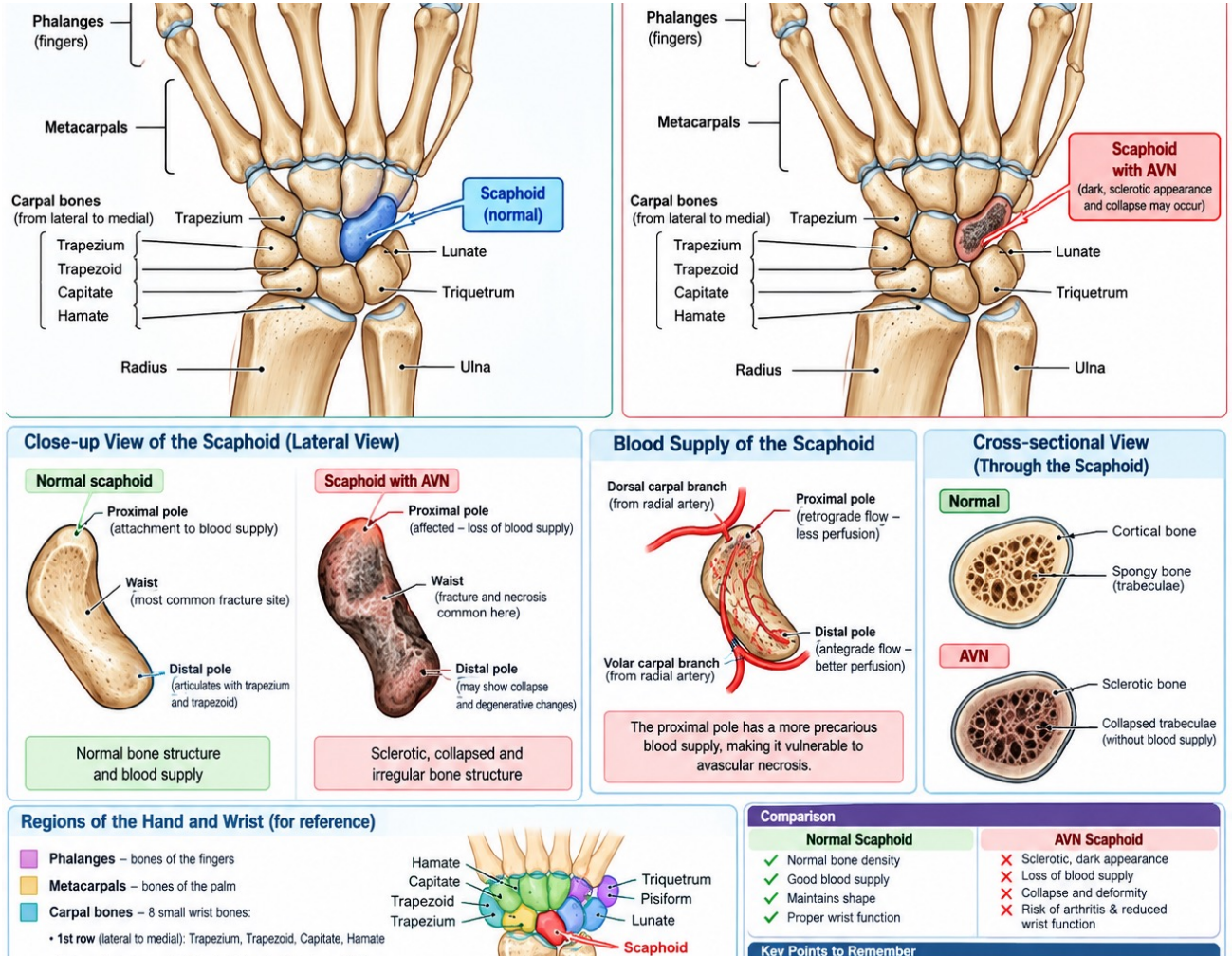

Nakiduuli Emily
EQ26/MBchB/AUG/0073DTUTORIAL 4 QN 4

Tutorial 4 - Q5: Nabateregga Desire Winslet EQ26/BDS/AUG/0025D

TUTORIAL 4 NUMBER 5 HYPOTHENAR MUSCLES

BY:

NABATEREGGA DESIRE WINSLET

EQ26/BDS/AUG/0025D

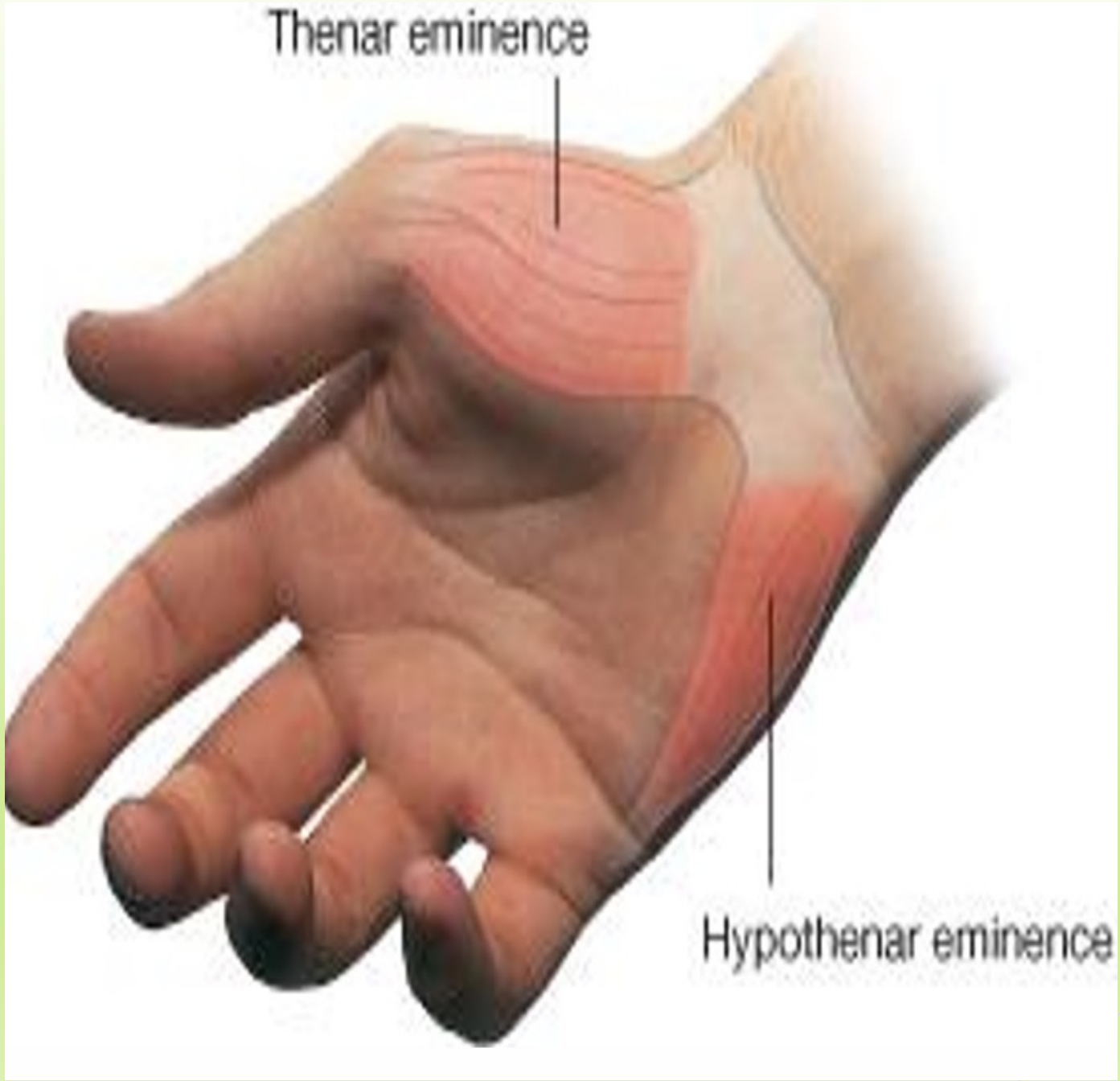
Thenar eminence
Hypothenar eminence

A 45-year-old cyclist presents with weakness of the hypothenar muscles and sensory loss in the medial hand. Diagnosis?

- The hypothenar muscles are innervated y the ulnar nerve and these include abductor digit minimi, flexor digit minimi brevis and opponens digit minimi.
- Responsible for fine motor control, gripping objects, and cupping the hand
- Diagnosis**: Guyon's canal syndrome[ULNAR NERVE COMPRESSION]** (also widely known as **cyclist's palsy** or **handlebar palsy**), which is an entrapment of the **ulnar nerve** at the wrist.
- In cyclists, prolonged pressure and road vibrations against the handlebars compress the ulnar nerve as it passes through **Guyon's canal** (the fibro-osseous tunnel between the pisiform and the hook of the hamate). Because this patient presents with both **motor weakness** (hypothenar muscles) and **sensory loss** (medial/ulnar aspect of the hand), the compression is localized **proximal to the bifurcation** of the ulnar nerve within Zone 1 of the canal, where the nerve is still a mixed sensory and motor trunk



QN6; -THE MALLET FINGER (The baseball finger)

BY; MUKEMBO JAVAN

EQ26/AUG/BDS/0023

CAUSE OF INJURY

Injury happens at the Distal Interphalangeal joint

When an object like a basket ball hits the tip of the straight finger that forces the tip to bend violently.

Hence the extensor tendon is torn away from the distal phalanx which is called an avulsion

The person loses the ability to expend the distal phalanx leaving it permanently bent

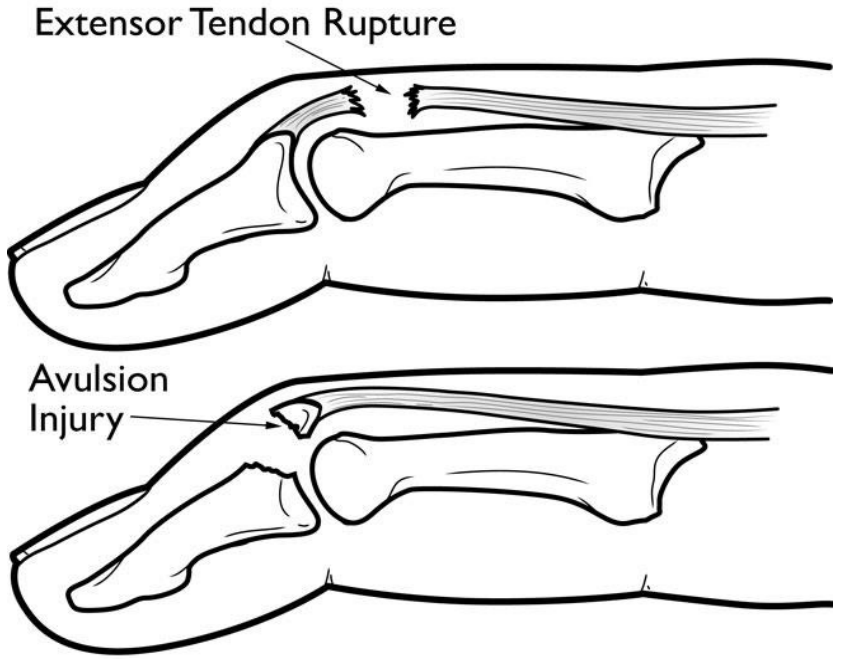

ILLUSTRATION

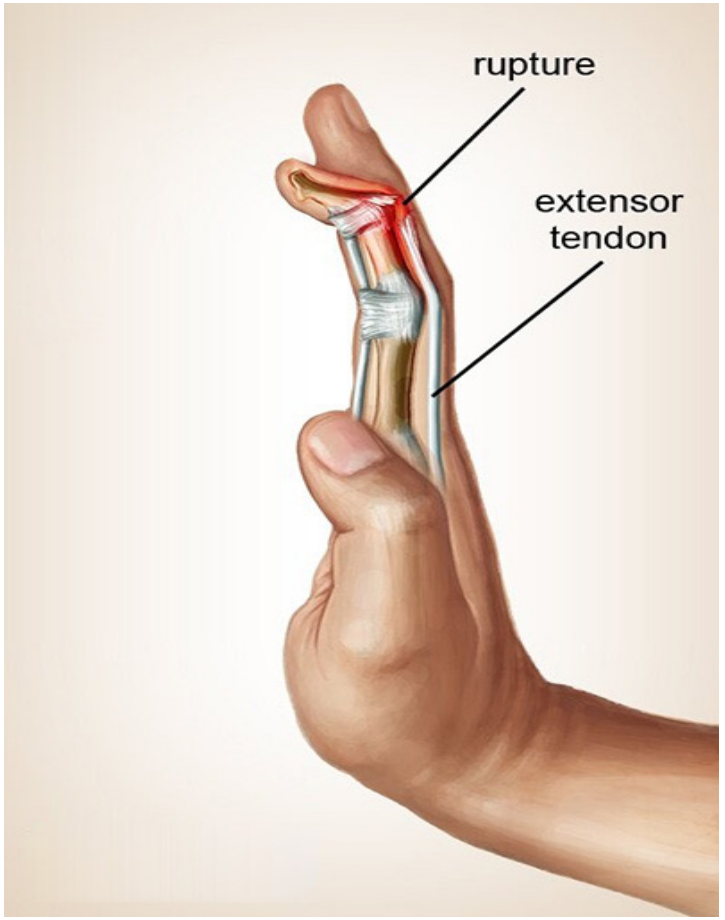

THANK YOU

Tutorial 4. No.7
Chronic wrist pain with radio carpal osteopytes

UWIMAANA PRECIOUS REBECCA

EQ26/BDS/AUG/0003D

Radio carpal joint

- This joint is located at the wrist, where the distal end of the radius articulates with the proximal row of carpal bones.

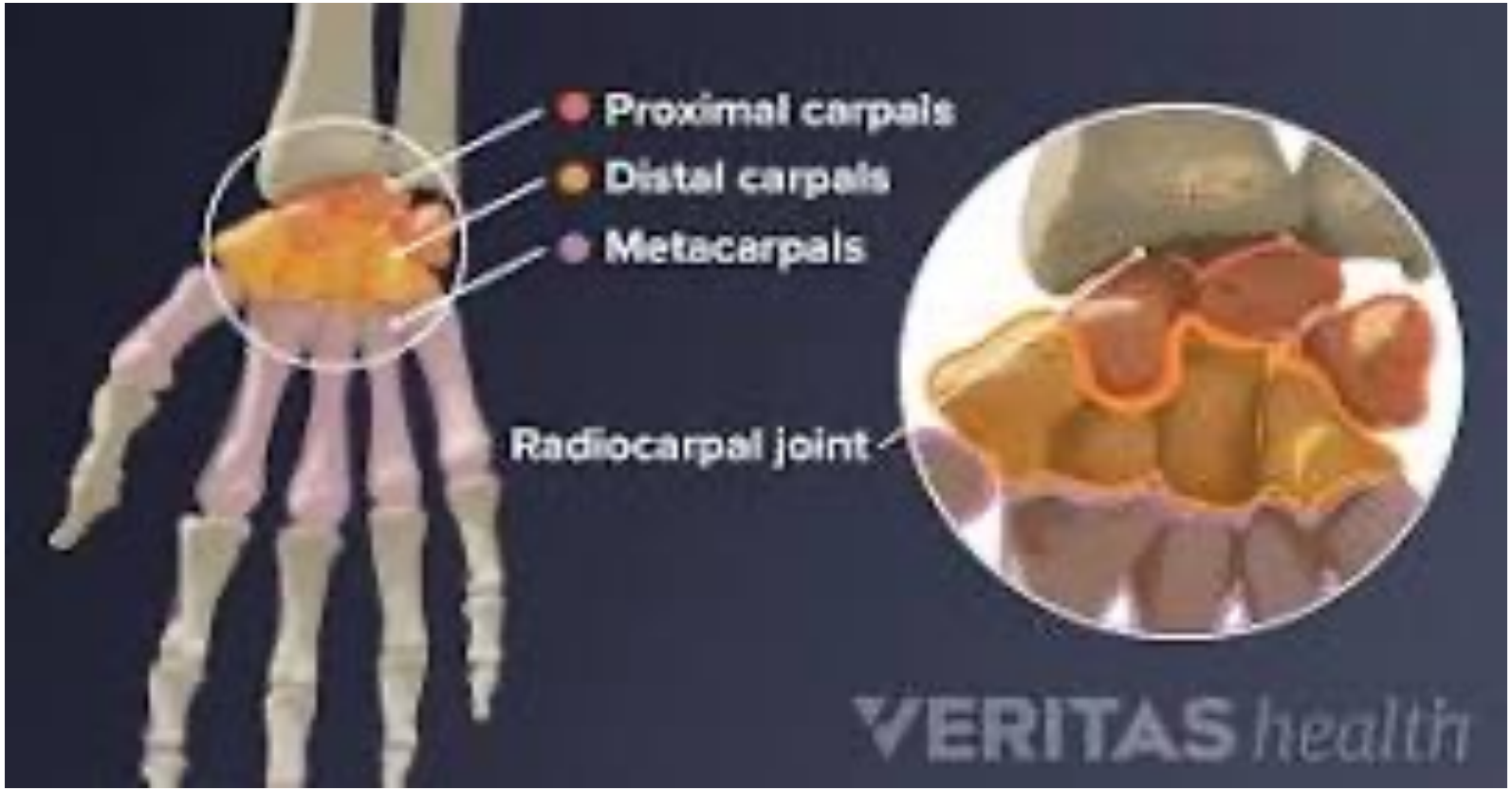

Osteophytes

- An osteophyte is a marginal bony outgrowth that develops at the edge of a joint, commonly as a result of a degenerative joint disease such as **osteoarthritis**.
- It is an abnormal bony projection or bone spur that develops along the edge of a joint.

Radio carpal osteophytes.

- These osteophytes develop around the margins of the radio carpal joint of the wrist

Causes ;

1. Detoriating and damage of the cartilage. It becomes thin.
2. Increased mechanical stress of the joint.
3. Bone modelling.(Formation of the new bone)

Later an osteophyte is formed.

Symptoms

- Chronic wrist pain.
- Stiffness
- Swelling and tenderness
- Clicking sensation.(hearing a snap or pop when the joint is moved)
- Reduced grip strength. (Loss of ability to squeeze, or hold an object)
- Restricted range of motion

Why is it chronically painful?

- When the patient grips an object, forces are transmitted through the hand and carpal bones to the radius.
- These forces can produce increased stress across the abnormal joint surfaces

Clinical Examination

- Swelling
- Deformity
- Muscle wasting
- Warmth
- Bony enlargement
- Restricted range of motion

FLEXION CONTRACTURES OF 4TH & 5TH FINGER "DUPUYTREN'S CONTRACTURE"

PRESENTED BY AMOIT PATRICIA "EQ26/MBCHB/AUG/0032D"

TUTORIAL 4 QN 9

DEFINATION: Dupuytren's contracture is abnormal thickening of the **palmer fascia**.

* It is an inherited disease.

- **Palmer fascia** is a thin sheet of fibrous tissue. It builds the ball shape of the palm.



Symptoms of Dupuytren's Contracture

- Dupytren's nodule
- Dupuytren's pit
- Dupuytren's band ; most common and it is characterized by a tight tendon.







TREATMENTS OF FLEXION CONTRACTURES OF 4TH AND 5TH FINGER

- EARLY STAGE; That is when the dupuytren's band appears but the fingers are still straight.
- **Treatment** ; keep the skin healthy by "using hand creams" & make some stretches of the fingers.





- LATE STAGE; When the fingers start to bend to a degree "20" and when there's failure of hand function. When you can not put your finger in the pocket.



CONTINUATION OF TREATMENT.

- **TREATMENT OF LATE STAGE**
- (1) **Needle fasciotomy** ; A Surgeon uses a needle to carefully release the thickened dupuytren's band beneath the skin allowing the affected fingers & joints to straighten.

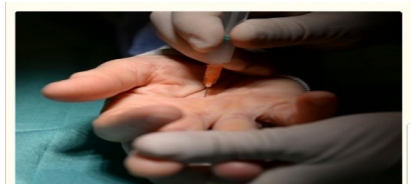

(2) **Collagenase injection**; A special chemical injected in the tight dupuytren's band to break it down. "24 – 48 hours "

After two days , the doctor stretches the affected finger.

CONTINUATION OF TREATMENT

- **PALMER FASCIECTOMY**; The surgeon cut through the dupuytren's band. It leaves a scar and a spleen is put for a few months so as to g[illegible]sults.



- **DERMO FASCIECTOMY**; A normal operation where the surgeon cuts a small skin graft from the hairless region of the forearm & place it over the palm. It slows down the dupuytren's contraction. It leaves the patient with a different skin on [illegible]n.



QN.11 RHEUMATOID ARTHRITIS of the hand

Rheumatoid arthritis is a chronic, systemic inflammatory disease that primarily targets the synovial joints, with a notable predilection for the small joints of the hands and wrists. The disease most commonly affects the metacarpophalangeal (MCP) and proximal interphalangeal (PIP) joints, which is consistent with the patient's presentation. The inflammatory process begins in the synovial membrane, leading to synovial hyperplasia and the formation of an invasive tissue called pannus, which ultimately causes destruction of articular cartilage and bone.

QN: A 50 –year- old woman presents with swollen MCP and PIP joints , ulna deviation and morning sickness. X ray shows joint erosions and deformities. diagnosis

Rheumatoid arthritis is a combination of;

- MCP involvement
- PIP involvement
- Swelling
- Prolonged morning sickness
- Ulna deviation

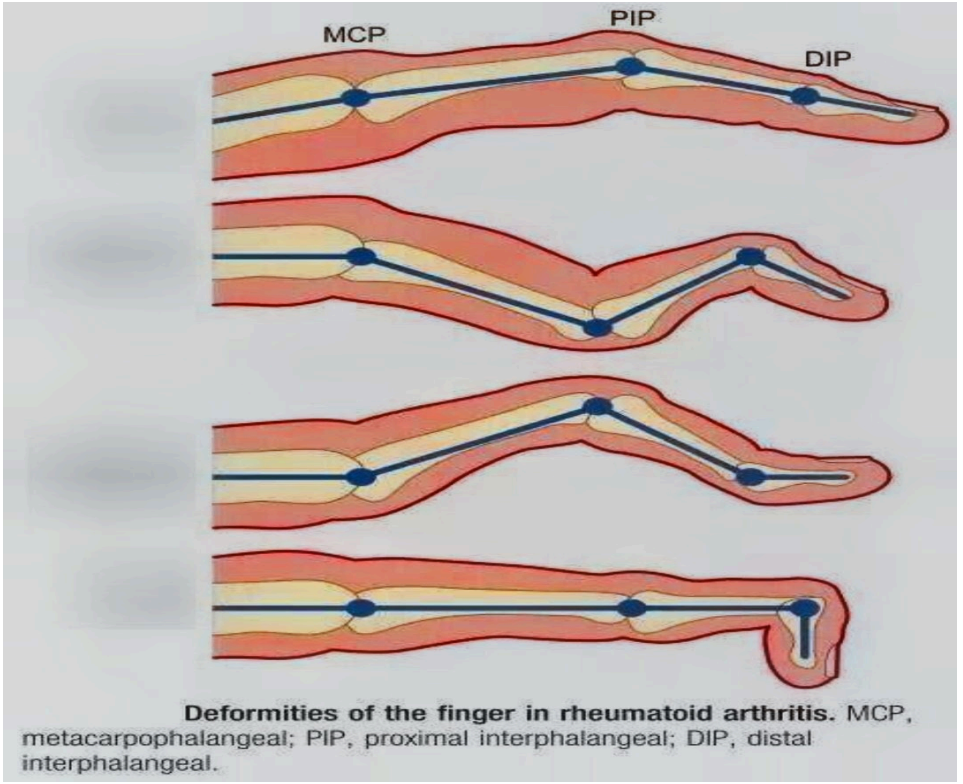

Deformities of the finger in rheumatoid arthritis. MCP, metacarpophalangeal; PIP, proximal interphalangeal; DIP, distal interphalangeal.

It primarily targets the synovial joints

Chronic synovitis can damage the;

Cartilage, subchondral bone, joint capsule, collateral ligaments, tendons, tendon sheaths.

This alters the balance of forces around the hand.

Why does ulna deviation occur?

At the MCP joints, chronic synovial inflammation and ligament/ tendon imbalance causes;

Extensor tendon displacement toward the ulna the ulna side

This leads to progressive ulna drift of the fingers

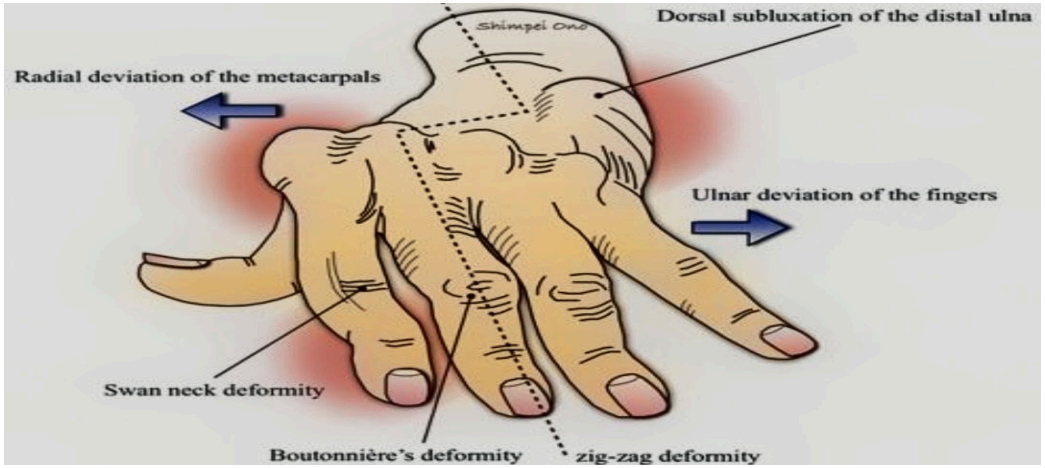

Important Rheumatoid deformities

1. Ulna deviation

   MCP joints drift towards the ulna.
2. Swan-neck deformity

   PIP hyperextension + DIP flexion
3. Boutonniere deformity

   PIP flexion + DIP hyperextension

These result from disruption of the extensor mechanism and altered tendon/ligament forces

Why rheumatoid arthritis?

The combination of:

- MCP involvement

PIP involvement

- swelling

prolonged morning stiffness

- ulnar deviation
- erosions

is characteristic of inflammatory rheumatoid disease.

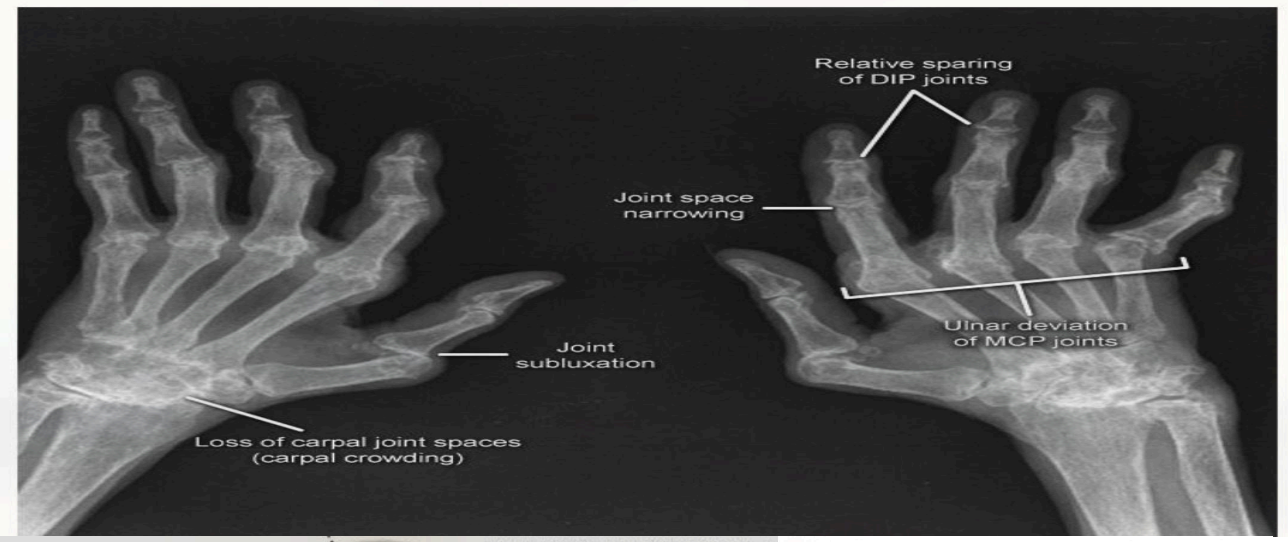

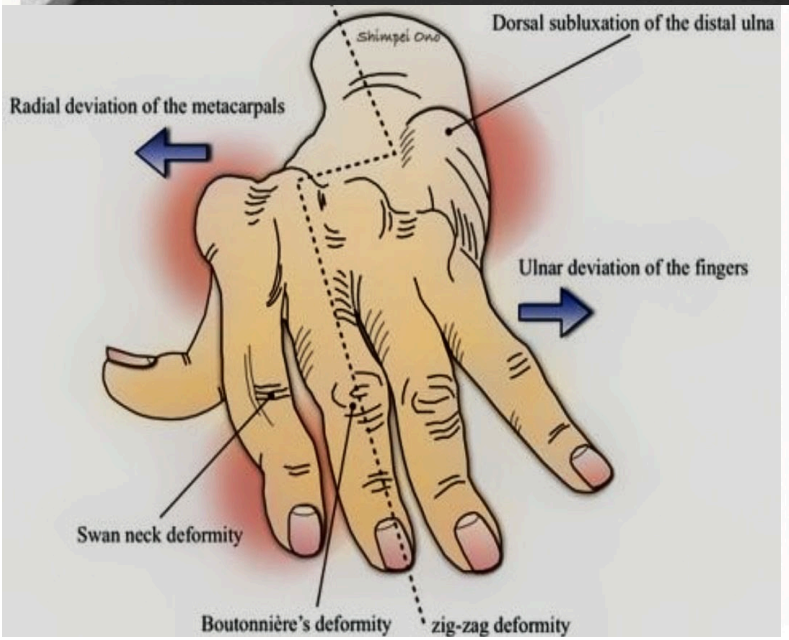

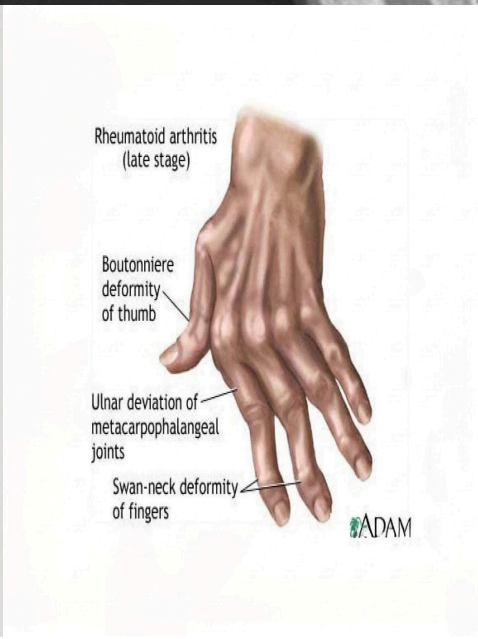

WHY DOES ULNAR DEVIATION OCCUR & MORNING SICKNESS

- Ulnar deviation is a characteristic deformity in RA, resulting from a complex interplay of forces acting on a joint destabilized by synovitis. Proliferative synovitis attenuates the MCP joint capsule and ligamentous structures, leading to loss of stability. The extensor tendons displace ulnaward from their normal position, and combined with the pull of flexor tendons and intrinsic muscles, this results in the classic ulnar drift. Concomitant wrist pathology, such as radial deviation of the wrist, can further contribute to ulnar deviation of the fingers, creating a "zig-zag" deformity
- Morning stiffness lasting for more than an hour is a hallmark symptom, reflecting the inflammatory nature of the disease.